



Reversal of dexamethasone depressed healing by *ficus racemosa* roots I

Krishna Murti¹ and Upendra Kumar²

¹Singhania University, Jhunjhunu, Rajasthan, India.

²Department of Pharmacy Chemistry, College of Pharmacy, Azamgarh, Uttar Pradesh, India.

ARTICLE INFO

Article history:

Received: 21 September 2011;

Received in revised form:

19 January 2012;

Accepted: 30 January 2012;

Keywords

Ficus racemosa,
Wound healing, dexamethasone,
Incision,
Excision wound model.

ABSTRACT

This study was conducted to evaluate aqueous & ethanolic extracts of *Ficus racemosa* for wound healing properties in presence of dexamethasone depressed healing conditions. Reversal mechanism of dexamethasone depressed wound healing properties by *Ficus racemosa* was determined using the incision and excision wound model. Both the extract reverted the dexamethasone depressed healing effectively when compared with dexamethasone treated group. The results were comparatively significant ($p < 0.05$).

© 2012 Elixir All rights reserved.

Introduction

Ficus racemosa Linn (Moraceae) is an evergreen, moderate to large sized spreading, lactiferous, deciduous tree, without much prominent aerial roots found throughout greater part of India in moist localities and is often cultivated in villages for its edible fruit [1]. The astringent nature of the bark has been employed as a mouth wash in spongy gum and also internally in dysentery, menorrhagia and haemoptysis. All parts of this plant (leaves, fruits, bark, latex, and sap of the root) are medicinally important in the traditional system of medicine in India. The leaves powdered and mixed with honey is given in bilious infections. The bark is antiseptic, antipyretic and vermifugal, and the decoction of bark is used in the treatment of various skin diseases, ulcers and diabetes. It is also used as a poultice in inflammatory swellings/boils and regarded to be effective in the treatment of piles, dysentery, asthma, gonorrhoea, gleet, leucorrhoea and urinary diseases [2]. Very little phytochemical work has been carried out on *Ficus racemosa*. Stem: campesterol, hentriacontane, hentriacontanol, kaempferol, stigmasterol, methyl ellagic acid. Leaves: Tetra triterpene, glaucanol acetate, racemoseic acid. Fruit: glaucanol, hentriacontane, β sitosterol, glaucanolacetate, glucose, tiglic acid, esters of taraxasterol, lupeolacetate, friedelin, higher hydrocarbons and other phytosterol. Root: cycloartenol, euphorbol and its hexacosanoate, taraxerone, tinyatoxin; Bark: euphorbol and its hexacosanoate, ingenol and its triacetate, taraxerone [3].

In view of this, so much recent attention has been paid to extracts of biologically active compounds isolated from plant species used in herbal medicine [4]. Wound healing is a complex multifactorial process that results in the contraction and closure of the wound and restoration of a functional barrier [5]. Repair of injured tissues occurs as a sequence of events, which includes inflammation, proliferation and migration of different cell types [6].

Glucocorticoids are known to suppress wound healing. Dexamethasone is a very potent antiinflammatory glucocorticoid used in organ transplantation and skin allografts.

Dexamethasone strongly interferes with both the synthesis and degradation of collagen [7]. There are not many agents which are able to successfully overcome the anti-healing effect of corticosteroids. Therefore, the present study was aimed to establish the reversal of antihealing effect of dexamethasone with antimicrobial properties.

Materials

Roots of *Ficus racemosa* L. growing in natural habitat in Modasa, Gujarat, India, was collected in October, 2010 and identified by Associate Professor Dr. M. S. Jangid, Department of Botany, Modasa, Hemchandra Gujarat University by carrying out macroscopic and microscopic evaluation and has been submitted in the institute for future reference purpose.

Preparation of the root extract

Dried and coarsely 500 g powdered roots of *Ficus racemosa* was extracted with 90% (v/v) ethanol in soxhlet apparatus for 36 hrs and aqueous extract was prepared by using maceration technique of extraction. Filter the filtrate. The filtrate was concentrated on water bath using petridish. The temperature was maintained at 55 °C. The semi-solid extract was dried and weighed.

The preliminary phytochemical analysis

The preliminary phytochemical studies were performed for testing different chemical groups present in ethanolic & aqueous extract [8-9].

Acute toxicity study

Acute toxicity study was done in rats weighing between 150-200 g. Rats were fasted overnight. They were divided into 5 groups of two animals each. The ethanolic extract of *Ficus racemosa* was administered orally through the feeding tube to the pair of rats of each group in ascending and widely spaced doses viz. 10, 30, 100, 300, 1000 mg/kg. The animals were observed continuously for 2 hours and then occasionally for further 4 hours and finally overnight mortality was recorded. No signs of toxicity were observed even with 1000 mg/kg of *Ficus racemosa*. So the dose of the extract chosen for the study was

100 mg/kg which is corresponding to the 1/10th of the maximum tolerated dose (1000 mg/kg) [10].

Drugs and their administration

Ketamine injection was obtained from Neon Laboratories Limited (Mumbai, India); Dexamethasone was obtained from Zydus Alidac (Ahmedabad, India). For oral administration, a suspension of aqueous and ethanol extract (8%) was prepared using 2% gum acacia. The drugs were administered once a day from day 1 and continued till the completion of the models.

Wound healing models

Animals and grouping

Wistar albino rats of either sex weighing between 180 and 200 g were obtained from Jai Foundation Research, Vapi (Gujarat). The study was approved by the Institutional Ethics Committee for animal experimentation, Vidyabharti Trust College of Pharmacy, Umrakh, Gujarat (VBT/IAEC/11/05/46) and all the procedures on animals were carried out as per CPCSEA guidelines, India. These animals were used for the wound healing activity studies. The animals were stabilized for 1 week. They were maintained in standard conditions at room temperature, 60±5% relative humidity and 12 h light dark cycle. They had been given standard pellet diet and water *ad libitum* throughout the course of the study. The ethanolic & aqueous extract of *Ficus racemosa* was administered orally to all groups of animals.

Group 1 Control group treated with simple saline orally (*p.o*)

Group 2 Dexamethasone treated group intraperitoneally (*i.p*)

Group 3 Aqueous extract of *Ficus racemosa* L. + Dexamethasone (*p.o + i.p*)

Group 4 Ethanolic extract of *Ficus racemosa* L. + Dexamethasone (*p.o + i.p*)

Incision wound model

The rats were anesthetized by administering ketamine (0.5 ml/kg b. w. i.p.). Incision wounds of about 6 cm in length and 2mm in depth were made with sterile scalpel on the shaved back of the rats 30 min later the administration of ketamine injection. The parted skin was kept together and stitched with black silk at 0.5cm intervals. Surgical thread (no. 000) and a curved needle (no. 9) were used for stitching. The continuous thread on both wound edges were tightened for good closure of the wounds. The wounds of animals in the different groups were treated with drug by oral administration as described above, for the period of 10 days. The wounding day was considered as day 0. When wounds were cured thoroughly, the sutures were removed on the 8th post-wounding day and the breaking strength of the skin that is the weight in grams required to break open the wound/skin was measured by tensiometer on the 10th day reported [11-12].

Excision wound model

A standard wound of uniform 2 cm diameter was formed with the aid of a round seal [13]. The percentage wound closure, epithelization time and scar area on complete epithelization was measured.

Statistical analysis:

Results were analysed by one way analysis of variance (ANOVA) using post hoc dunnet's test and p-value < 0.05 was considered significant.

Results

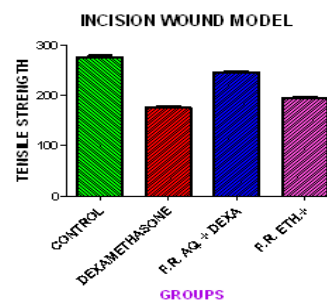
Phytochemical Analysis

On preliminary phytochemical screening the extract showed that the roots of *Ficus racemosa* L. contain saponins, tannins, alkaloids and flavanoids while other constituents like amino acids, carbohydrate was absent (Table 1).

Incision wound model:

A significant decrease in wound breaking strength in dexamethasone alone treated group was observed as compared to control group. Suppression of wound breaking strength by dexamethasone was effectively reversed (p-value < 0.05) when treated along with aqueous & ethanolic extract of *Ficus racemosa* 100mg/kg extract as shown in table 1. (Table 2, Fig.1)

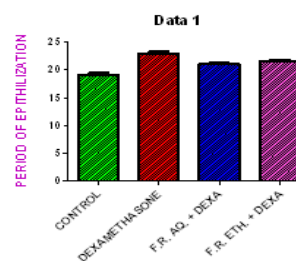
Fig. 1 Incision wound model



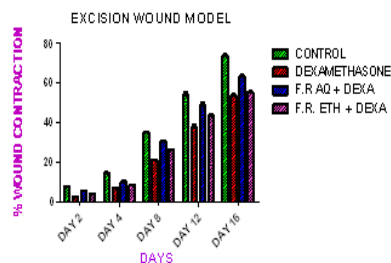
Excision wound model

In excision wound model reversal effect was observed with the extract treated animals which showed significant decrease (p-value < 0.05) in epithelization period and significant increase in percentage wound contraction as compared to dexamethasone alone (table 3). In dexamethasone alone treated group significant increase (p-value < 0.05) in epithelization period and decrease in percentage wound contraction were observed when compared to control. (Table 3, Fig. 2.1 & 2.2)

Excision wound Model (Period of epithelization in days)



Excision wound Model (Percentage wound contraction in days)



Discussions:

The complex process of healing involves various phenomena like wound contraction, granuloma formation, collagen maturation etc. The contribution for healing of such processes depends on the type of wound. Wound contraction plays a significant role in healing of excision wound while granuloma formation plays a role in healing of sutured incision. The results of the present study clearly demonstrate that the aqueous & ethanolic extract of *Ficus racemosa* possess a definite reversal action in the steroid depressed wound healing. An increase in wound tensile strength of treated wounds may be due to increase in collagen concentration and stabilization of collagen fibres. Recent studies with other plant extracts have shown that phytochemical constituents like flavanoids [15],

alkaloids [16], saponins [17] and tannins [18] are known to promote the wound-healing process. The study reveals that both aqueous & ethanolic extracts treated groups possess good wound healing properties which may be attributed to the individual or combined action of phytoconstituents like, flavanoids, alkaloids, saponins and tannins present in it. However, from the study it was evident that aqueous extract was having more potential to antagonize the dexamethasone suppressant action. Ethanolic extract was also effective comparable to that of control group.

References

- Krishna Murti^{1*}, Upendra Kumar², Vijay Lambole et. al. Pharmacological properties of *Ficus racemosa* –A Review. *Pharmacologyonline* 2: 802-807 (2010)
- Nadkarni KM, Nadkarni AK, Chopra RN. *Indian Materia Medica*, Popular Prakashan, Bombay, 1976, 1, 548-550.
- Padmaa MP, Phytochemicals in *Ficus recemosa*, *_at Pro Rad.*, Vol. 8(1), 2009; pp.84-90.
- Essawi, T., Srour, M., Screening of some Palestinian medicinal plants for antibacterial activity. *Journal of Ethnopharmacology*. 2000. 70, 343.
- Chattopadhyay, D., Arunachalam, G., Mandal, A.B., Sur, T.K., Mandal, S.C., Bhattacharya, S.K. Antimicrobial and anti-inflammatory activity of folklore: *Mellotus peltatus* leaf extract. *Journal of Ethnopharmacology*. 2002 82, 229– 237.
- Sidhu, G.S., Mani, H., Gaddipatti, J.P., Singh, A.K., Seth, P., Banaudha, K.K., Patnaik, G.K., Maheshwari, R.K., Curcumin enhances wound healing in streptozotocin-induced diabetic rats and genetically diabetic mice. *Wound Repair and Regeneration*, 1999. 7, 362– 374.
- Shalini Adiga*, Prakash Tomar, Rajput. R.R. Effect of *Punica granatum* peel aqueous extract on normal and dexamethasone suppressed wound healing in wistar rats. *International Journal of Pharmaceutical Sciences Review and Research*, Volume 5, Issue 2, November – December 2010
- Mohammed A. *Text Book of Pharmacognosy*, CBS Publishers and Distributors, 2006 pp. 81,116, 372 and 447.
- Dnyaneshwar D. Kokane, Rahul Y. More, Mandar B. Kale, Minakshi N. Nehete, Prachi C. Mehendale, Chhaya H. Gadgoli. Evaluation of wound healing activity of root of *Mimosa pudica*. *Journal of Ethnopharmacology* 2009. 124; 311–315
- Ghosh MN, *Fundamental of experimental pharmacology*, 3rd Edition, Hilton and company, Kolkata, 2005, 193 – 194.
- Kiran K, Asad M. Wound healing activity of *Sesamum indicum* L seed and oil in rats, *Indian J Exp Biol*. 2008 ;46(11):777-82
- Zili Zhaia, Devon M. Haney. Alcohol extract of *Echinacea pallida* reverses stress-delayed wound healing in mice *Phytomedicine* 2009. 16; 669–678
- Pradeep T. Deshmukha, Jennifer Fernandesb, Akarte Atul, Emmanuel Toppo. Wound healing activity of *Calotropis gigantea* root bark in rats. *Journal of Ethnopharmacology*. 2009. 125 178–181
- Cavalitto CJ and Bailey JH, The antibacterial principles of (*Allium sativum* L.): Isolation, physical properties and antibacterial action, *Journal of American Chemical Society*, 66: 195-200, (1994).
- Tsuchiya, H., Sato, M., Miyazaki, T., Fujiwara, S., Tanigaki, S., Ohyama, M., Tanaka, T., Iinuma, M., 1996. Comparative study on the antibacterial activity of phytochemical flavanones against methicillin-resistant *Staphylococcus aureus*. *Journal of Ethnopharmacology* 50, 27–34.
- Ansel S. *Pharmaceutical Dosage Form and Drug Delivery System*. Lippincott 8: 278-281, 2005
- Mukherjee PK. *Quality Control of Herbal Drugs*, Business Horizons, New Delhi, 1: 546-549, 2002.
- Rane, M., Madhura, Mengi, A., Shusma, 2003. Comparative effect of oral administration and topical application of alcoholic extract of *Terminalia Arjuna* bark on incision and excision wounds in rats. *Fitoterapia* 74, 553– 558.

Table1. Phytochemical Analysis of extract of *Ficus racemosa*

Phytochemical	Confirmation
Amino acids	-
Carbohydrates	-
Tannins	+
Alkaloids	+
Flavonoids	+
Saponins	+

Table: 2

z	BREAKING STRENGTH (SKIN)
CONTROL (Simple Saline)	275.0±3.625***
Dexamethasone	175.0±3.522
F.R. AQ + Dexamethasone	245.6±2.811***
F.R. ETH + Dexamethasone	193.3±3.333***

*** - (p<0.05), values are in mean ± SE compared with dexamethasone group

Table: 3

Groups	% WOUND CONTRACTION IN DAYS					Period of Epithelialization (Days)
	Day 2	Day 4	Day 8	Day 12	Day 16	
Control (Simple Saline)	7.3±0.12	14.16±2.12***	34.16±1.23***	53.83±0.12***	73.66±0.13***	19.17± 0.3073***
Dexamethasone	2.16±1.23	6.66±2.24	21.83±0.54	37.00±0.21	53.50±0.32	23.00± 0.2582
FR.AQ. Extract + Dexamethasone	4.16±0.24	10.16±0.32***	29.66±0.54***	43.33±0.21***	63.16±0.12***	21.00± 0.3651***
FR. Eth. Extract + Dexamethasone	3.5±2.21	8.50±1.23***	27.30±2.23***	48.66±0.23***	57.33±0.12***	21.67± 0.2108***

*** - (p<0.05), values are in mean ± SE compared with Dexamethasone group