



## Isolated medial cuneiform fracture-dislocation a case report and review of literature

L.Unyendje, A.Karkazan, F.Ismael, MS. Berrada, A. El Bardouni, M. Kharmaz, MY.O.Lamrani, M.Ouadghiri, A. Lahlou, M. Mahfoud and M. EL Yaacoubi

Mohammed V University, Faculty of Medicine and Pharmacy, IBN SINA Hospital, Orthopedic Department Rabat-Morocco.

### ARTICLE INFO

#### Article history:

Received: 18 April 2013;

Received in revised form:

3 June 2013;

Accepted: 12 June 2013;

#### Keywords

Fracture,  
Dislocation,  
Medial cuneiform.

### ABSTRACT

The authors present unusual case of isolated fracture-dislocation of medial cuneiform bone in a 22-year old after falling from the horse with midfoot taken by the stirrup .The plain x-rays is not likely to reveal a fracture-dislocation on this part of foot .Computing tomography (CT scan) can useful in determing the nature of the injury in such a case. The fracture was treated surgically by performing a through debridement and an internal fixation using kirshner wire after reducing .Ligaments were repaired and a prevention antimicrobial and physiotherapy were instaured. At the end of three months, we obtained a painless foot, stable and the patient was returned his activity.

© 2013 Elixir All rights reserved.

### Introduction

The cuneiform bones located in the midfoot form a block locked by capsular ligament system which makes rarely a isolated injury (1,2,3). all the cuneiform injuries should be accompanied with injuries such as metatarsal fracture dislocation of Lisfranc. Cain (4). These injuries were described in 1815 by Jacques Lisfranc in a rider during a fall of the horse with foot taken up by the sidewalk. Smith et al (5). Cuneiform fracture-dislocation affects mainly young adults during sports Taylor et al. (6), Karim (7), and has been caused by direct impact when a heavy object crash on the midfoot. Its diagnosis is not easy to radiography and often requires a CT scan and magnetic resonance imaging Karim (7). Treatment should not be based on the type of fracture, but the presence of instability and anatomical reduction. An osteosynthesis with Kirshner wire followed by physiotherapy is excellent.

The purpose of study is to describe the particularity of this entity and to make a review of the literature.

### Case Report

A 22 year- old man with no history pathological notable was presented in emergency of Ibn Sina hospital after a fall of horse in which the right foot was caught between the horse and the curb caused traumatism to the foot.

On admission the clinical examination found the patient awake and oriented. He had a great deal of pain, edema deformity of the dorsal aspect of the midfoot and a linear wound on the internal face, exposed bone (Fig. 1) .No vascular or neurological injury was found.

The plain X-Ray film noted the dislocation of the first cuneiform (fig.2). CT scan revealed a fracture separation between the navicular and medial cuneiform was demonstrated on the first ray. (Fig. 3).He was admitted in operating room, under lumbar anesthesia the wound was dressing , and the fracture was fixed with two crossed kirschner wires, ligaments were stitched (Fig. 4).1500UI of antitetanic serum and an antibiotic was introduced .After two weeks the wound was

healing and ablation pins were at six weeks followed by physiotherapy. Three months later the foot was anatomically stable and painless.

### Discussion

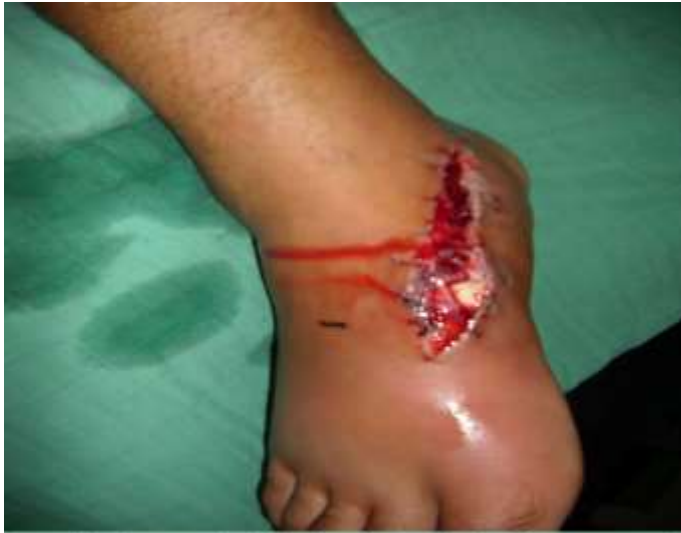The isolated fracture-dislocation of the first cuneiform is rarely seen, there are an union and connections with others bones of the midfoot such an injury although fracture of the midfoot are common and these fractures are frequently associated with injuries such as metatarsal fracture- dislocation of Lisfranc. Cain (4).

It is caused by a fall from horse with foot caught in the stirrup. The mechanisms of the injury in this case is a crushing of an axial load through on the midfoot (Taylor (6) associated by forced plantar flexion (Creighton (8). The intercuneiform ligament and a dislocation in the first ray of the toes results , since there are strong ligaments in the plantar session and an avulsion fracture must have accompanied the dislocation.

The clinical diagnosis was based on the pain of the midfoot with an avulsion dislocation of medial cuneiform bone. Davies et al. (9) have reported on their observation by the existence of edema in relation to the line of cuneiform. Plain radiographs are inadequate for diagnosis (Fig. 2) and required a scan CT to analyze and to confirm the fracture and the mode of injury (Fig. 3)

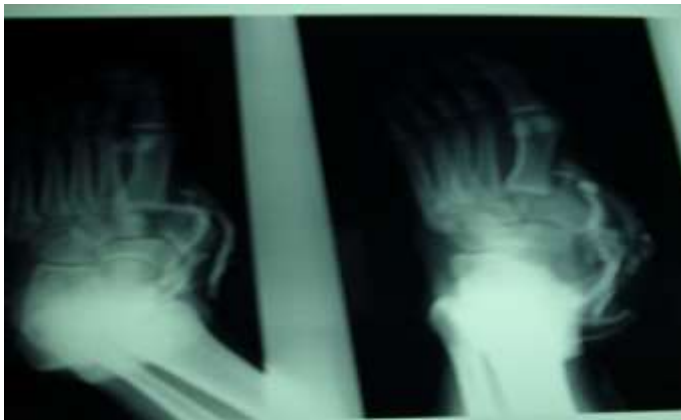The treatment consisted by debridement followed by reduction and for immobilization strong anchors such as screws are recommended in many cases but kirschner wire was a strong enough in this case and good stability resulted. Olson (10) prefer a closed reduction and casting the use of non-weight bearing holding the foot in neutral position .If we have Instability Levine et al (11) preferred an opening wedge followed by a internal fixation with screws or pins, Campson (12) adds the attachment of the tendon of tibialis anterior. When the crash caused a loss of substance Maitra et al (2) have obtained a satisfactory result by grafting the a cortico-cancellous bone. Complications such as arterial injury and re-dislocation are

sometimes associated with this type of injury. Un one case of nonunion has been reported by Loud et al (13) and treated with open reduction and internal fixation. No complications were seen in this case.

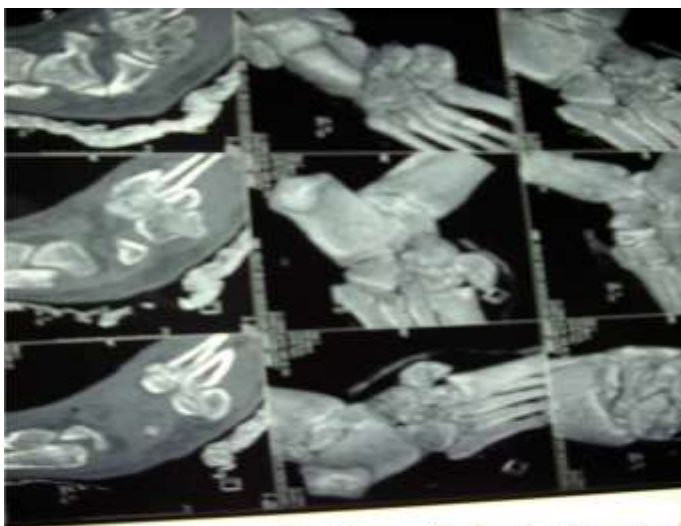


*figure1:clinical appearance of medial cuneiform fracture-dislocation with cutaneous wound*

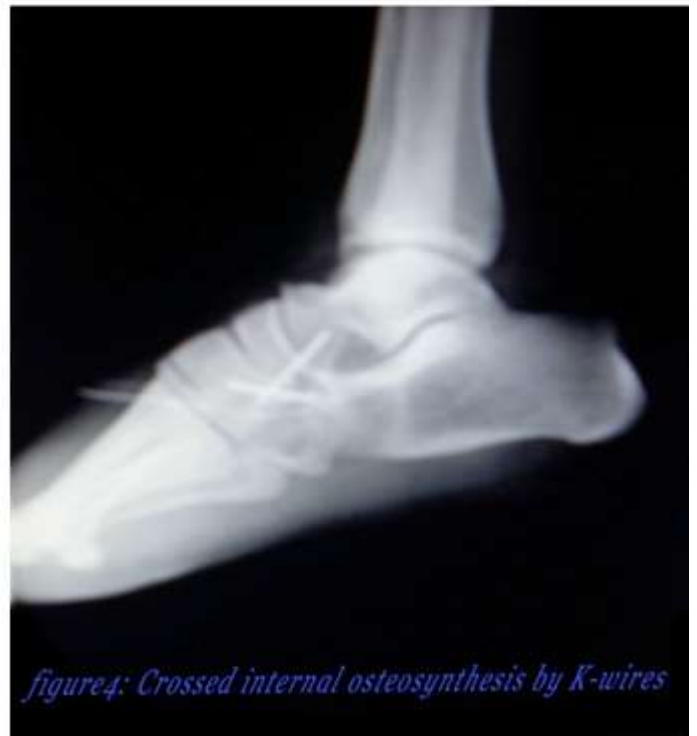
**Figure 1: Clinical appearance of open fracture-dislocation of medial cuneiform**



*figure 2:anteroposterior radiograph of midfoot showed displacement of medialcuneiform*



*figure 3: CT scan of midfoot confirmed fracture-dislocation of medial cuneiform*



*figure4: Crossed internal osteosynthesis by K-wires*

#### Conclusion

The isolated fracture-dislocation of the medial cuneiform is typically rare. These fractures are frequently associated with injuries such as metatarsal fracture- dislocation of Lisfranc. It caused during a fall on horse with foot in plantar flexion forced. Its diagnosis confirmed by the CT scan .The crossed fixation with kirshener wires was made. Three months later, the patient returned to full activities.

#### References

- 1.Sangeozan B, Mayon K, Hansen S, Intraarticular fracture of the foot: Talus and Lesser tarsals; Clin orthop Relat Res 1993; 292:135-141
2. Maitra R, Degnore LT, Isolated dislocation of the middle cuneiform in a farmer: A case report and review of the literature. Foot int 1997; 18: 735-738
3. Mcglinchey JJ, Dislocation of the intermediate cuneiform. Injury 1981; 12: 501-502
4. Cain PR, Seligson D. Lisfranc fracture-dislocation with intercuneiform dislocation. foot ankle int 1981 :156-160
5. Smith BR, Begeman PC, Leland R, Meehan R, Levine RS, Yang KH, Le roi AI, Un mécanisme de la blessure de l'avant-pied dans les accidents de voiture : Prévention des accidents de la route 2005 ;6(2) :156-69
6. Taylor SF, Heidenreich D. Isolated medial cuneiform fracture Injury 2008; 110(8):848-9
7. Karim M, Khan MD, Peter D, Bruckner MD, Chris Bradshaw MD. Stress fracture of the medial cuneiform bone in a runner. Clin J of sport med.1993 (3):262-264
- 8.Creighton R , Sonoga A, Gordon G ,Stress fracture of tarsal middle cuneiform bone's. Am Med Assoc Podiatr. 1990; 80(9) 489-95
9. Davies M, Saxby T. Intercuneiform instability and the gap sign. Foot ankle int 1999; 20: 606-609
10. Olson R, Mendicino S, Rockett M, Isolated medial cuneiform fracture review of the literature and report of two cases. Foot ankle int 2000; 21: 150-153

11. Levine B, Stoppacher R, Kristiansen T, Plantar lateral of the medial cuneiform: A case report. *Foot ankle int* 1998; 19: 118-119
12. Campson JP, An irreducible medial cuneiform fracture-dislocation. *Injury* 1992; 23: 501-502
13. 13. Bruyant M, Baird D, A case of non union of the medial cuneiform. *Injury* 1993; 24:207-208.