



Nephrogenic adenoma of the bladder : a case report

Y.Essatara¹, M.Asseban¹, M.H. Benazzouz¹, H. El Sayegh¹, A. Ikeⁿ¹, L. Benslimane¹, K.Znati^{2,*} and Y. Nouini¹

¹Urology Department A, Chu Ibn Sina, Rabat.

²Pathology Department, Chu Ibn Sina Rabat.

ARTICLE INFO

Article history:

Received: 8 March 2014;

Received in revised form:

25 June 2014;

Accepted: 24 July 2014;

Keywords

Nephrogenic,
Metaplasia,
Bladder.

ABSTRACT

Nephrogenic metaplasia is a benign tumor characterized by urothelial tubulo - papillary structures. It is also called nephrogenic adenoma . It is a benign lesion and highly prone to recurrency. We report a case of a bladder nephrogenic metaplasia of a 65 years old patient with hematuria and POLLAKIURIA. Clinical examination was normal . Ultrasonography showed a circumferential thickening bladder , while cystoscopy showed a tumor at the dome and the right side. A transurethral resection of the bladder was performed. Histological study concluded at the existence of nephrogenic metaplasia of the bladder mucosa . The evolution was favorable and postoperative controls, including cystoscopy and intravenous urography (IVU) at 1, 3 and 6 months were normal.

© 2014 Elixir All rights reserved.

Introduction

Nephrogenic metaplasia (nephrogenic adenoma) is a rare urothelial lesion , which can interest the pyelum, the ureter as well as the bladder or urethra. This lesion was first described by Davis in 1949 [16], but it was Friedman and KUHLENBECK who first give it the denomination of nephrogenic adenoma, considering its resemblance with the glandular morphological structure of the kidney 's collecting duct system [26] .

Report:

Mr TO age 65 , chronic smoker at 40 packs / year. This patient has diabetes , well balanced with insulin for 5 years and had 6 month of medical treatment for urogenital tuberculosis . he also has a surgical procedure for nephrolithiasis in 1994. Clinical history reported intermittent hematuria associated with urinary disorders as pollakuria, obstructive symptoms for three years. Clinical examination was normal. The laboratory tests including a complete blood count and chemistry panel has highlighted renal failure at 46 mg / l creatinine. The cyto-bacteriological examination of urine showed an infection by *Klebsiella pneumoniae* multidrug-resistant treated with amikacin . Ultrasonography showed a circumferential wall thickening of the bladder measuring 15 mm and bilateral ureterohydronephrosis. Cystoscopy confirmed the presence of two tumor at the bladder dome and the right side face . The treatment consisted of transurethral resection of the bladder taking all lesions. Histological examination of the fragments collected showed at the surface of the bladder mucosa numerous papillae (Figure 1) lined in surface by metaplastic cells SOMETIMES Cubo- cylindrical and sometimes in brad (Figure 2). The cells were devoid of cyto- nuclear atypia or mitosis . Histological examination revealed in conclusion a nephrogenic adenoma. Postoperative controls including cystoscopy and intravenous urography at 1.3 and 6 months found no recurrence

Discussion:

The nephrogenic adenoma is a rare lesion of the urothelium and of Benin character. It may interest any filiaire urologic from pyeloma to urethra. There is a male predominance in adults (sex ratio of two men on one woman), contrary to the child population where this trend is reversed. The average age

is 44 years (7-79 years). In our case the patient was aged 65 years at the moment of diagnosis [1-6].

Locations are bladder in 70% of cases [7, 8, 9]. The most common location is usually trigonal bladder (25% of cases), but it can be found at the side faces (23%) at the dome (20%) at the ureteral orifices (11%) at the wall posterior (20%) and the anterior face (1%) [8]. Several other atypical localizations have been reported. They can be ureteral [10,11], urethral [12] sit in a bladder diverticulum [15, 11]. It also has even been reported lesions at urethroplasty using the bladder mucosa [15, 17], or on a replacement enterocystoplasty [18]. Lesions in our study were on the dome on the right side face and retro-trigonal region.

Etiological factors involved in the genesis of this lesion are unknown. However, it is often associated with a history of surgery [8] , chronic infection [8] , the presence of urothelial carcinoma [19] , immunosuppressive therapy [20, 19] or intravesical instillations [21, 22]. These factors are commonly responsible for chronic irritation of the bladder mucosa. The delay between the aggression of urothelial mucosa and the discovery of the tumor varies from 3 months to 11 years with a maximum frequency of 3 years [24]. At the pathogenic viewpoint, the theory of the metaplastic reaction evoked by Mostofi in 1954 [23] , is currently used by most authors . This assumption is for a metaplastic transformation of urothelial cells in response to a risk factors. Indeed, almost all carriers of the nephrogenic metaplasia have one or more contributing factors . In our case, the patient had a history of urogenital tuberculosis treated, several episodes of urinary infection and finally a history of renal surgery .

The most common clinical signs are, as in our case, nonspecific , and include hematuria , dysuria, urinary urgency , suprapubic pain and flank pain [7,23] . In 20% of cases the lesions are discovered during endoscopic exams ,ultrasound or routine inspections , while patients showed no clinical sign. On the pathological level, there is a lesion of variable architecture. Typically, it is made of tubulous structures , tubulo- cystic , polypoid and papillary more rarely , as in our patient. The normal urothelial epithelium surface is replaced by an unistratified epithelium made by a single layer of cuboidal

cells, cubo-cylindrical or flattened cells with round nuclei in globular called aspect of bud. This metaplasia precedes the appearance in the lamina propria of tubes that resemble to renal tubular system centered by a eosinophile (PAS and Alcian blue positive) in case of tubulous or tubulo-cystic forms meanwhile it precedes the appearance of papillae forms in papillary or polypoid forms. Immunohistochemical study may be useful to confirm the diagnosis of nephrogenic adenoma and avoid the wrong diagnosis of urothelial or prostatic tumor. Indeed tumor cells express racemase (P504S) PAX8/PAX2, cytokeratin 7, and cytokeratin 20. CEA, PSA, p63 are not expressed. The endoscopic treatment is currently based on the resection of the lesion. Treatment should be combined, wherever possible, to the elimination of irritative factors. In rare cases, radical cystectomy is indicated, either because of a preoperative histological diagnosis of cancerous lesions associated, either because of the significant reduction in bladder capacity, as is the case for tuberculous bladders [12]. Let alone the Nephrogenic metaplasia does not justify the practice of cystectomy.

The evolution of this lesion is benign, no cases of malignant transformation have been reported. For patients who received long-term monitoring, recurrences were observed in 10% to 80% of cases [7, 25].

Conclusion

Nephrogenic metaplasia is a rare benign tumor of the urothelium. The bladder is the most common location. Clinical signs are nonspecific and usually related to predisposing factors (infections, inflammation, bladder tumor). Only histological examination makes the diagnosis and proves the Benin nature of this lesion. Endoscopic resection therefore has two objectives, diagnosis and therapy. The evolution remains characterized by recidivism.

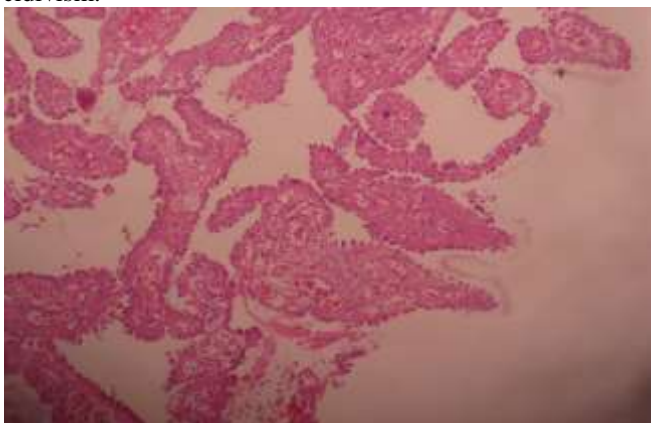


Figure 1. Proliferation of buds made on the surface of the bladder mucosa

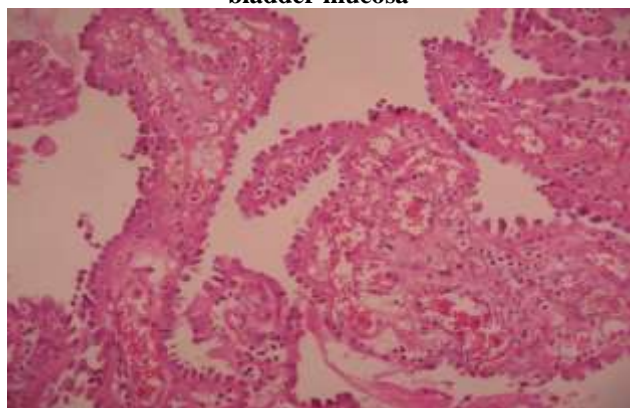


Figure 2. HESx100: Buds lined on surface with globular nuclei cells

Références

- GERRIDZEN R.G., DE JESUS F., WESLEY JAMES T., SCHILLINGER J.F. Nephrogenic adenoma with bladder extrophy and immunosuppression. *Urology*, 1991, 38, 345-346.
- HUSAIN A.N., MARIN A.R., SCHUSTER G.A. Nephrogenic metaplasia of urinary tract in children: Report of three cases and review of the literature. *Pediat. Pathol.*, 1988, 8, 293-300.
- JOHANNES A., PRANTL F., PESCHKE P., WENZL H. Sogenanntes nephrogenes adenom (adenomatose metaplasie). Sel tene tumorartige adenopapillare lasion des urothels in der Harnblase bei einen 6-jährigen knaben nach trauma. *Urologe - A.*, 1988, 27, 204-206.
- NOLD S.R., TERRY W.J., CERNIGLIA F.R., HAWKINS E.P., ROTH D.R., GONZALES E.T. Nephrogenic adenoma of the bladder in children. *J. Urol.*, 1989, 142, 1545-1547
- STEFFENS J., SEITZ G., WERNERT N., ALLOUSSI S., ZIEGLER, M. Nephrogenic adenoma of the bladder in a child – immunohistochemical and lectin histochemical investigations. *Eur. Urol.* 1990, 18, 64-67.
- ZIMMERMANN K., AMIS E.S. J.R., NEWHOUSE J.H. Nephrogenic adenoma of the bladder : urographic spectrum. *Urol. Radiol.*, 1989, 11, 123-126
- FOURNIER G.: Métaplasie néphrogène de l'appareil urinaire. *Prog. Urol.*, 1996; 6 : 861-868.
- McINTIRE T., SOLOWAY M.S., MURPHY W.M. : Nephrogenic adenoma. *Urology*, 1987 ; 29 : 237-241.
- PEEKER R., ALDENBORG F., FA L L M. : Nephrogenic adenoma. A study with special reference to clinical presentation. *Br. J. Urol.*, 1997 ; 80 : 539-542.
- BENCHEKROUN A., LACHKAR A., BEN SLIMAN L., BELAHNECH Z., MARZOUK M., FAIK M. : Métaplasie néphrogénique de l'uretère. *Prog. Urol.*, 2000 ; 10 : 287-290.
- GOKASLAN S.T., KRUEGER J.E., ALBORES-SAAVEDRA J. : Symptomatic nephrogenic metaplasia of ureter : a morphologic and immunohistochemical study of four cases. *Mol. Pathol.*, 2002 ; 15 : 765-770.
- ALLAN C.H., EPSTEIN J.I. : Nephrogenic adenoma of the prostatic urethra: ba mimicker of prostate adenocarcinoma. *Am. J. Surg. Pathol.*, 2001 ; 25 : 802-808
- HEFFERNAN J.P., HUISMAN T.K. : Nephrogenic adenoma in a bladder diverticulum. *J. Urol.*, 1994 ; 152 : 1208-1210.
- ODZE R., BEGIN L.R. : Tubular adenomatous metaplasia (nephrogenic adenoma) of the female urethra. *Int. J. Gynecol. Pathol.*, 1989 ; 8 : 374-380.
- GARCIA-PENIT J., ORSOLA A., PARADA R., ALGABAF., GARAT J.M.: Synchronous nephrogenic adenoma in the bladder and neourethra (bladder mucosa) in a boy. *BJU International.*, 1999 ; 84 : 169-170.
- DAVIS T.A. : Hamartoma of the urinary bladder. *Northwest. Med.*, 1949 ; 48: 182-185.
- WEINGARTNER K., KOZAKIEWICH H.P., HENDREN W.H. : Nephrogenic adenoma after urethral reconstruction using bladder mucosa : report of 6 cases and review of the literature. *J. Urol.*, 1997 ; 158 : 1175-1177.
- GOLDMAN H.B., DMOCHOWSKI R.R., NOE H.N. : Nephrogenic adenoma occurring in an augmented bladder. *J. Urol.*, 1996 ; 155 : 1410.
- TSE V., KHADRA M., EISINGER D., MITTERDORFER A., BOULAS J., ROGERS J. : Nephrogenic adenoma of the bladder in renal transplant and non-renal transplant patients : a review of 22 cases. *Urology*, 1997 ; 50 : 690- 696.

20. THONG W., HINSCH R., CLOUSTON A., NICOL D. : Nephrogenic metaplasia : long-term haemodialysis and anuria as potential risk factor and reversibility with renal transplantation. *Nephrol. Dial. Transplant.*, 1995 ; 10 : 2101-2103.
21. STILMANT M.M., SIROKY M.B. : Nephrogenic adenoma associated with intravesical bacillus Calmette-Guérin treatment : A report of 2 cases. *J. Urol.*, 1986 ; 135 : 359-361.
22. WOOD D.P., STREEM S.B., LEVIN H.S. : Nephrogenic adenoma in patients with transitional cell carcinoma of the bladder receiving intravesical thiotepa. *J. Urol.*, 1988 ; 139 : 130-131.
23. MOSTOFI F.K. Potentialities of bladder epithelium. *J. Urol. (Baltimore)*, 1954, 71, 705-714.
24. BILLEREY C., KHAMLU K. , REGIN J.P., BITTARD M. , OPPERMANN A.: La métaplasie néphrogénique de la muqueuse urothéliale. A propos de onze observations. *Ann. Urol.*, 1983,17, 340-346.
25. GONZALEZ J.A., WATTS J.C., ALDERSON T.P. : Nephrogenic adenoma of the bladder : report of 10 cases. *J. Urol.*, 1988 ; 139 : 45-47.
26. FRIEDMAN N.B., KUHLENBECK H: Adenomatoid tumors of the bladder reproducing renal structures (nephrogenic adenomas). *J. Urol.*, 1950 ; 64 : 657-670