

Comparison of two methods of local anesthesia before transrectal ultrasound-guided biopsies of prostate

Ousmane Nago Dembele, Ali Beddouch, Hamade Mouthi, Hachem Sayegh, Ali Iken, Lounis Benslimane and Yassine Nouini

Department of Urology, Chu Ibn Sina, Rabat, Morocco.

ARTICLE INFO

Article history:

Received: 1 April 2016;

Received in revised form:

29 April 2016;

Accepted: 2 May 2016;

Keywords

Analgesic,
Transrectal ultrasound,
Prostate.

ABSTRACT

We compare the analgesic efficiency of the endo-rectal instillation of xylocaine gel compared to peri-prostatic infiltration xylocaine biopsies before transrectal ultrasound guided prostate Patients and Methods: Between November 2013 and March 2014, candidates for prostate biopsies were randomized into 2 groups. In group 1, 10 ml of Xylocaine 2% gel was instilled in the rectum 10 minutes before biopsy, while patients in group 2 benefited from the periprostatic infiltration of 5 ml injection of Xylocaine 2% in two equal injections, 4 min before prostate biopsies. A visual analogue scale possible to assess pain during anesthesia (VAS 1) and during prostate biopsies (VAS 2) and finally 30 min after the end of these (VAS 3).

© 2016 Elixir All rights reserved.

Introduction

Aspiration biopsies transrectal ultrasound-guided prostate (PBP), common practice, are usually performed without anesthesia. Many studies aimed at reducing pain during the procedure leading to the sometimes conflicting results.

We compare in a randomized two local anesthesia methods, namely the endo-rectal instillation of Xylocaine gel and infiltration peri-prostatic Xylocaine under ultrasound guidance.

Material and Methods

Between November 2013 and March 2014, the consultant in urology patients at the Ibn Sina University Hospital to undergo the PBP, were included in this study. A history of allergy to xylocaine, an anticoagulant treatment is prolonged, or the impossibility of using a visual analog scale (VAS) were the main criteria for exclusion. Rectal enema and antibiotic prophylaxis spillway preceded by Ofloxacin the PBP.

After obtaining patient consent, they were randomized into 2 groups. All examined in left lateral decubitus, the PBP were performed using a transrectal ultrasound probe MHz. In group 1, was administered 10 ml of Xylocaine 2% gel in the rectum while in group 2, local anesthesia before PBP was by peri-prostatic infiltration of 5 ml of Xylocaine 2% each nerve plexus located at the junction of the prostate and seminal vesicles and, under ultrasound guidance with a 22 gauge Chiba needle 25 cm. After a period of 10 min in group 1 and 4 min in group 2, the PBP were performed using a biopsy needle 18 Gauge 20 cm disposable. A series of 12 PBP was generally achieved.

Prior to installation, the patient was informed on the VAS pain from 0 to 10: 0 representing no pain, 1 to 3, with minor aches, 4-6, to moderate pain, and 7-10, with major pain. Pain was measured during anesthesia (VAS 1), during the PBP (VAS 2) and 30 min at the end thereof (VAS 3). Patients were reviewed 3 weeks after the PBP. The various data were then listed, complications included: namely rectal bleeding,

hematuria or persistent hémospémie, fever, acute urinary retention or other complication.

Results

69 patients were randomized to 35 in group 1 and 34 in Group 2. The characteristics of our patients are shown in Table I.

Table 1. Characteristics of patients.

	Group 1 n=35	Group 2 n=34
Average age (years)	69	66
Number of patients in normal rectal touch(%)	29 (83%)	31 (91%)
PSA medium (ng/ml)	70	28
Average volume of prostate (cc)	48	59
Average number of biopsies	12	12
Number of tumor biopsies (%)	12 (34%)	9 (26%)

Regarding the assessment of pain by VAS, pain was lower in group 2 regarding VAS 2 (3.5 in group 1 vs 1.5 in group 2) and VAS 3 (0.5 in group 1 vs 0.1 in group 2), by against lesser in group 1 for the score VAS 1 (0.1 in group 1 vs 0.2 in group 2).

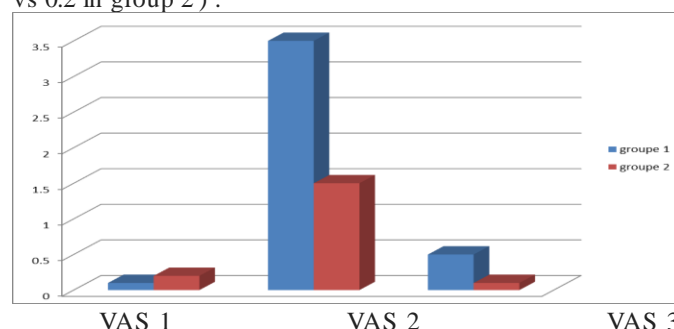


Figure 1. Comparison of VAS scores of the 2 groups

A classification of patients according to age (<60 years, 60 to 70 years, > 70 years), their serum PSA levels (<10 ng/ml, > 10 ng/ml), their prostate volume (<50 cc, > 50 cc) or the number of PBP was no influence on the assessment of pain by VAS. All patients were without prostate biopsy history.

Furthermore, patients in whom the pathological result of PBP was adenocarcinoma felt less pain for the VAS evaluation 2 and 3.

Table 2. Comparison VAS according to presence or absence of tumor tissue to pathological results.

	Malignant tissue n=22	Benign tissue n=47
VAS 1 medium	0,8	0,6
VAS 2 medium	1,0	2,9
VAS 3 medium	0,9	1,3

Discussion :

Considered painful and uncomfortable for a significant number of patients [1, 2 , 3, 4 , 5] , the PBP sparked numerous local anesthesia methods. A randomized prospective study brings together two technical local anesthesia, endo-rectal instillation Lidocaine gel , described by Desgrandchamps [6] , and periprostatic infiltration of Lidocaine .

Most studies show the efficacy of ultrasound-guided infiltration of Lidocaine with different sites, or injection volumes numbers. The time between local anesthesia and prostate biopsy is generally set at 4 min in connection with the pharmacokinetics of injectable Lidocaine .

Having proven its effectiveness in many procedures , including cystoscopy or gastrointestinal endoscopy , it was suggested to provide the anesthetic Lidocaine gel as before PBP [7 , 8]. This gel has an analgesic effect during the introduction of the endorectal probe and during the puncture of the rectal mucosa. Desgrandchamps [6] found no superiority of the gel compared to placebo . Rather, Issa has demonstrated the simplicity and effectiveness of this gel . [9] published results [10, 11] have demonstrated that injection of 10 ml of 1% Lidocaine was sufficient. Some comparative studies have demonstrated the superiority of infiltration relative to the gel Lidocaine [12, 13] , based on the fact that the pain during biopsies is caused by the puncture of the prostatic capsule , the latter can not be anesthetized by infiltration of autonomic nerve fibers of the latero -prostatic pedicles [14]

However, all the supporters Lidocaine gel recommend a period of 10 minutes between applying the gel and the achievement of prostate biopsies [15] , time seems long , but referred to the Vidal data.

Furthermore , patients with tumor biopsies complained of less pain , despite identical VAS scores at local anesthesia, but without sufficient explanation.

The inherent complications of anesthesia or biopsy are exceptional. Most studies do not indicate any major complications. Hematuria or self limiting hémospemie are the most frequently observed minor complications .

With relatively low VAS scores at each measurement , our study reveals that patients under local anesthetic Lidocaine by intra- rectal gel have an average pain score more High compared to periprostatic anesthetic infiltration.

Conclusion

Periprostatic block infiltration of xylocaine , allows better patient comfort during biopsies and 30 min after the end thereof .

Conflict of interest

The authors declare no conflict of interest

Copyright contribution

All authors have contributed to the conduct of this research work; they have read and approved the final manuscript

Références

1. ADDLA S.K., ADEYOJU A.A.B., WEMYSS-HOLDEN G.D., NEILSON D.: Local anaesthetic for transrectal

ultrasound-guided prostate biopsy: a prospective, randomised, double-blind, placebo-controlled study. *Eur. Urol.*, 2003; 43 : 441-443.

2. ALAVI A.S., SOLOWAY M.S., VAIDYA A., LYNNE C.M., GHEILER E.L.: Local anaesthesia for ultrasound guided prostate biopsy: a prospective randomised trial comparing 2 methods. *J. Urol.*, 2001; 166: 1343-1345.

3. BERGER A.P., FRAUSCHER F., HALPERN E.J., SPRANGER R., STEINER H., BARTSCH G., HORNINGER W. : Periprostatic administration of local anaesthesia during transrectal ultrasound-guided biopsy of the prostate : a randomised, double-blind, placebo-controlled study. *Urology*, 2003; 61: 585-588.

4. BULBUL M.A., HADDAD M.C., KHAULI R.B., HEMADY K., SHAAR A., KHOUZAMI R., WAZZAN W.: Periprostatic infiltration with local anaesthesia during transrectal ultrasound-guided prostate biopsy is safe, simple, and effective. A pilot study. *J. Clin. Imag.*, 2002 ; 26 : 129-132.

5. CRUNDWELL M.C., COOKE R.W., WALLACE D.M. : Patients' tolerance of transrectal ultrasound-guided prostate biopsy : an audit of 104 cases. *Br. J. Urol.*, 1999; 83: 792-795.

6. DESGRANDCHAMPS F., MERIA P., IRANI J., DESGRIPPES A., TEILLAC P., LE DUC A. : The rectal administration of lidocaine gel and tolerance of transrectal ultrasonography-guided biopsy of the prostate : a prospective randomised placebo-controlled study. *Br. J. Urol.*, 1999; 83: 1007-1009.

7. DESMOND P.M., CLARK J., THOMPSON I.M., ZEIDMAN E.J., MUELLER E.J.: Morbidity with contemporary prostate biopsy. *J. Urol.*, 1993; 150: 1425-1426.

8. DJAVAN B., WALDERT M., ZLOTTA A., DOBRONSKI P., SEITZ C., REMZI M., BORKOWSKI A., SCHULMAN C., MARBERGER M.: Safety and morbidity of first and repeat transrectal ultrasound guided prostate needle biopsies: results of a prospective European prostate cancer detection study. *J. Urol.*, 2001; 166: 856-860.

9. ISSA M.M., BUX S., CHUN T., PETROS J.A., LABADIA A.J., ANASTASIA K., MILLER L.E., MARSHALL F.F. : A randomised prospective trial of intrarectal lidocaine for pain control during transrectal prostate biopsy : the Emory University experience. *J. Urol.*, 2000; 16: 397-399.

10. KAVAR I., MABJEESH N.J., MATZKIN H: Randomised prospective study of periprostatic local anaesthesia during transrectal ultrasound-guided prostate biopsy. *Urology*, 2002; 59: 405-408.

11. LEIBOVICI D., ZISMAN A., SIEGEL Y.I., SELLA A., KLEINMANN J., LINDNER A.: Local anaesthesia for prostate biopsy by periprostatic lidocaine injection: a double-blind placebo controlled study. *J. Urol.*, 2002; 167: 563-565.

12. LYNN N.N., COLLINS G.N., BROWN S.C., O'REILLY P.H.: Periprostatic nerve block gives better analgesia for prostatic biopsy. *Br. J. Urol.*, 2002; 90: 424-426.

13. MATLAGA B.R., LOVATO J.F., HALL M.C. : Randomised prospective trial of a new local anaesthetic technique for extensive prostate biopsy. *Urology*, 2003; 61: 972-976. 14. NASH P.A., BRUCE J.E., INDUDHARA R., SHINOHARA K. : Transrectal ultrasound guided prostatic nerve blockade eases systematic needle biopsy of the prostate. *J. Urol.*, 1996; 155: 607-609.

15. RODRIGUEZ A., TAZIU H., KYRIAKOU G., LERAY E., LOBEL B., GUILLE F: Apical periprostatic nerve block versus endorectal lidocaine gel. *Prog. Urol.*, 2002; 12: 1228-1233.