

Foreign Body at the Root of the Verge at a Young Man of 27 Years

Ousmane Nago Dembele, Youssef Kadouri, Hachem Elsayegh, Ali Iken, Lounis Benslimane And Yassine Nouini
Department of Urology, Chu Ibn Sina, Rabat Morocco.

ARTICLE INFO

Article history:

Received: 9 May 2016;

Received in revised form:

17 June 2016;

Accepted: 25 June 2016;

Keywords

Foreign body,
Scrotal ultrasound.

ABSTRACT

We report the case of a young man aged 23, victim of an accident to type up falling penetration with thorns wood at the side of the inner right thigh. A scrotal ultrasound scan with erectile body objectified a strong allure foreign body straight. A mini-incision made at the level of the symphysis pubis allowed the removal of the foreign body.

© 2016 Elixir All rights reserved.

Introduction

This is Mr. A. K 23 year old farmer was received consultation for pain in the pubic symphysis in front of the dorsal aspect of the penis. The patient reported the questioning a notion of a falling tree during a fruit picking it 8 months ago with the point of impact the inside of the thigh, associated with the penetration of several thorns wood developed impact

The spines were extracted Home emergency department there are 8 months and the patient reported no hematuria or urethral bleeding after the fall.

After 8 months the patient consulted for pain in the pubic symphysis in front of the dorsum of the penis, clinical examination revealed the presence of a strong allure foreign object, mobile, linear

Scrotal ultrasound with Doppler scan of the erectile bodies objectified presence next to the small curve of the root of the penis of a linear foreign body picture fine of about 40 mm in length, with posterolateral oblique orientation, located 4 mm from the right cavernous body, and whose end is 4 mm from the skin surface.

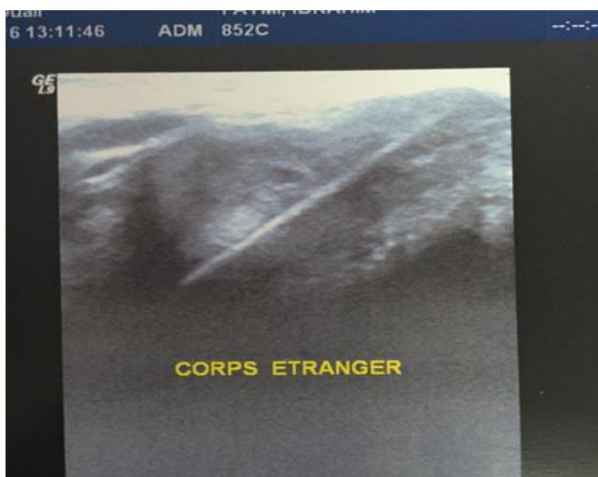


Figure 1. Ultrasound showing a hyperechoic linear picture next to the root of the penis.

The patient underwent a mini incision at the root of the penis after local anesthesia that allowed the removal of the foreign body.

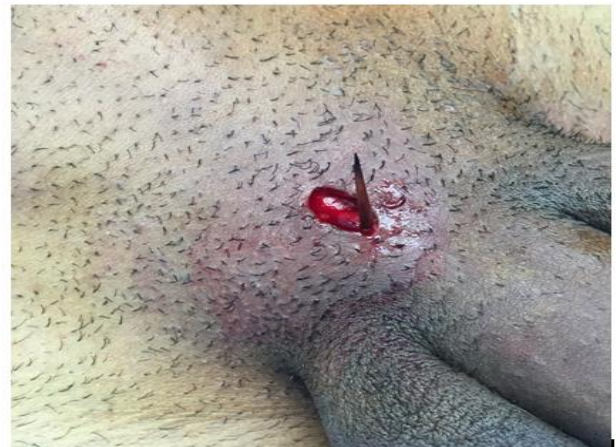

Figure 2. Removal of the foreign body by a mini-incision at the pubic symphysis.

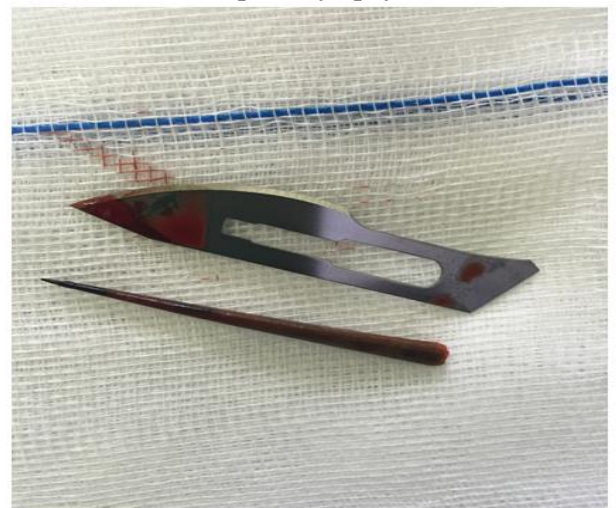

Figure 3. Exposure of the foreign body after extraction.

The postoperative course was uneventful, with disappearance of symptoms immediately after surgery

Comment

The presence of a foreign body moving next to the root of the penis, in all cases pose the question of its mode of penetration.

In the case of our patient it is most likely to migrate a non- extracted wood thorn in home emergency department. In the literature many foreign body migration to the bladder have been reported (intrauterine device, IUD)

Conclusion

The migration of a foreign body from the inside of the thigh to the root of the penis is a rare phenomenon. The examination, clinical examination and ultrasonography allow the diagnosis, treatment consists of the extraction of foreign bodies.