

# Splenic Hydatid Cyst Calcified

Slaoui A and Bakloul F

Urology B, IbnSinaUniversity Hospital, Rabat, Morocco.

### ARTICLE INFO

#### Article history:

Received: 25 February 2016;

Received in revised form:

20 September 2016;

Accepted: 30 September 2016;

#### Keywords

Cyst,  
Hydatid,  
Splenic,  
Calcified.

### ABSTRACT

The hydatid cyst of the spleen is a rare affection. The location splenic comes in 3rd position after the liver and lungs. In the absence of really effective medical treatment, splenic hydatid disease often leads to surgery. We report the case of a patient with calcified splenic hydatid cyst discovered incidentally and in whom the therapeutic decision was abstention and monitoring.

© 2016 Elixir All rights reserved.

### Introduction

A patient of 54 years with a chronic history as smoking was hospitalized in urology department for care of a bladder tumor. As part of its staging, a thoraco- abdominopelvic CT was requested. He revealed the presence of a calcified hydatid cyst spleen, liver and lung were unharmed. The patient showed no hyper eosinophilia and hydatid serology was positive. The splenic hydatid cyst was asymptomatic and calcified that's why the therapeutic decision was abstention and monitoring. To this day the patient had no complications.

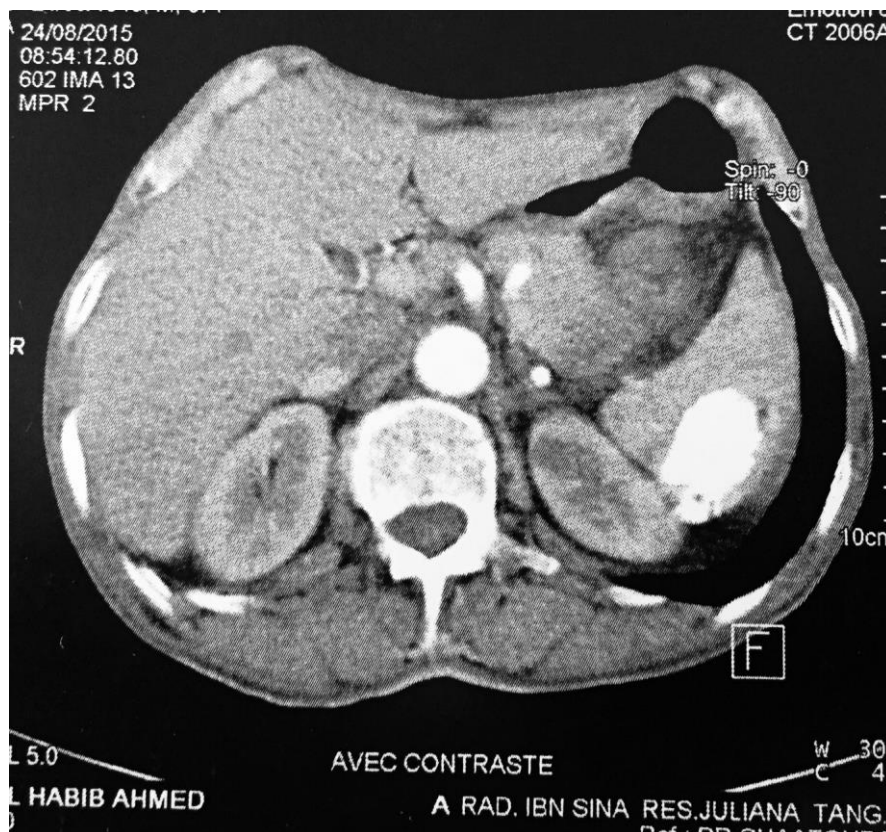
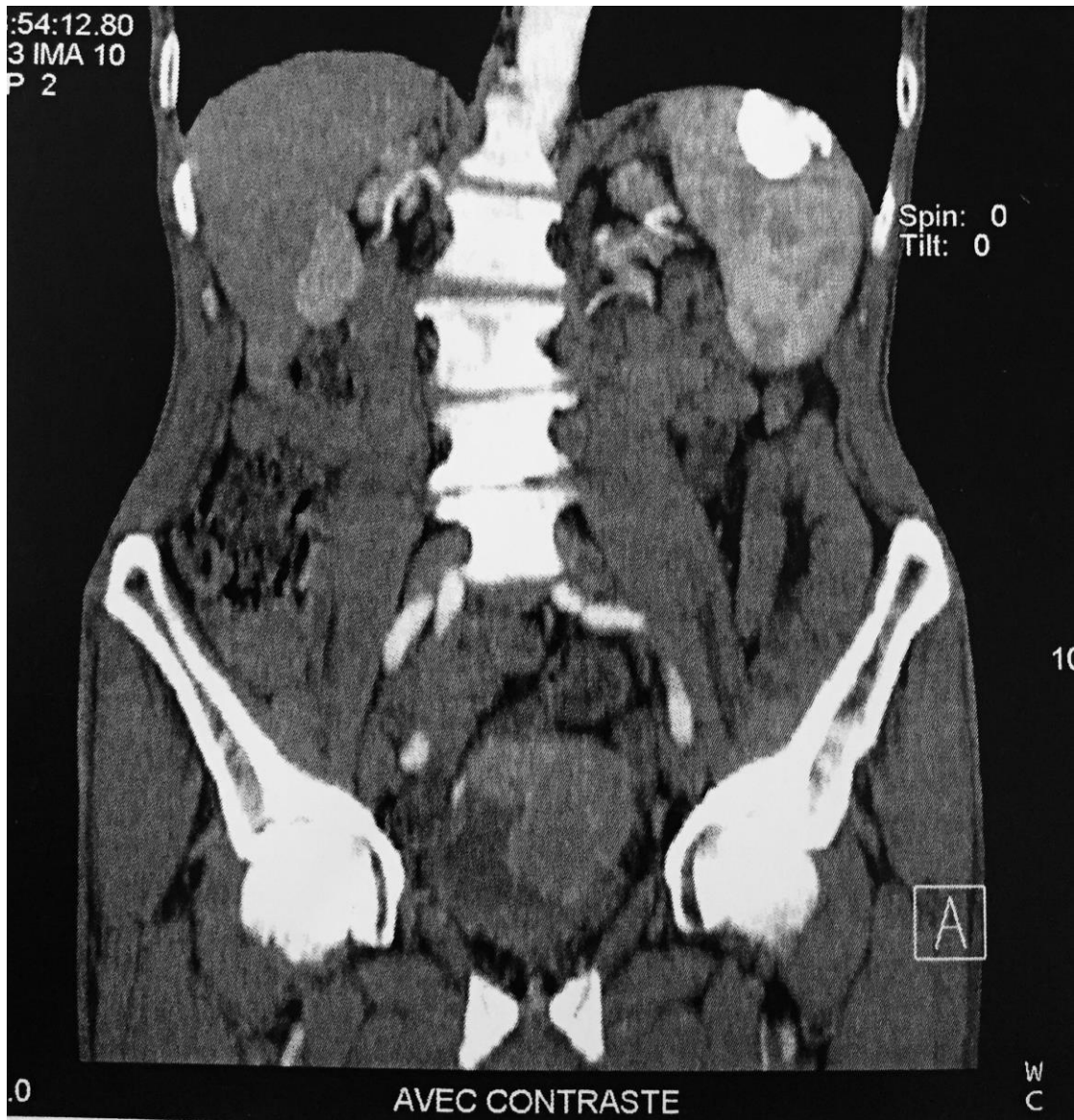


Figure 1. Hydatid cyst of the spleen (coronal section)



**Figure 2. Hydatid cyst of the spleen (Reconstruction)**

The authors declare no conflict of interest.