

SOCCKER SYNDROME – 4: “MANUAL THERAPEUTIC CORRECTIONS” FOR COMMON INNOMINATE MALALIGNMENTS

Ganesh Elumalai and Sushma Chodisetty

Department of Anatomy and Neuroscience, College of Medicine, Texila American University, South America.

ARTICLE INFO

Article history:

Received: 6 August 2016;

Received in revised form:

6 September 2016;

Accepted: 16 September 2016;

Keywords

Pelvic Malalignments

Manual therapeutic corrections

Trigger point release

Muscle energy techniques

Core muscle strengthening

ABSTRACT

The pelvic or innominate malalignment syndrome is most common in sports injuries and even in every client who presents with low back or pelvis pain and dysfunctions. In my experience, the treatments for the pelvic or innominate malalignments were best, using manual therapy techniques and focused on corrective exercises. The three manual techniques were we used to correct the pelvic malalignments are (i) trigger point release (TrP), (ii) muscle energy techniques (MET), and (iii) the Isolated and/or Core muscles strengthening exercises. The current study focused on the manual therapeutic corrections for the different common innominate malalignment presentations in soccer players.

© 2016 Elixir All rights reserved

Introduction

Pain, discomfort, and disabilities are presents primarily in the low back were the main source of sufferings for a large number of people in the world. It accounts, for each year more than eighty millions of patients seek advice from the physician for the same. Due to its ubiquitous causes, the low back pains are remains remarkably difficult to elucidate and treat. Many people are claimed to understand the core cause of this low back pain, but in the reality, it remains an unknown mystery. All the previous experts are worked on this low back pain says that the low back pain is strictly a mechanical phenomenon due to the fatigue and/or strain of the muscles, tendons and ligaments around the lower back. But, some author claims that the predicament was because of the imbalances in the Psoas major muscle. While some other points that the inter-vertebral discs are the primary culprits for the majority of the low back pain. Another theory attributes that most of the low back pains are merely due to the emotional stress. Each of these explanations may probably correct to some extent, but none of them specifies that why these strains and injuries occur or why they transpire with such frequencies.

Even now we are not confident on which musculoskeletal issues could result in the chronic low back pain issues. Some claim that the chronic muscle strains, lower extremity tendinopathies, periscapular pain, tightness of the paravertebral muscles or tension headaches. I am sure that we can think few of the possibilities, but few can result in all. More often, when a patient reports to our care for the low back pain with one of the aforementioned problems, we immediately take for granted for the nearby particular area or locally. Unfortunately, the real problem may possibly with the rotational innominate stuck or the pelvic upslip, or both. Despite being often overlooked, these malalignments are not

Pelvic malalignments are referred to the incorrect anatomical alignments of the pelvic bones. This is a very common finding in patients present with low back pain nowadays. When the bones in pelvis alignment are not symmetrically balanced, then the entire spine can be affected, resulting in the injuries of the back or lower back. If we imagine that the pelvis as the base, into which the spine is installed, then it is easy to visualize the possible potential for these dysfunctions.

The pelvic malalignment syndrome is the most common in sports injuries and even in every client who presents with low back and pelvis pain or dysfunction. According to Kristine Boyle Walker, palpation and mobility tests have shown poor reliability and validity. But, in our previous study, we used simple bony palpation method to assess the various pelvic malalignments accurately [Ganesh E, et al., 2014; Ganesh E, et al., 2015 and Ganesh E, et al., 2016].

Materials and Methods

Forty football players (n = 40) from National Football Club (NFC), were qualified for support in the study. Subjects were limited to men who had a normal muscle strength and range of Motion (ROM) of the back and lower extremities and who had no history of orthopaedic or neurologic disorders. The mean age of the study population was 22.2 ± 3.9 years, height 175.8 ± 6.6 cms, and weight 87.5 ± 7.1 kgs. All subjects were instructed to restrict excessive physical activity on the day of testing, such as recreational running and bicycling, and to wear gym trunks for the tests. On the day of testing, all subjects reviewed and signed informed consent forms before proceeding for the study. All aspects of Human care compiled with the ethical guidelines and technical requirements were approved by the Institutional Human Ethics Committee (IHEC) and Institutional Review Board (IRB) [Ganesh E, et al., 2014; Ganesh E, et al., 2015 and Ganesh E, et al., 2016].

During the assessment, we demonstrated the subjects to perform the movements to gain access the innominate malalignments. In addition, to justify our diagnosis we accessed the muscles of the functional slings and the muscles around the pelvis related to the malalignments (Abdolhamid D et al, Julie H, Fernando I et al, pelvic evaluation, and stone athletic medicine). The techniques were rehashed for one time each day and proceeded for three to five (depend on the severity of the malalignments) times to standardize.

Common Innominate Malalignments

The assessment of innominate bone was followed by the Bony Pelvis Malalignment Assessment Chart of Ganesh et al., 2014. The common presentation may appear in isolation or in combination with one or both of the others. For example, an 'Upslip' appears on its own in about 10%, in combination with either 'rotational malalignment' or 'flare' or both in another 10%, for a total of 20% overall. In this study, the common 'Innominate malalignment' refers to fixation of an innominate bone relative to the sacrum in excessive anterior or posterior rotation in the sagittal plane [Ganesh E, et al., 2014; Ganesh E, et al., 2015 and Ganesh E, et al., 2016].

Such rotation can affect an innominate on one side only but it was more likely to be seen in association with any of the following [Ganesh E, et al., 2014]:

1. Both the innominate in fixed with Anterior (Anterior tilt), Posterior (Posterior-tilt) and Lateral (Lateral-tilt, without the displacement of the pubic bone superiorly)
2. Compensatory rotation of the contralateral Innominate around the coronal axis in the sagittal plane. (e.g. Right side anterior rotation with Left side Posterior rotation)
3. Compensatory rotation of the contralateral Innominate around the vertical axis in the transverse plane. (e.g. Right side anterior rotation with Out-flare & Left side Posterior rotation with inflare)
4. Upslip of innominate with the displacement of the pubic bone superiorly, relative to each other
5. Upslip with the compensatory rotation of the contralateral innominate around the coronal axis in the sagittal plane. (e.g. Upslip & Right side anterior rotation with Left side Posterior rotation)
6. Upslip with the compensatory rotation of the contralateral innominate around the vertical axis in the transverse plane. (e.g. Upslip & Right side anterior rotation with Out-flare & Left side Posterior rotation with In-flare)

Innominate Malalignment Presentations (Table-1)

[Ganesh E, et al., 2015]:

1. Bilateral Low ASIS & High PSIS, near level Intercristal line & Pubic symphysis.
- “Anterior tilted pelvis”
2. Bilateral Low PSIS & High ASIS, near level Intercristal line & Pubic symphysis.
- “Posterior tilted pelvis”
3. Unilateral high ASIS & PSIS, Ipsilateral high Intercristal line & Neutral / Superior Pubic symphysis.
- “Lateral tilted pelvis”
4. Low ASIS, High PSIS, and near level Intercristal line
- “Anterior rotational stuck”
5. High ASIS, Low PSIS, and near level Intercristal line
- “Posterior rotational stuck”
6. Low & Lateral ASIS, High & Medial PSIS, and near level Intercristal line
- “Anterior rotational stuck with Out-flare”
7. High & Medial ASIS, Low & Lateral PSIS, and near level Intercristal line

“Posterior rotational stuck with In-flare”

8. High ASIS & PSIS, with superior pubic:

“Innominate up-slip stuck with supra-pubic dysfunction”

9. Upslip & level / low ASIS, high PSIS, with Superior pubic.

“Innominate Upslip & Anterior rotational stuck with supra-pubic dysfunction”

10. Upslip & High ASIS, level / low right PSIS, with Superior pubic.

“Innominate Upslip & Posterior rotational stuck with supra-pubic dysfunction”

11. Upslip with level / low & lateral ASIS, high & medial PSIS, with Superior pubic.

“Innominate Upslip & anterior rotational stuck with Out-flare & supra-pubic dysfunction”

12. Upslip with level / low & medial PSIS, high & lateral ASIS, with Superior pubic.

“Innominate Upslip & posterior rotational stuck with In-flare & supra- pubic dysfunction”

Table-1: Innominate malalignment presentations

[Ganesh E, et al., 2015].

S.No.	INNOMINATE BONE			
	ROTATIONAL STUCK		UPSLIP	PUBIS
	Horizontal Axis	Vertical Axis		
1	Anterior Tilt	Out flare	-	-
2	Posterior Tilt	In flare	-	-
3	Lateral Tilt	Maybe Out flare	Maybe present	Maybe Superior
4	Unilateral Anterior Rotation	-	-	-
5	Unilateral Posterior Rotation	-	-	-
6	Unilateral Anterior Rotation	Unilateral Out flare	-	-
7	Unilateral Posterior Rotation	Unilateral In flare	-	-
8	-	-	Unilateral	Ipsilateral Superior
9	Ipsilateral Anterior Rotation	-	Unilateral	Ipsilateral Superior
10	Ipsilateral Posterior Rotation	-	Unilateral	Ipsilateral Superior
11	Ipsilateral Anterior Rotation	Ipsilateral Out flare	Unilateral	Ipsilateral Superior
12	Ipsilateral Posterior Rotation	Ipsilateral In flare	Unilateral	Ipsilateral Superior

Methods of Corrections

In my experience, the treatments for the pelvic malalignments were best, using manual therapy techniques and focused corrective exercises. I've seen many patients with low back pain, who addresses their functional leg length discrepancy by placing a heel lift in their shoe. The heel lifts will do nothing if the discrepancies not in an anatomical leg length. In this case, we must correct the causes for the dysfunction not to treat symptomatically. Sometimes, the non-symptomatic individuals may also be shown to have the pelvic asymmetries [Wilson E, et al., 2003].

When I saw an individual's those who are presenting with rotational in nominate or up slip in nominate or combination of both, I usually perform these three things to correct their pelvic malalignments are (i) trigger point release (TrP), followed by (ii) muscle energy techniques (MET), and followed by an isolated and core (iii) muscles strengthening exercises.

1. Trigger-Point (TrP) Release

Myofascial trigger point release was an ischemic compression technique. In this, the pressure was applied slowly and progressively over the trigger point, as the tension and taut band in the trigger point were slowly subsided. The

ischemic compression pressure was maintained until the tenderness diminishes or the tension released. This was followed by the stretching of the muscle(s). Before the application of ischemic compression pressure, the patient should be informed that some discomfort may occur. The technique of ischemic compression followed by stretching provided the best and most effective drop off in the trigger point's pain levels. Ischemic compression was a gentle and non-invasive way to turn off the active trigger points. I used this principle of ischemic compression pressure to 'reset' the consequences that kept the muscle in spasm.

The important thing to realize here, the trigger points are the part of a protective mechanism of our body. The active trigger points are actually an important defense reflex that keeps our body safe. However, the problems occur when these reflex misfires or doesn't switch off may cause an ongoing pain and stiffness. The key point was that this trigger point release technique was pain-free; if it hurts we are not doing it correctly. This was the only area I know, where the 'no pain, do not gain' fail. In fact, a muscle in pain may tense up, so the causing pain would hinder the techniques to work correctly.

Mechanism

The ischemic compression technique was the application of sustained direct pressure using your digits (usually the thumb) over the trigger pain point. We must ensure to maintain that, the sufficient strength and specific time duration, to slow down the blood flow and relieve tension in the muscle involved [Hou CR, et al., 2002; Gemmel H, et al., 2008]. A proposed mechanism for the benefit of ischemic compression technique that the relief of pain and muscle spasm by using the direct pressure (usually with the thumb), may result in the local reactive hyperemia may produce by the spinal reflex mechanism.

Post-Release Care

The painless trigger point pain release was an implausible therapeutic skill. It not only benefits to the athletes, sports workers, and also to the people who suffer from the chronic mechanical low back pain. Once we reduce the sensitivity of the trigger points through digital ischemic pressure, the treatment isn't quite completed. Next, we need to stretch out the muscle what we released. Stretching must be performed slowly and it must be followed with the breathing out, it helps in reach the complete length of the muscle, also to feel the increase in muscle stretch length. At any stage, we should not try to apply force in the stretch this could turn the trigger point to back on. Stretching was an important part of this process, to prevent the returning or recurring of trigger points soon. After the stretch, the last stage in the process was, to apply a gentle heat. We can use a heat pack, wheat bag or simply a hot water bottle over the performed muscle(s). Apply the heat to the area for at least five to ten minutes.

2. Muscle Energy Technique (MET)

The muscle energy technique (MET) was my second choice of therapeutic skill for those who are presenting with rotational innominate or upslip innominate or combination of both. In this, the patients are voluntary contracts their specific group muscles against the resistance of the therapist [Lenahan KL, et al., 2003]. MET was considered a placid manual therapy technique for the mechanical low back pain and pelvic asymmetry patients and it was an active technique, where the patients, note, not the therapist, controls the counteractive force [Wilson E, et al., 2003]. In this, the patient's voluntary to perform the muscle contractions in varying intensity also in a precise direction. Simultaneously,

the therapist applies a counterforce for not allowing the movement to occur. The hypothesis behind the MET techniques was that it helps in correct an asymmetry by targeting a resisted contraction of the muscles on the painful side of the low back thereby it moves the innominate in a right direction.

Mechanism

The muscle energy technique (MET) was a direct and active technique. In this, the patient involved to voluntary contracts their specific group muscles against the resistive barrier and it also requires the patient's active participation for the maximal effect. During the procedure, the patient's muscle group undergoes an isometric contraction, and the following physiological changes may occur [Wilson E, et al., 2003; Ballantyne et al., 2003].

Type-I: Post Isometric Relaxation (PIR) – In this, the activation of Golgi tendon organ occurs, it may result in the direct inhibition of agonist group muscles (Fig-1A).

Type-II: Reflexive Reciprocal Inhibition (RRI) – Due to the activation of Muscle spindle receptors, would result in the reflexive reciprocal inhibition of the antagonist muscle groups (Fig-1B). When the patient relaxes, the agonist and antagonist muscles remain inhibited and it allows the joint to move further into the restricted range of motion.

Techniques:

To attain the maximum effect on the Muscle energy technique (MET), the therapist must ensure the following eight essential steps [Dowling and Dennis J, 2005].

1. The therapist must be accurate on their assessment of innominate bone, followed the Bony Pelvis Malalignment Assessment Chart of Ganesh et al., 2014.
2. The therapist must apply the counter restrictive barrier in as many planes as possible.
3. The therapist and patient must engage in obdurate counteractive forces for the enhanced results.
4. The therapist must ensure about the patients' isometric contraction, the amount of force applied, the correct direction of effort and, the optimal durations (approx five to ten seconds).
5. The patients must be at utmost relaxation after the each repetition of the muscular effort.
6. The patient was repositioned to apply the counter restrictive barrier in as many planes as possible.
7. Make sure, the Steps three to six, are repeated approximately for three to six times or discontinued until no further improvement in the range of motion was observed.
8. The structural diagnosis was repeated to evaluate the dysfunction has resolved or improved.

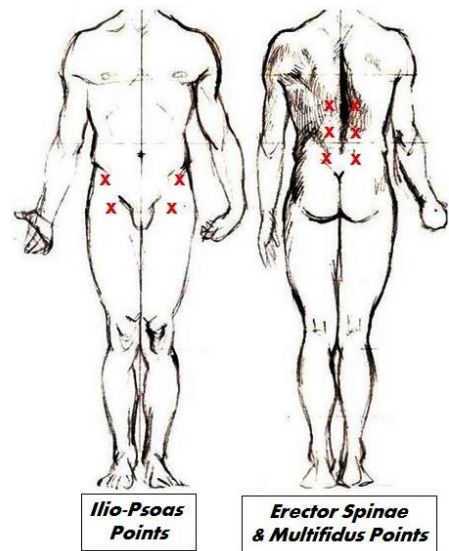
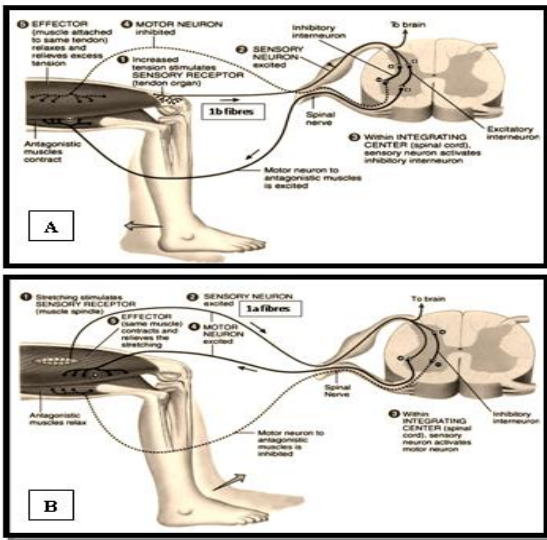


Figure 1: Shows the schematic representation of neural mechanism behind the muscle energy technique. A. Type-I: Post - Isometric Relaxation (PIR). B. Type-II: Reflexive - Reciprocal Inhibition (RRI)

MANUAL THERAPEUTIC CORRECTIONS OF INNOMINATE MALALIGNMENTS:

1. Bilateral Low ASIS & High PSIS, near level Intercristal line & Pubic symphysis.

IMPRESSION: Anterior Tilted Pelvis

SOFT TISSUES IMBALANCES: The antero-posterior stability of the pelvic bones was maintained by the two main factors, anterior longitudinal slings formed by the Rectus Abdominis & Ilio-pectus, and the posterior longitudinal slings are Erectorspinae and Hamstring group muscles. If the patient exhibits, the presentation of “bilateral tightness of Ilio-pectus and Erector spinae muscles” and the counterpart lengthening of “bilateral Rectus Abdominis & Hamstring” muscles, results in the “Anterior tilted” innominate malalignment (Fig-2).

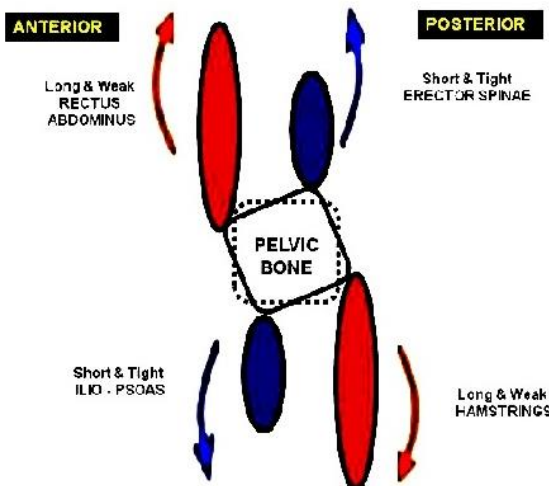


Figure 2: Shows the muscles responsible for “Anterior tilted” pelvic malalignment.

CORRECTIONS

A. Trigger Point Release (TrP) for imbalanced soft tissues: (Fig-3)

Figure 3: Indicates the trigger point's location to the muscles responsible for the “Anterior Tilted Pelvis”.

B. Muscle Energy Technique (MET)

Step-1: The patient was placed in knee flexed prone position and the hip was passively extended to the range where he/she feels the discomfort to the point of tension of the iliopsoas muscle. This was the point of tension or the feather edge barrier range. Simultaneously, the therapist must support the opposite side thigh and pelvic bone in neutral. At this level, with shorter than the feather edge barrier range, the patient was instructed to press his/her knee down against the counterforce created by the therapist.

The technique was initially performed with the knee flexion position (Fig-4) and repeated the same with the straightened knee (to avoid the contraction of rectus femoris), hold it approximately for five to ten seconds, followed to the relaxation for three to five seconds and repeat the same, to the opposite leg (Fig-5).

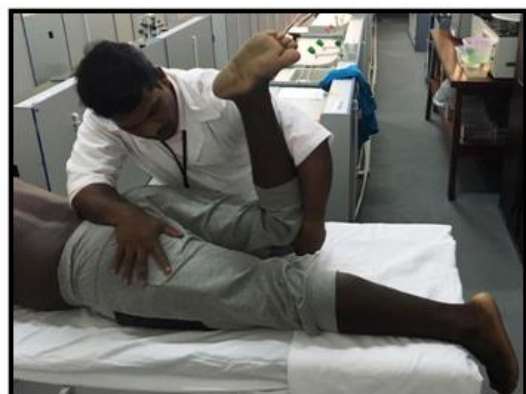

Figure 4: MET technique to correct the right “Ilio-Psoas” muscle

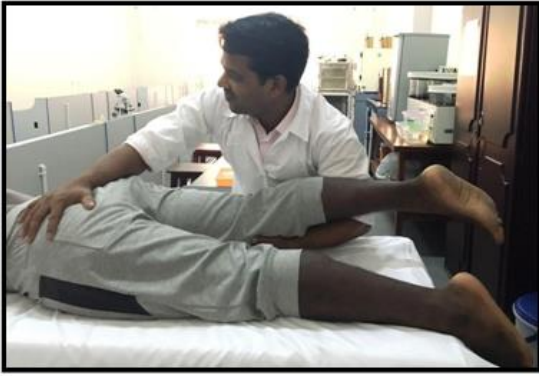

Figure 5: MET technique to correct the right “Rectus femoris” muscle.

Step-2: The patient was placed in knee flexed supine position and the hip was passively flexed and moved towards the chest, until the range where he/she feels the discomfort to the point of tension of the erector spinae muscle. This was the point of tension or the feather edge barrier range. Simultaneously, the therapist must support the opposite side thigh and pelvic bone in neutral, the leg was placed out the treatment table with the hip extended and the knee flexed position. Smaller than the point of tension range, the patient pushes his/her knee towards the front, against the counterforce created by the therapist, and hold it approximately for five to ten seconds, followed to the relaxation for three to five seconds and repeat the same, to another leg (Fig-6).

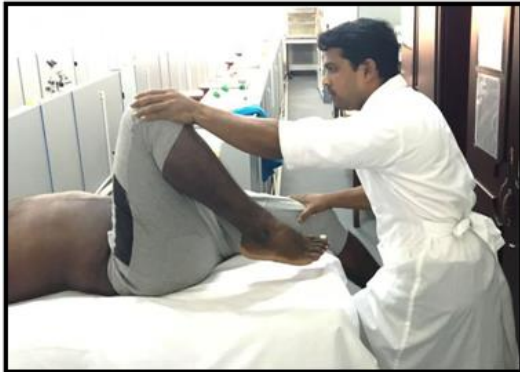

Figure 6: MET technique to correct the right “Erector-spinae” muscle.

The therapist must ensure the followings, the patient's isometric contraction of the iliopsoas on step-1 and erector spinae muscles on step-2, the amount of force applied, the correct direction of effort and, the optimal duration (approx five to ten seconds). The technique was repeated approximately for three to six times or discontinued if the patient experiences any discomfort or the neurological symptoms during the procedure. The structural diagnosis was repeated to evaluate the dysfunction has resolved or improved.

2. Bilateral Low PSIS & High ASIS, near level Intercristal line & Pubic symphysis.

IMPRESSION: Posterior Tilted Pelvi

SOFT TISSUES IMBALANCES: The antero-posterior stability of the pelvic bones was maintained by the two main factors, anterior longitudinal slings formed by the Rectus Abdominis & Ilio-psoas, and the posterior longitudinal slings are Erector spinae and Hamstring group muscles. If the patient exhibits, the presentation of “bilateral tightness of Rectus Abdominis & Hamstring muscles” and the counterpart lengthening of “bilateral Ilio-psoas and Erector spinae

muscles”, results in the “Posterior tilted” innominate malalignment (Fig-7).

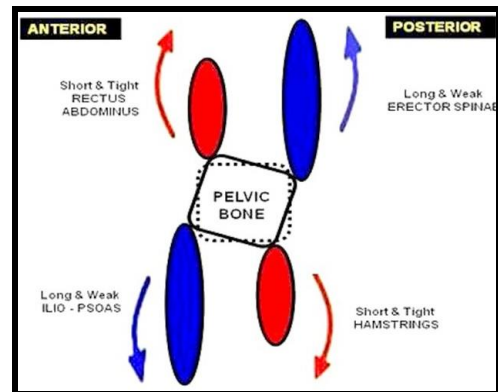


Figure 7: Shows the muscles responsible for the “Posterior Tilted” pelvic malalignment.

CORRECTION

A. Trigger Point Release (TrP) for imbalanced soft tissues: (Fig-8)

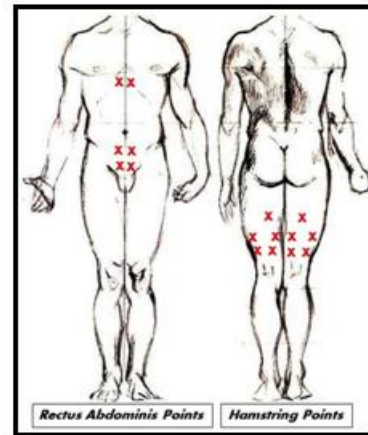


Figure 8: Indicates the trigger point's location to the muscles responsible for the “Posterior Tilted Pelvis”

B. Muscle Energy Technique (MET)

The patient was placed in Thomas tests position and advised to hold the treatment table on sides. The right leg hip and knee were in 90° flexed, the foot was placed against the body of the therapist and the knee was firmly supported. Simultaneously, the left leg which held off from the treatment table, with the knee flexed and the hip-extended position, here the therapist applied the downward thrust over the knee. At this level, therapists passively flexed the right hip and simultaneously extend the left hip to the range where he/she feels the discomfort to the point of tension of the right hamstring and left rectus abdominis muscles. This was the point of tension or the feather edge barrier range. Smaller than the point of tension range, the patient allowed push his/her knees to approximate each other, i.e., the right leg hip undergoes extension and left hip draws towards flexion. The therapists applied the counterforce against this patient's attempt and hold it approximately for five to ten seconds, followed to the relaxation for three to five seconds. The techniques were repeated in both legs alternatively (Fig-9 and 10).

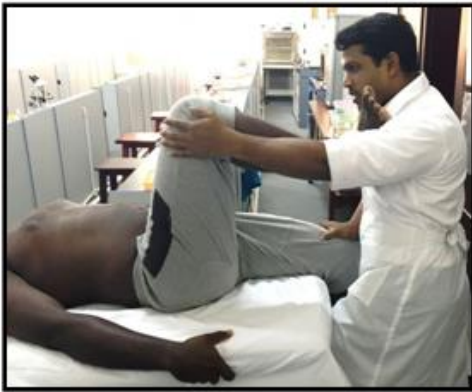

Figure 9: MET technique to correct the right “Hamstring” and left “Ilio-Psoas” muscles.

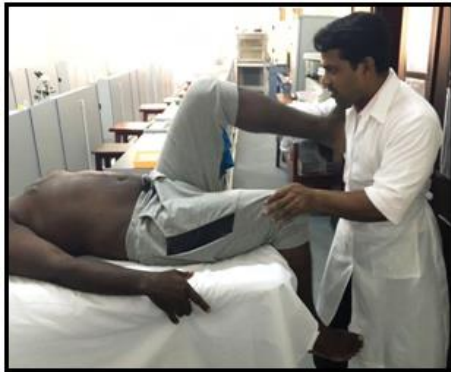

Figure 10: MET technique to correct the left “Hamstring” and right “Ilio-Psoas” muscles.

The therapist must ensure the followings, the patient's isometric contraction of the rectus abdominis and hamstring muscles, the amount of force applied, the correct direction of effort and, the optimal duration (approx five to ten seconds). The technique was repeated approximately for three to six times or discontinued if the patient experiences any discomfort or the neurological symptoms during the procedure. The structural diagnosis was repeated to evaluate the dysfunction has resolved or improved.

3. Unilateral high ASIS & PSIS, Ipsilateral high Intercristal line & Neutral / Superior Pubic

IMPRESSION: Lateral Tilted Pelvis

SOFT TISSUES IMBALANCES: (Example on right tilted pelvis) The lateral stability of the pelvic bones was maintained by the two main factors, Right and Left lateral slings formed by the Quadratus Lumborum above, and the Gluteus muscles below. If the patient exhibits, the presentation of “Ipsilateral Quadratus Lumborum and Contralateral Gluteus muscles tightness” and the counterpart lengthening of “Ipsilateral Gluteus and Contralateral Quadratus Lumborum muscles”, results in the “Lateral tilted” innominate malalignment (Fig-11).

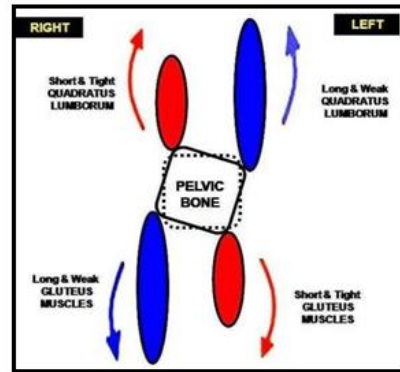


Figure 11: Shows the muscles responsible for the “Lateral Tilted” pelvic malalignment.

CORRECTION:

A. Trigger Point Release (TrP) for imbalanced soft tissues: (Example on right tilted pelvis) (Fig-12)

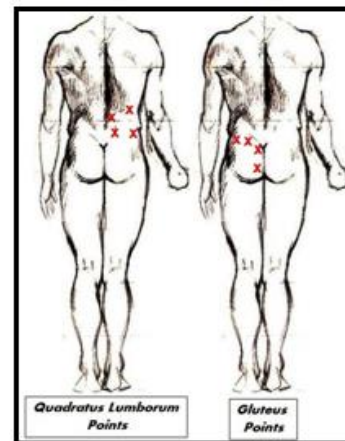


Figure 12: Indicates the trigger point's location to the muscles responsible for the “Lateral Tilted Pelvis”

B. Muscle Energy Technique (MET): (Example on right tilted pelvis)

Step-1: The patient was in left lateral recumbent position and the left leg was maintained in fully flexed position, close to the patient's chest wall and fixed by the left hand of the patient. The patient's right hand was allowed to hold the treatment table in over head position and it helps in support the body during the maneuver. Later to this, the therapist moved the patient's fully extended right leg, off and away from the treatment table. At this point, the patient was advised to press the right leg down, until the range where he/she feels the discomfort to the point of tension of the right Quadratus Lumborum. This was the point of tension or the feather edge barrier range. Smaller than the point of tension range, the patient was advised to lift his/her right leg against the therapist counterforce and hold it approximately for five to ten seconds, followed to the relaxation for three to five seconds. The techniques were repeated three to six times in the lower pain-free length ranges (Fig-13 and 14).

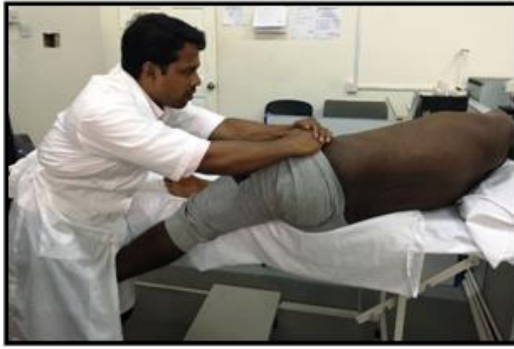

Figure 13: (Left lateral view) MET technique to correct the left "Quadratus Lumborum" muscle.

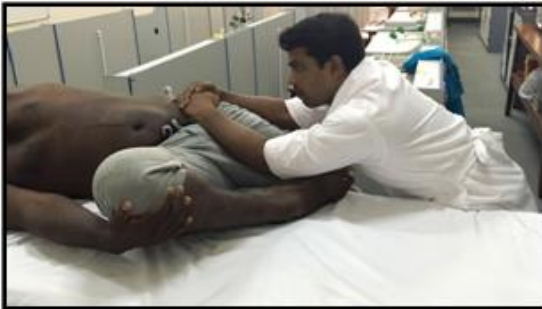

Figure 14: (Right lateral view) MET technique to correct the left "Quadratus Lumborum" muscle.

Step-2: The patient was placed in supine position with the right leg hip and the knee was in flexed, further the right hip was passively flexed towards the chest, until the range where he/she feels the discomfort to the point of tension in the Gluteus muscle. This was the point of tension or the feather edge barrier range. Simultaneously, the therapist must support the opposite side thigh and pelvic bone in neutral, the left leg was placed out the treatment table with the hip extended and the knee flexed position. At the point of tension or the feather edge barriers range or shorter than the point of tension range, the patient was allowed to extend his/her right hip against the counter force created by the therapist. The technique was initially performed with the knee flexion position and repeated the same with the straightened knee (to localize the contraction in Gluteus muscle), hold it approximately for five to ten seconds, followed to the relaxation for three to five seconds.

The therapist must ensure the followings, the patient's isometric contraction of the Quadratus Lumborum on step-1 and Gluteus muscles on step-2, the amount of force applied, the correct direction of effort and, the optimal duration (approx five to ten seconds). The technique was repeated approximately for three to six times or discontinued if the patient experiences any discomfort or the neurological symptoms during the procedure. The structural diagnosis was repeated to evaluate the dysfunction has resolved or improved.

4. Unilateral Low ASIS, High PSIS, and near level Intercristal line

IMPRESSION: Anterior rotational stuck of innominate bone
SOFT TISSUES IMBALANCES : (Example on right innominate) The antero-posterior stability of the pelvic bones was maintained by the two main factors, anterior longitudinal slings formed by the Rectus Abdominis & Ilio-psoas, and the posterior longitudinal slings are Erector spinae & Hamstring group muscles. If the patient exhibits, the presentation of "right side tightness of Ilio-psoas and Erector spinae muscles" and the counterpart lengthening of "Ipsilateral Rectus

Abdominis & Hamstring" muscles, results in the 'Anterior rotational stuck" of the innominate malalignment (Fig-15).

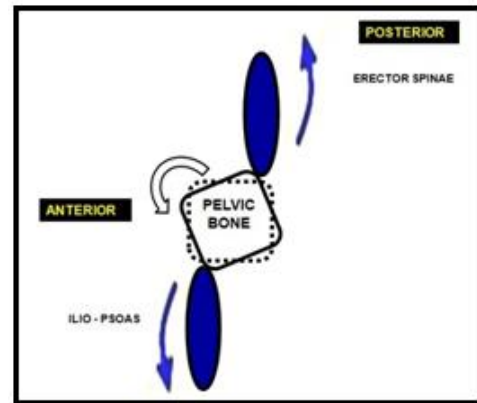


Figure 15: Shows the muscles responsible for the "Anterior rotational stuck of innominate bone"

CORRECTION:

A. Trigger Point Release (TrP) for imbalanced soft tissues: (Example on right innominate) (Fig-16)

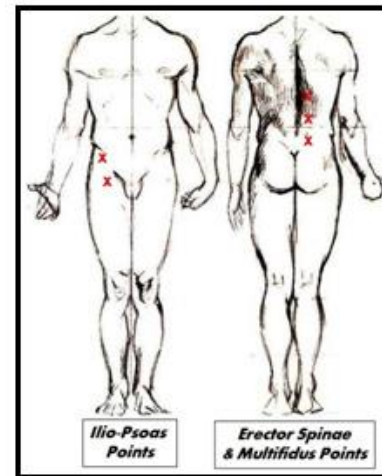


Figure 16: Indicates the trigger point's location to the muscles responsible for the "Anterior rotational stuck of innominate bone"

B. Muscle Energy Technique (MET): (Example on right innominate)

Step-1: The patient was placed in right knee flexed prone position and the hip was passively extended to the range where he/she feels the discomfort to the point of tension of the iliopsoas muscle. This was the point of tension or the feather edge barrier range. Simultaneously, the therapist must support the opposite side leg in extended position, the thigh and pelvic bone in neutral. At this level, with shorter than the feather edge barrier range, the patient was instructed to press his/her knee down against the counterforce created by the therapist. The technique was initially performed with the knee flexion position and repeated the same with the straightened knee (to avoid the contraction of rectus femoris), hold it approximately for five to ten seconds, followed to the relaxation for three to five seconds (Fig-4 & 5).

Step-2: The patient was placed in right knee flexed supine position and the hip was passively flexed and moved towards the chest, until the range where he/she feels the discomfort to the point of tension of the erector spinae muscle. This was the

point of tension or the feather edge barrier range. Simultaneously, the therapist must support the opposite side thigh and pelvic bone in neutral, the leg was placed out the treatment table with the hip extended and the knee flexed position. Smaller than the point of tension range, the patient pushes his/her knee towards the front, against the counterforce created by the therapist, and hold it approximately for five to ten seconds, followed to the relaxation for three to five seconds (Fig-6).

The therapist must ensure the followings, the patient's isometric contraction of the iliopsoas on step-1 and erector spinae muscles on step-2, the amount of force applied, the correct direction of effort and, the optimal duration (approx five to ten seconds). The technique was repeated approximately for three to six times or discontinued if the patient experiences any discomfort or the neurological symptoms during the procedure. The structural diagnosis was repeated to evaluate the dysfunction has resolved or improved.

5. Unilateral High ASIS, Low PSIS, and near level Intercristal line

IMPRESSION: Posterior rotational stuck of innominate bone
SOFT TISSUES IMBALANCES: (Example on right innominate) The antero-posterior stability of the pelvic bones was maintained by the two main factors, anterior longitudinal slings formed by the Rectus Abdominis & Ilio-psoas, and the posterior longitudinal slings are Erector spinae & Hamstring group muscles. If the patient exhibits, the presentation of "right side tightness of Rectus Abdominis & Hamstring muscles" and the counterpart lengthening of "Ipsilateral Ilio-psoas and Erector spinae" muscles, results in the "Posterior rotational stuck" of the innominate malalignment (Fig-17).

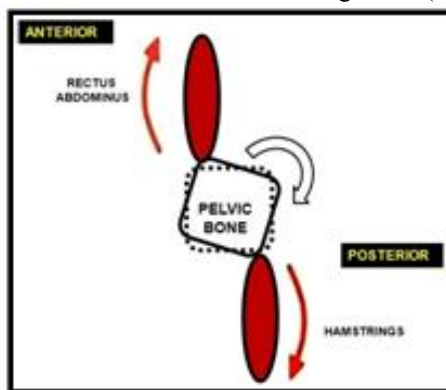


Figure 17: Shows the muscles responsible for the "Posterior rotational stuck of innominate bone"

CORRECTION:

A. Trigger Point Release (TrP) for imbalanced soft tissues: (Example on right innominate) (Fig-18)

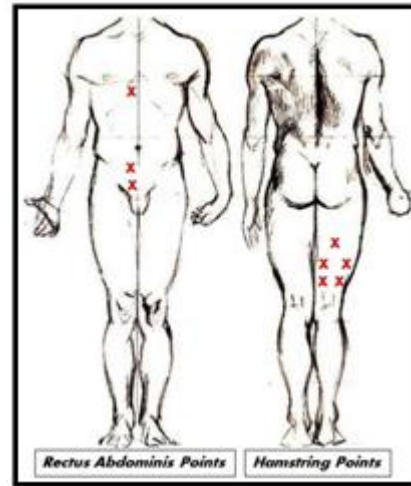


Figure 18: Indicates the trigger point's location to the muscles responsible for the "Posterior rotational stuck of innominate bone"

B. Muscle Energy Technique (MET): (Example on right innominate)

The patient was placed in Thomas tests position and advised to hold the treatment table on sides. The right leg hip and knee were in 90° flexed, the foot was placed against the body of the therapist and the knee was firmly supported. Simultaneously, the left leg which held off from the treatment table, with the knee flexed and the hip-extended position, here the therapist applied the downward thrust over the knee. At this level, therapists passively flexed the right hip and simultaneously extend the left hip to the range where he/she feels the discomfort to the point of tension of the right hamstring and left rectus abdominis muscles. This was the point of tension or the feather edge barrier range. Smaller than the point of tension range, the patient was allowed push his/her knees to approximate each other, i.e., the right leg hip undergoes extension and left hip draws towards flexion. The therapists applied the counterforce against this patient's attempt and hold it approximately for five to ten seconds, followed to the relaxation for three to five seconds. The techniques were repeated in both legs alternatively (Fig-9 & 10).

The therapist must ensure the followings, the patient's isometric contraction of the rectus abdominis and hamstring muscles, the amount of force applied, the correct direction of effort and, the optimal duration (approx five to ten seconds). The technique was repeated approximately for three to six times or discontinued if the patient experiences any discomfort or the neurological symptoms during the procedure. The structural diagnosis was repeated to evaluate the dysfunction has resolved or improved.

6. Low & Lateral ASIS, High & Medial PSIS and near level Intercristal line

IMPRESSION: Anterior rotation with Out-flare innominate stuck

SOFT TISSUES IMBALANCES: (Example on right innominate) The antero-posterior stability of the pelvic bones was maintained by the two main factors, anterior longitudinal slings formed by the Rectus Abdominis & Ilio-psoas, and the posterior longitudinal slings are Erector spinae & Hamstring group muscles. If the patient exhibits, the presentation of "right side tightness of Ilio-psoas and Erector spinae muscles" and the counterpart lengthening of "Ipsilateral Rectus

Abdominis & Hamstring” muscles, results in the Anterior rotational stuck of the innominate bone.

The internal-external stability of the pelvic bones was maintained by the two other factors, internally by the internal rotators of the hip called, the Tensor fascia latae, the Gluteus medius, and the Gluteus minimus muscles. The external stability was maintained by the internal rotators of the hip called, the piriformis, the triple tendon (superior gemelli – Obturator internus – Inferior gemelli) and the quadratus femoris muscles. If the patient exhibits, the presentation of Anterior rotational stuck of the innominate bone with the “tightness of the Tensor fascia latae, Gluteus medius and Gluteus minimus muscles” and the weak counterpart of “piriformis, the triple tendon (superior gemelli – Obturator internus – Inferior gemelli) and the quadratus femoris muscles”, results in the “Anterior rotation with Out-flare stuck” of the innominate malalignments (Fig-19).

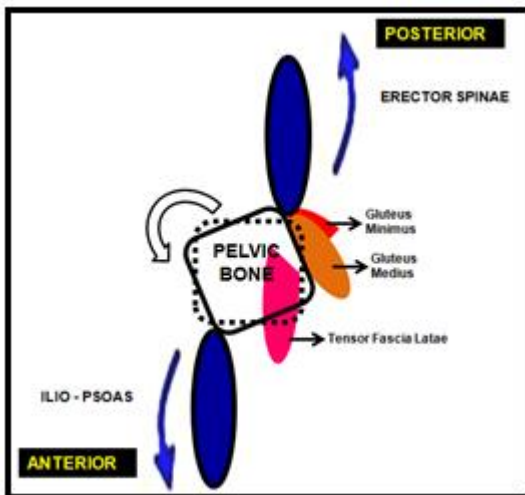


Figure 19: Shows the muscles responsible for the “Anterior rotational with Out-flare stuck of innominate bone”

CORRECTION:

A. Trigger Point Release (TrP) for imbalanced soft tissues: (Example on right innominate) (Fig-20)

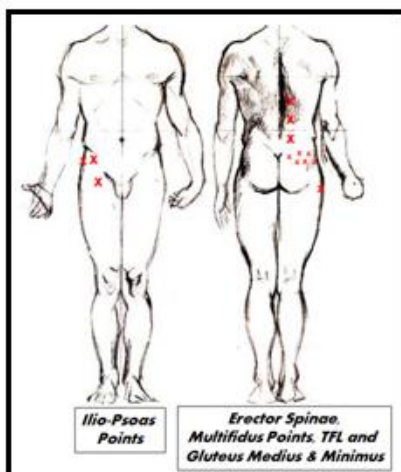


Figure 20: Indicates the trigger point’s location to the muscles responsible for the “Anterior rotational with Out-flare stuck of innominate bone”

B. Muscle Energy Technique (MET): (Example on right innominate)

Step-1: The patient was placed in right knee flexed prone position and the hip was passively extended to the range where he/she feels the discomfort to the point of tension of the

iliopsoas muscle. This was the point of tension or the feather edge barrier range. Simultaneously, the therapist must support the opposite side leg in extended position, the thigh and pelvic bone in neutral. At this level, with shorter than the feather edge barrier range, the patient was instructed to press the knee down against the counterforce created by the therapist. The technique was initially performed with the knee flexion position and repeated the same with the straightened knee (to avoid the contraction of rectus femoris), hold it approximately for five to ten seconds, followed to the relaxation for three to five seconds (Fig-4 & 5).

Step-2: The patient was placed in right knee flexed supine position and the hip was passively flexed and moved towards the chest, until the range where he/she feels the discomfort to the point of tension of the erector spinae muscle. This was the point of tension or the feather edge barrier range. Simultaneously, the therapist must support the opposite side thigh and pelvic bone in neutral, the leg was placed out the treatment table with the hip extended and the knee flexed position. Smaller than the point of tension range, the patient pushes his/her knee towards the front, against the counterforce created by the therapist, and hold it approximately for five to ten seconds, followed to the relaxation for three to five seconds (Fig-6).

Step-3: The patient was placed in right hip and knee 90° flexed supine position, the therapist was passively rotated his/her right hip externally, until the range where he/she feels the discomfort to the point of tension of the internal rotators of the hip. Simultaneously, the therapist must support the opposite side thigh and pelvic bone in neutral, the leg was placed out the treatment table with the hip extended and the knee flexed position. Smaller than the point of tension range, the patient was advised to move his/her right hip rotate internally, against the counterforce created by the therapist, and hold it approximately for five to ten seconds, followed to the relaxation for three to five seconds.

The therapist must ensure the followings, the patient's isometric contraction of the iliopsoas on step-1, erector spinae muscles on step-2 and internal rotators of the hip during the step-3, the amount of force applied, the correct direction of effort and, the optimal duration (approx five to ten seconds). The technique was repeated approximately for three to six times or discontinued if the patient experiences any discomfort or the neurological symptoms during the procedure. The structural diagnosis was repeated to evaluate the dysfunction has resolved or improved.

7. High & Medial ASIS, Low & Lateral PSIS, and near level Intercristal line

IMPRESSION: Posterior rotation with In-flare innominate stuck

SOFT TISSUES IMBALANCES:(Example on right innominate)The antero-posterior stability of the pelvic bones was maintained by the two main factors, anterior longitudinal slings formed by the Rectus Abdominis & Ilio-psoas, and the posterior longitudinal slings are Erector spinae & Hamstring group muscles. If the patient exhibits, the presentation of “right side tightness of Rectus Abdominis & Hamstring muscles” and the counterpart lengthening of “Ipsilateral Ilio-psoas and Erector spinae” muscles, results in the Posterior rotational stuck of the innominate bone.

The internal-external stability of the pelvic bones was maintained by the two other factors, internally by the internal rotators of the hip called, the Tensor fascia latae, the Gluteus medius, and the Gluteus minimus muscles. The external

stability was maintained by the internal rotators of the hip called, the piriformis, the triple tendon (superior gemelli – Obturator internus – Inferior gemelli) and the quadratus femoris muscles. If the patient exhibits, the presentation of Posterior rotational stuck of the innominate bone with the “tightness of the piriformis, the triple tendon (superior gemelli – Obturator internus – Inferior gemelli) and the quadratus femoris muscles” and the weak counterpart of “Tensor fascia latae, Gluteus medius, and Gluteus minimus muscles”, results in the “Posterior rotation with In-flare innominate stuck” innominate malalignments (Fig-21).

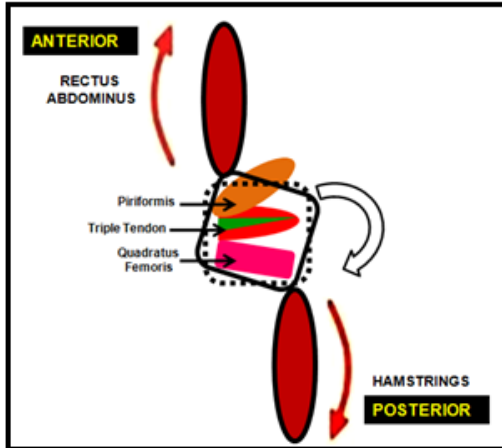


Figure 21: Shows the muscles responsible for the “Posterior rotational with In-flare stuck of innominate bone”

CORRECTION:
A. Trigger Point Release (TrP) for imbalanced soft tissues: (Example on right innominate) (Fig-22)

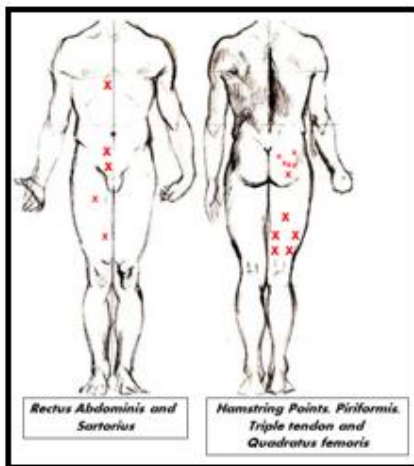


Figure 22: Indicates the trigger point's location to the muscles responsible for the “Posterior rotational with In-flare stuck of innominate bone”

B. Muscle Energy Technique (MET)

Step-1and 2: The patient was placed in Thomas tests position and advised to hold the treatment table on sides. The right leg hip and knee were in 90° flexed, the foot was placed against the body of the therapist and the knee was firmly supported. Simultaneously, the left leg which held off from the treatment table, with the knee flexed and the hip-extended position, here the therapist applied the downward thrust over the knee. At this level, therapists passively flexed the right hip and simultaneously extend the left hip to the range where he/she feels the discomfort to the point of tension of the right hamstring and left rectus abdominis muscles. This was the

point of tension or the feather edge barrier range. Smaller than the point of tension range, the patient was allowed push his/her knees to approximate each other, i.e., the right leg hip undergoes extension and left hip draws towards flexion. The therapists applied the counterforce against this patient's attempt and hold it approximately for five to ten seconds, followed to the relaxation for three to five seconds. The techniques were repeated in both legs alternatively (Fig- 9 & 10).

Step-3: The patient was placed in right hip and knee 90° flexed supine position, the therapist was passively rotated his/her right hip internally, until the range where he/she feels the discomfort to the point of tension of the external rotators of the hip. Simultaneously, the therapist must support the opposite side thigh and pelvic bone in neutral, the leg was placed out the treatment table with the hip extended and the knee flexed position. Smaller than the point of tension range, the patient was advised to move his/her right hip rotate externally, against the counterforce created by the therapist, and hold it approximately for five to ten seconds, followed to the relaxation for three to five seconds.

The therapist must ensure the followings, the patient's isometric contraction of the rectus abdominis and hamstring muscles on step-1& 2 and the external rotators of the hip on step-3, the amount of force applied, the correct direction of effort and, the optimal duration (approx five to ten seconds). The technique was repeated approximately for three to six times or discontinued if the patient experiences any discomfort or the neurological symptoms during the procedure. The structural diagnosis was repeated to evaluate the dysfunction has resolved or improved.

8. High ASIS & PSIS, with superior pubic:

IMPRESSION: Innominate up-slip stuck with supra-pubic dysfunction

SOFT TISSUES IMBALANCES: (Example on right innominate): The lateral stability of the pelvic bones was maintained by the two main factors, Right and Left lateral slings formed by the Quadratus Lumborum above, and the Gluteus muscles below. If the patient exhibits, the presentation of “Ipsilateral Quadratus Lumborum tightness and Gluteus muscles weakness”, results in the up-slip innominate stuck. Normally, the up-slip innominate stuck usually associated with the ipsilateral supra-pubic dysfunctions innominate malalignments (Fig-23).

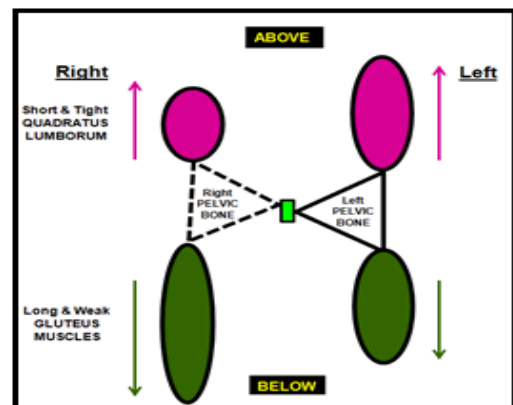


Figure 23: Shows the muscles responsible for the “Innominate up-slip stuck with supra-pubic dysfunction”

CORRECTION:

A. Trigger Point Release (TrP) for imbalanced soft tissues: (Example on right innominate) (Fig-24)

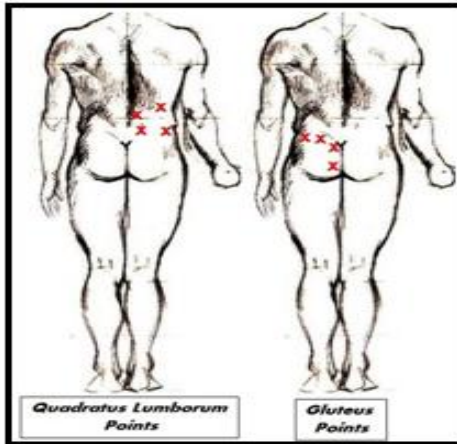


Figure 24: Indicates the trigger point's location to the muscles responsible for the "Innominate up-slip stuck with supra-pubic dysfunction"

B. Muscle Energy Technique (MET)

Step-1: The patient was in left lateral recumbent position and the left leg was maintained in fully flexed position, close to the patient's chest wall and fixed by the left hand of the patient. The patient's right hand was allowed to hold the treatment table in over head position and it helps in support the body during the maneuver. Later to this, the therapist moved the patient's fully extended right leg, off and away from the treatment table. At this point, the patient was advised to press the right leg down, until the range where he/she feels the discomfort to the point of tension of the right Quadratus Lumborum. This was the point of tension or the feather edge barrier range. Smaller than the point of tension range, the patient was advised to lift his/her right leg against the therapist counterforce and hold it approximately for five to ten seconds, followed to the relaxation for three to five seconds. The techniques were repeated three to six times in the lower pain-free length ranges (Fig-13 & 14).

Step-2: The patient was in hip and knee 45° flexed supine position, the feet are fixed apart in the line of hip and the patient was allowed to abduct his/her both the hips as much as possible to the range where he/she feels the discomfort to the point of tension of the adductor muscles of the hip. This was the point of tension or the feather edge barrier range. Smaller than the point of tension range, the patient was advised to adduct the both hips against the therapist counter force applied by the therapist, and hold it approximately for five to ten seconds, followed to the relaxation for three to five seconds (Fig-25).

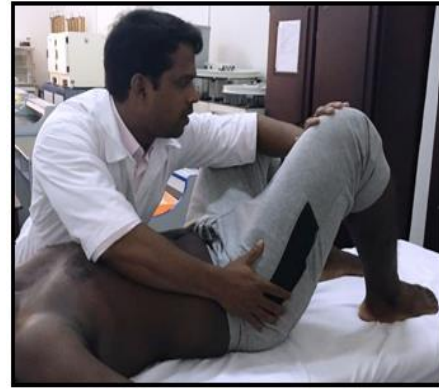

Figure 25: MET technique to correct the Supra-pubic dysfunction by releasing the "Adductor" muscles.

The therapist must ensure the followings, the patient's isometric contraction of the Quadratus Lumborum on step-1 and Adductors of the hip on step-2, the amount of force applied, the correct direction of effort and, the optimal duration (approx five to ten seconds). The technique was repeated approximately for three to six times or discontinued if the patient experiences any discomfort or the neurological symptoms during the procedure. The structural diagnosis was repeated to evaluate the dysfunction has resolved or improved.

9. Upslip & level / low ASIS, high PSIS, with Superior pubic.

IMPRESSION: Innominate Upslip & Anterior rotational stuck with supra-pubic dysfunction

SOFT TISSUES IMBALANCES: (Example on right innominate): The lateral stability of the pelvic bones was maintained by the two main factors, Right and Left lateral slings formed by the Quadratus Lumborum above, and the Gluteus muscles below. If the patient exhibits, the presentation of "Ipsilateral Quadratus Lumborum tightness and Gluteus muscles weakness", results in the up-slip innominate stuck. Normally, the up-slip innominate stuck usually associated with the ipsilateral supra-pubic dysfunctions.

The antero-posterior stability of the pelvic bones was maintained by the two main factors, anterior longitudinal slings formed by the Rectus Abdominis & Ilio-psoas, and the posterior longitudinal slings are Erector spinae & Hamstring group muscles. If the patient demonstrates the innominate up-slip stuck and supra-pubic dysfunctions with, the presentation of "ipsilateral tightness of Ilio-psoas and Erector spinae muscles", results in the "Innominate Upslip & Anterior rotational stuck with supra-pubic dysfunction" innominate malalignments (Fig-26)

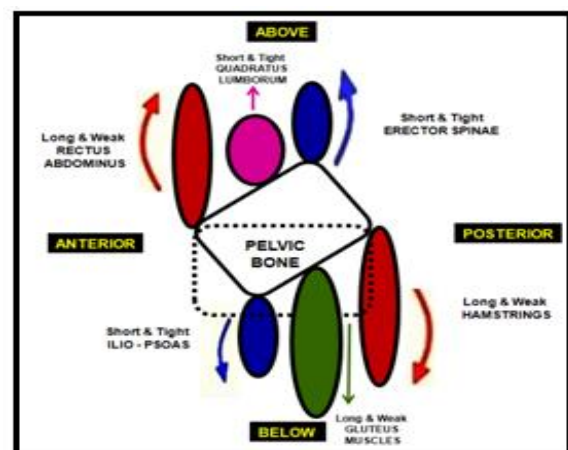


Figure 26: Shows the muscles responsible for the “Innominate Upslip & Anterior rotational stuck with supra-pubic dysfunction”

CORRECTION:

A. Trigger Point Release (TrP) for imbalanced soft tissues: (Example on right innominate) (Fig-27)

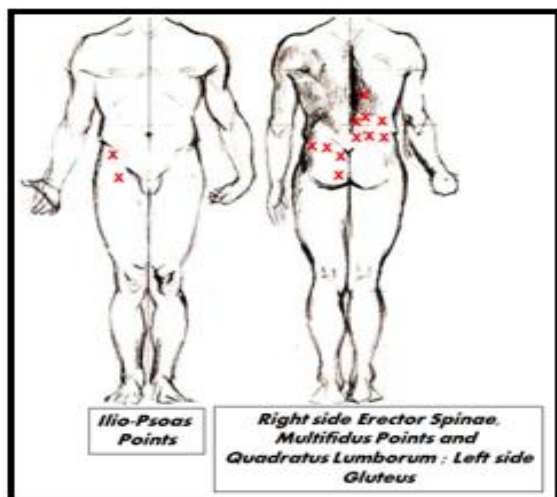


Figure 27: Indicates the trigger point's location to the muscles responsible for the “Innominate Upslip & Anterior rotational stuck with supra-pubic dysfunction”

B. Muscle Energy Technique (MET)

Step-1: The patient was in left lateral recumbent position and the left leg was maintained in fully flexed position, close to the patient's chest wall and fixed by the left hand of the patient. The patient's right hand was allowed to hold the treatment table in over head position and it helps in support the body during the maneuver. Later to this, the therapist moved the patient's fully extended right leg, off and away from the treatment table. At this point, the patient was advised to press the right leg down, until the range where he/she feels the discomfort to the point of tension of the right Quadratus Lumborum. This was the point of tension or the feather edge barrier range. Smaller than the point of tension range, the patient was advised to lift his/her right leg against the therapist counterforce and hold it approximately for five to ten seconds, followed to the relaxation for three to five seconds. The techniques were repeated three to six times in the lower pain-free length ranges (Fig-13 & 14).

Step-2: The patient was placed in right knee flexed prone position and the hip was passively extended to the range where he/she feels the discomfort to the point of tension of the iliopsoas muscle. This was the point of tension or the feather edge barrier range. Simultaneously, the therapist must support the opposite side leg in extended position, the thigh and pelvic bone in neutral. At this level, with shorter than the feather edge barrier range, the patient was instructed to press his/her knee down against the counterforce created by the therapist. The technique was initially performed with the knee flexion position and repeated the same with the straightened knee (to avoid the contraction of rectus femoris), hold it approximately for five to ten seconds, followed to the relaxation for three to five seconds (Fig-4 & 5).

Step-3: The patient was placed in right knee flexed supine position and the hip was passively flexed and moved towards the chest, until the range where he/she feels the discomfort to

the point of tension of the erector spinae muscle. This was the point of tension or the feather edge barrier range. Simultaneously, the therapist must support the opposite side thigh and pelvic bone in neutral, the leg was placed out the treatment table with the hip extended and the knee flexed position. Smaller than the point of tension range, the patient pushes his/her knee towards the front, against the counterforce created by the therapist, and hold it approximately for five to ten seconds, followed to the relaxation for three to five seconds (Fig-6).

Step-4: The patient was in hip and knee 45° flexed supine position, the feet are fixed apart in the line of hip and the patient was allowed to abduct his/her both the hips as much as possible to the range where he/she feels the discomfort to the point of tension of the adductor muscles of the hip. This was the point of tension or the feather edge barrier range. Smaller than the point of tension range, the patient was advised to adduct the both hips against the therapist counter force applied by the therapist, and hold it approximately for five to ten seconds, followed to the relaxation for three to five seconds (Fig-25).

The therapist must ensure the followings, the patient's isometric contraction of the Quadratus Lumborum on step-1, the iliopsoas on step-2, the erector spinae muscles on step-3 and the adductors of the hip on step-4, the amount of force applied, the correct direction of effort and, the optimal duration (approx five to ten seconds). The technique was repeated approximately for three to six times or discontinued if the patient experiences any discomfort or the neurological symptoms during the procedure. The structural diagnosis was repeated to evaluate the dysfunction has resolved or improved.

10. Upslip & High ASIS, level / low right PSIS, with Superior pubic.

IMPRESSION: Innominate Upslip & Posterior rotational stuck with supra-pubic dysfunction

SOFT TISSUES IMBALANCES: (Example on right innominate): The lateral stability of the pelvic bones was maintained by the two main factors, Right and Left lateral slings formed by the Quadratus Lumborum above, and the Gluteus muscles below. If the patient exhibits, the presentation of “Ipsilateral Quadratus Lumborum tightness and Gluteus muscles weakness”, results in the up-slip innominate stuck. Normally, the up-slip innominate stuck usually associated with the ipsilateral supra-pubic dysfunctions.

The antero-posterior stability of the pelvic bones was maintained by the two main factors, anterior longitudinal slings formed by the Rectus Abdominis & Ilio-psoas, and the posterior longitudinal slings are Erector spinae & Hamstring group muscles. If the patient demonstrates the innominate up-slip stuck and supra-pubic dysfunctions with, the presentation of “ipsilateral tightness of Rectus Abdominis & Hamstring muscles”, results in the “Innominate Upslip & Posterior rotational stuck with supra-pubic dysfunction” innominate malalignments (Fig-28).

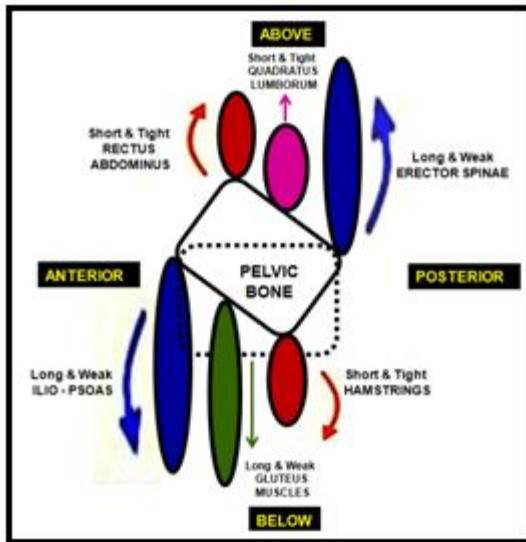


Figure 28: Shows the muscles responsible for the “Innominate Upslip & Posterior rotational stuck with supra-pubic dysfunction”

CORRECTION:

A. Trigger Point Release (TrP) for imbalanced soft tissues: (Example on right innominate) (Fig-29)

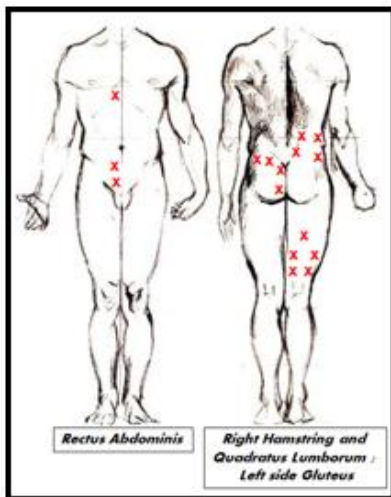


Figure 29. Indicates the trigger point's location to the muscles responsible for the “Innominate Upslip & Posterior rotational stuck with supra-pubic dysfunction”

B. Muscle Energy Technique (MET): (Example on right innominate)

Step-1: The patient was in left lateral recumbent position and the left leg was maintained in fully flexed position, close to the patient's chest wall and fixed by the left hand of the patient. The patient's right hand was allowed to hold the treatment table in over head position and it helps in support the body during the maneuver. Later to this, the therapist moved the patient's fully extended right leg, off and away from the treatment table. At this point, the patient was advised to press the right leg down, until the range where he/she feels the discomfort to the point of tension of the right Quadratus Lumborum. This was the point of tension or the feather edge barrier range. Smaller than the point of tension range, the patient was advised to lift his/her right leg against the therapist counterforce and hold it approximately for five to ten seconds, followed to the relaxation for three to five seconds.

The techniques were repeated three to six times in the lower pain-free length ranges (Fig-13 & 14).

Step-2 & 3: The patient was placed in Thomas tests position and advised to hold the treatment table on sides. The right leg hip and knee were in 90° flexed, the foot was placed against the body of the therapist and the knee was firmly supported. Simultaneously, the left leg which held off from the treatment table, with the knee flexed and the hip-extended position, here the therapist applied the downward thrust over the knee. At this level, therapists passively flexed the right hip and simultaneously extend the left hip to the range where he/she feels the discomfort to the point of tension of the right hamstring and left rectus abdominis muscles. This was the point of tension or the feather edge barrier range. Smaller than the point of tension range, the patient allowed push his/her knees to approximate each other, i.e., the right leg hip undergoes extension and left hip draws towards flexion. The therapists applied the counterforce against this patient's attempt and hold it approximately for five to ten seconds, followed to the relaxation for three to five seconds. The techniques were repeated in both legs alternatively (Fig-9 & 10).

Step-4: The patient was in hip and knee 45° flexed supine position, the feet are fixed apart in the line of hip and the patient was allowed to abduct his/her both the hips as much as possible to the range where he/she feels the discomfort to the point of tension of the adductor muscles of the hip. This was the point of tension or the feather edge barrier range. Smaller than the point of tension range, the patient was advised to adduct the both hips against the therapist counter force applied by the therapist, and hold it approximately for five to ten seconds, followed to the relaxation for three to five seconds (Fig-25).

The therapist must ensure the followings, the patient's isometric contraction of the Quadratus Lumborum on step-1, the rectus abdominis and the hamstring muscles on step-2 & 3 and the adductors of the hip on step-4, the amount of force applied, the correct direction of effort and, the optimal duration (approx five to ten seconds). The technique was repeated approximately for three to six times or discontinued if the patient experiences any discomfort or the neurological symptoms during the procedure. The structural diagnosis was repeated to evaluate the dysfunction has resolved or improved.

11. Upslip with level / low & lateral ASIS, high & medial PSIS, with Superior pubic.

IMPRESSION: Innominate Upslip & anterior rotational stuck with Out-flare & supra-pubic dysfunction

SOFT TISSUES IMBALANCES: (Example on right innominate): The lateral stability of the pelvic bones was maintained by the two main factors, Right and Left lateral slings formed by the Quadratus Lumborum above, and the Gluteus muscles below. If the patient exhibits, the presentation of “Ipsilateral Quadratus Lumborum tightness and Gluteus muscles weakness”, results in the up-slip innominate stuck. Normally, the up-slip innominate stuck usually associated with the ipsilateral supra-pubic dysfunctions. The antero-posterior stability of the pelvic bones was maintained by the two main factors, anterior longitudinal slings formed by the Rectus Abdominis & Ilio-psoas, and the posterior longitudinal slings are Erector spinae & Hamstring group muscles. The internal-external stability of the pelvic bones was maintained by the two other factors, internally by the internal rotators of the hip called, the Tensor fascia latae, the Gluteus medius, and the Gluteus minimus muscles. The external stability was

maintained by the internal rotators of the hip called, the piriformis, the triple tendon (superior gemelli – Obturator internus – Inferior gemelli) and the quadratus femoris muscles.

If the patient demonstrates the innominate up-slip stuck and supra-pubic dysfunctions with, the presentation of “ipsilateral tightness of Ilio-psoas and Erector spinae muscles”, along with the “tightness of the Tensor fascia latae, Gluteus medius and Gluteus minimus muscles” and the weak counterpart of “piriformis, the triple tendon (superior gemelli – Obturator internus – Inferior gemelli) and the quadratus femoris muscles”, results in the “Innominate Upslip & anterior rotational stuck with Out-flare & supra-pubic dysfunction ” innominate malalignments (Fig-30).

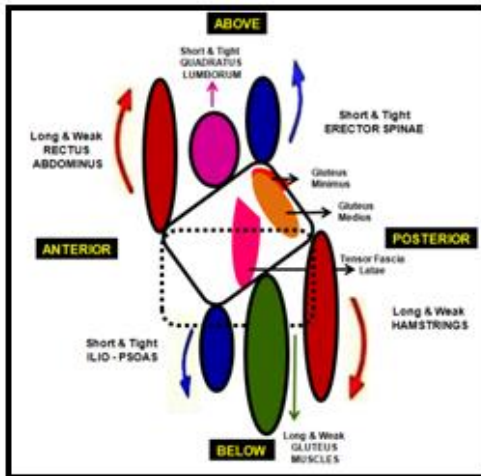


Figure 30: Shows the muscles responsible for the “Innominate Upslip & Anterior rotational stuck with Out-flare & supra-pubic dysfunction”

CORRECTION:

A. Trigger Point Release (TrP) for imbalanced soft tissues: (Example on right innominate) (Fig-31)

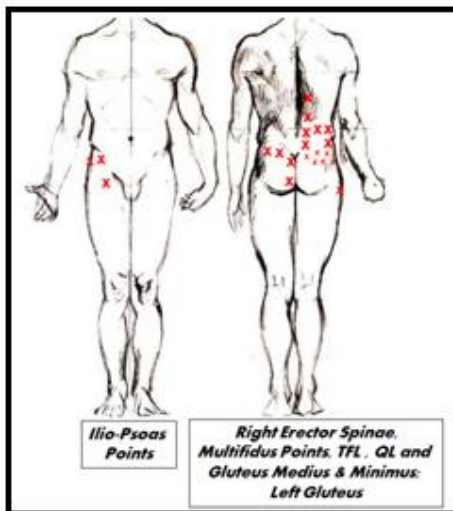


Figure 31: Indicates the trigger point's location to the muscles responsible for the “Innominate Upslip & Anterior rotational stuck with Out-flare & supra-pubic dysfunction”

B. Muscle Energy Technique (MET)

Step-1: The patient was in left lateral recumbent position and the left leg was maintained in fully flexed position, close to the patient's chest wall and fixed by the left hand of the patient. The patient's right hand was allowed to hold the treatment table in over head position and it helps in support the body during the maneuver. Later to this, the therapist moved the patient's fully extended right leg, off and away

from the treatment table. At this point, the patient was advised to press the right leg down, until the range where he/she feels the discomfort to the point of tension of the right Quadratus Lumborum. This was the point of tension or the feather edge barrier range. Smaller than the point of tension range, the patient was advised to lift his/her right leg against the therapist counterforce and hold it approximately for five to ten seconds, followed to the relaxation for three to five seconds. The techniques were repeated three to six times in the lower pain-free length ranges (Fig-13 & 14).

Step-2: The patient was placed in right knee flexed prone position and the hip was passively extended to the range where he/she feels the discomfort to the point of tension of the iliopsoas muscle. This was the point of tension or the feather edge barrier range. Simultaneously, the therapist must support the opposite side leg in extended position, the thigh and pelvic bone in neutral. At this level, with shorter than the feather edge barrier range, the patient was instructed to press his/her knee down against the counterforce created by the therapist. The technique was initially performed with the knee flexion position and repeated the same with the straightened knee (to avoid the contraction of rectus femoris), hold it approximately for five to ten seconds, followed to the relaxation for three to five seconds (Fig-4 & 5).

Step-3: The patient was placed in right knee flexed supine position and the hip was passively flexed and moved towards the chest, until the range where he/she feels the discomfort to the point of tension of the erector spinae muscle. This was the point of tension or the feather edge barrier range. Simultaneously, the therapist must support the opposite side thigh and pelvic bone in neutral, the leg was placed out the treatment table with the hip extended and the knee flexed position. Smaller than the point of tension range, the patient pushes his/her knee towards the front, against the counterforce created by the therapist, and hold it approximately for five to ten seconds, followed to the relaxation for three to five seconds (Fig- 6).

Step-4: The patient was placed in right hip and knee 90° flexed supine position, the therapist was passively rotated his/her right hip externally, until the range where he/she feels the discomfort to the point of tension of the internal rotators of the hip. Simultaneously, the therapist must support the opposite side thigh and pelvic bone in neutral, the leg was placed out the treatment table with the hip extended and the knee flexed position. Smaller than the point of tension range, the patient was advised to move his/her right hip rotate internally, against the counterforce created by the therapist, and hold it approximately for five to ten seconds, followed to the relaxation for three to five seconds.

Step-5: The patient was in hip and knee 45° flexed supine position, the feet are fixed apart in the line of hip and the patient was allowed to abduct his/her both the hips as much as possible to the range where he/she feels the discomfort to the point of tension of the adductor muscles of the hip. This was the point of tension or the feather edge barrier range. Smaller than the point of tension range, the patient was advised to adduct the both hips against the therapist counter force applied by the therapist, and hold it approximately for five to ten seconds, followed to the relaxation for three to five seconds (Fig-25).

The therapist must ensure the followings, the patient's isometric contraction of the Quadratus Lumborum on step-1, the iliopsoas on step-2, the erector spinae muscles on step-3, the internal rotators of the hip during the step-4 and the

adductors of the hip on step-5, the amount of force applied, the correct direction of effort and, the optimal duration (approx five to ten seconds). The technique was repeated approximately for three to six times or discontinued if the patient experiences any discomfort or the neurological symptoms during the procedure. The structural diagnosis was repeated to evaluate the dysfunction has resolved or improved.

10. Upslip with level / low & medial PSIS, high & lateral ASIS, with Superior pubic.

IMPRESSION: Innominate Upslip & posterior rotational stuck with In-flare & supra-pubic dysfunction

SOFT TISSUES IMBALANCES: (Example on right innominate): The lateral stability of the pelvic bones was maintained by the two main factors, Right and Left lateral slings formed by the Quadratus Lumborum above, and the Gluteus muscles below. If the patient exhibits, the presentation of “Ipsilateral Quadratus Lumborum tightness and Gluteus muscles weakness”, results in the up-slip innominate stuck. Normally, the up-slip innominate stuck usually associated with the ipsilateral supra-pubic dysfunctions.

The antero-posterior stability of the pelvic bones was maintained by the two main factors, anterior longitudinal slings formed by the Rectus Abdominis & Ilio-psoas, and the posterior longitudinal slings are Erector spinae & Hamstring group muscles. The internal-external stability of the pelvic bones was maintained by the two other factors, internally by the internal rotators of the hip called, the Tensor fascia latae, the Gluteus medius, and the Gluteus minimus muscles. The external stability was maintained by the internal rotators of the hip called, the piriformis, the triple tendon (superior gemelli – Obturator internus – Inferior gemelli) and the quadratus femoris muscles.

If the patient demonstrates the innominate up-slip stuck and supra-pubic dysfunctions with, the presentation of “ipsilateral tightness of Rectus abdominis and Hamstring muscles”, along with the tightness of the “piriformis, the triple tendon (superior gemelli – Obturator internus – Inferior gemelli) and the quadratus femoris muscles” and the weak counterpart of “Tensor fascia latae, Gluteus medius and Gluteus minimus muscles”, results in the “Innominate Upslip & posterior rotational stuck with In-flare & supra-pubic dysfunction” innominate malalignments (Fig-32).

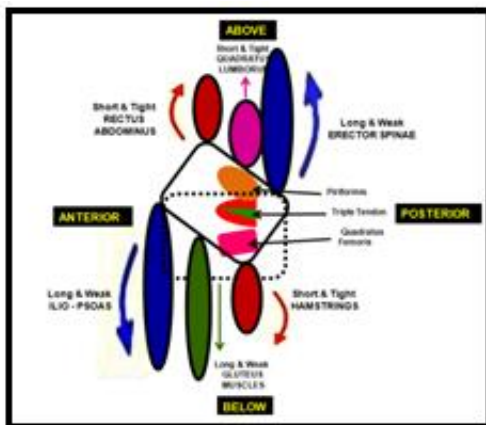


Figure 32: Shows the muscles responsible for the “Innominate Upslip & Posterior rotational stuck with In-flare & supra-pubic dysfunction”

CORRECTION:

A. Trigger Point Release (TrP) for imbalanced soft tissues: (Example on right innominate) (Fig-33)

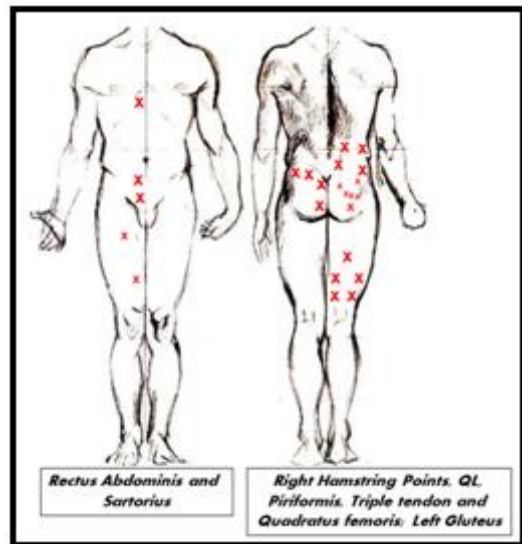


Figure 33: Indicates the trigger point's location to the muscles responsible for the “Innominate Upslip & Posterior rotational stuck with In-flare & supra-pubic dysfunction”

B. Muscle Energy Technique (MET)

Step-1: The patient was in left lateral recumbent position and the left leg was maintained in fully flexed position, close to the patient's chest wall and fixed by the left hand of the patient. The patient's right hand was allowed to hold the treatment table in over head position and it helps in support the body during the maneuver. Later to this, the therapist moved the patient's fully extended right leg, off and away from the treatment table. At this point, the patient was advised to press the right leg down, until the range where he/she feels the discomfort to the point of tension of the right Quadratus Lumborum. This was the point of tension or the feather edge barrier range. Smaller than the point of tension range, the patient was advised to lift his/her right leg against the therapist counterforce and hold it approximately for five to ten seconds, followed to the relaxation for three to five seconds. The techniques were repeated three to six times in the lower pain-free length ranges (Fig-13 & 14).

Step-2 & 3: The patient was placed in Thomas tests position and advised to hold the treatment table on sides. The right leg hip and knee were in 90° flexed, the foot was placed against the body of the therapist and the knee was firmly supported. Simultaneously, the left leg which held off from the treatment table, with the knee flexed and the hip-extended position, here the therapist applied the downward thrust over the knee. At this level, therapists passively flexed the right hip and simultaneously extend the left hip to the range where he/she feels the discomfort to the point of tension of the right hamstring and left rectus abdominis muscles. This was the point of tension or the feather edge barrier range. Smaller than the point of tension range, the patient allowed push his/her knees to approximate each other, i.e., the right leg hip undergoes extension and left hip draws towards flexion. The therapists applied the counterforce against this patient's attempt and hold it approximately for five to ten seconds, followed to the relaxation for three to five seconds. The techniques were repeated in both legs alternatively (Fig-9 & 10).

Step-4: The patient was placed in right hip and knee 90° flexed supine position, the therapist was passively rotated

his/her right hip internally, until the range where he/she feels the discomfort to the point of tension of the external rotators of the hip. Simultaneously, the therapist must support the opposite side thigh and pelvic bone in neutral, the leg was placed out the treatment table with the hip extended and the knee flexed position. Smaller than the point of tension range, the patient was advised to move his/her right hip rotate externally, against the counterforce created by the therapist, and hold it approximately for five to ten seconds, followed to the relaxation for three to five seconds.

Step-5: The patient was in hip and knee 45° flexed supine position, the feet are fixed apart in the line of hip and the patient was allowed to abduct his/her both the hips as much as possible to the range where he/she feels the discomfort to the point of tension of the adductor muscles of the hip. This was the point of tension or the feather edge barrier range. Smaller than the point of tension range, the patient was advised to adduct the both hips against the therapist counter force applied by the therapist, and hold it approximately for five to ten seconds, followed to the relaxation for three to five seconds (Fig-25).

The therapist must ensure the followings, the patient's isometric contraction of the Quadratus Lumborum on step-1, the rectus abdominis and the hamstring muscles on step-2&3, the external rotators of the hip during the step-4 and the adductors of the hip on step-5, the amount of force applied, the correct direction of effort and, the optimal duration (approx five to ten seconds). The technique was repeated approximately for three to six times or discontinued if the patient experiences any discomfort or the neurological symptoms during the procedure. The structural diagnosis was repeated to evaluate the dysfunction has resolved or improved.

3. Core Muscle Strengthening

The trunk muscle helps to stabilize the spine from the pelvis to the neck. It helps to transfer the forces exerts by the powerful movements, to the appendicular skeletons. The majority of the powerful movements are usually originating from the axial region of the body then it was moved out, but it never from the appendicular skeleton alone. Previous to any powerful movements, the rapid muscle contractions occur in the spine, so the spine must maintain their stability using their more stable core muscles.

Sometimes, it appears that the abdominal muscle gets all the credit for protecting the back and forms the foundation of strength, but if strictly speaks, they are only a small part of what makes up the core. In fact, it was a weak and unbalanced core muscles that are linked to pelvic asymmetry or low back pain. The weak core muscles may result in the loss of normal alignments in the bony pelvis. The stronger and balanced core muscles would always help to maintain the appropriate alignment of the spine and bony pelvis.

In my experience, treatments of pelvic malalignments, non-equipment core muscle strengthening exercises are simply called as the body weight exercises are very effective to develop the core muscle strength. Normally, I love to break this core muscle strengthening into four stages, starting with the (i) protective stage, (ii) fundamental stage, (iii) progressing stage and, (iv) advanced specific strengthening stage.

Core muscle strengthening's are most effective, when the torso works as a solid unit, and both the front and back muscles are contracts at the same time, the multi-joint movements are performed, ultimately the stabilization of the spine and bony pelvis are achieved.

Enduring and strengthening the core muscles helps to correct the malalignments of the spine and bony pelvis, this prevents to lead the further injuries. The major advantage in the core muscles training, to develop a normal tone and fitness in the functional slings around the bony pelvis [Ganesh E, et al., 2014].

Discussion

Pain, discomfort, and disabilities are presents primarily in the low back were the main source of sufferings for a large number of peoples in the world. It accounts, for each year more than eighty millions of patients seek advice from the physician for the same. Due to its ubiquitous causes, the low back pains are remains remarkably difficult to elucidate and treat.

Many people are claimed to understand the core cause of this low back pain, but in the reality, it remains an unknown mystery. Two thirds of the adult population is at least once in their life affected by back pain. This pain, as is usually described by the patients, stands in closer sense for complaints of the lower lumbar spine and/or of the lumbo-sacral transition (Ganesh Elumalai et.al., 2016). All the previous experts are worked on this low back pain says that the low back pain is strictly a mechanical phenomenon due to the fatigue and/or strain of the muscles, tendons and ligaments around the lower back. But, some author claims that the predicament was simply due the imbalances in the Psoas major muscle. While some other points that the intervertebral discs are the primary culprits for the majority of the low back pain. Muscle fatigue and excessive muscle tension can cause pain and ache in the muscles and restrict the joint flexibility (Malarvani T et.al. 2014).

Another theory attributes that the most of the low back pains are merely due to the emotional stress. Each of these explanations may probably correct to some extent, but none of them specifies that why these strains and injuries occur or why they transpire with such frequencies. Over the long term this kind of excessive use can irritate the tendons and lead to premature arthritis (Malarvani T et.al., 2014). It may cause compression of surrounding neurovascular structures or it may lead to variation of normal mechanical actions and also can cause erroneous interpretation during routine surgeries (Ajit Kumar, et al., 2014).

Even now we are not confident on which musculoskeletal issues could result in the chronic low back pain issues. Some claim that the chronic muscle strains, lower extremity tendinopathies, periscapular pain, tightness of the paravertebral muscles or tension headaches. I am sure that we can think few of the possibilities, but few can result in all. More often, when a patient reports to our care for the low back pain with one of the aforementioned problems, we immediately take for granted for the nearby particular area or locally. Unfortunately, the real problem may possibly with the rotational innominate stuck or the pelvic upslip, or both. Despite being often overlooked, these malalignments are not hard to identify if we know what to look for.

Pelvic malalignments are referred to the incorrect anatomical alignments of the pelvic bones. This is a very common finding in patients present with low back pain nowadays. Sometimes decreased surface area for the attachment of extensor muscles of the back and so even a mild stress to these muscles will make it strain more and will result in painful conditions of the back (Malarvani, et.al., 2015). When the bones in pelvis alignment are not symmetrically balanced, then the entire spine can be affected, resulting in the

injuries of the back or lower back. If we imagine that the pelvis as the base, into which the spine is installed, then it is easy to visualize the possible potential for these dysfunctions. The morphological variations may predispose people to joint instability, ligaments laxity and the development of arthritic changes (Chowdhury A and Ganesh E, 2013).

The pelvic malalignment syndrome is the most common in sports injuries and even in every client who presents with low back & pelvis pain or dysfunction. According to Kristine Boyle -Walker, palpation and mobility tests have shown poor reliability and validity. But, in our previous study, we used simple bony palpation method to assess the various pelvic malalignments accurately [Ganesh E, et al., 2014; Ganesh E, et al., 2015 and Ganesh E, et al., 2016].

Conclusion

The Innominate malalignments are most common in soccer players. An understanding of this 'malalignment syndrome' requires knowledge of the common presentations of malalignments and the techniques used to diagnose and treat. According to our previous observations, we noticed that there were thirteen (including normal pattern) different alignments in the innominate bone of soccer players. The above-mentioned observations and results are also indicated that an imbalance in the key muscles around the bony pelvis will affect the innominate stability.

In my experience, the treatments for the pelvic malalignments were best, using manual therapy techniques and focused corrective exercises. I've seen many patients with low back pain, who addresses their functional leg length discrepancy by placing a heel lift in their shoe. The heel lift will do nothing if the discrepancies not in an anatomical leg length. In this case, we must correct the causes for the dysfunction not to treat symptomatically. Sometimes, the non-symptomatic individuals may also be shown to have the pelvic asymmetries [Wilson E, et al., 2003]. When I seen an individual's those who are presenting with rotational innominate or upslip innominate or combination of both, I usually perform these three things to correct their pelvic malalignments: (i) trigger point release (TrP), followed by (ii) muscle energy techniques (MET), and followed by an isolated and core (iii) muscles strengthening exercises.

Noted, the pelvic rotations are relative and it is not always necessary to know which side is the dysfunctional side if you are treating them, as you should treat both sides of the pelvis. To justify our diagnosis we always access the muscles of the functional slings and also the muscles which are around the bony pelvis related to the malalignment of the innominate bone. The techniques were rehased for one time each day and proceeded for three to five (depend on the severity of the malalignments) times to standardize.

However, this method of Manual therapeutic corrections in the common pelvic malalignments until then not documented. In this sense, the current study was mainly focused on the analysis of the "Manual therapeutic corrections" on different common presentations in the innominate malalignments, which are common in soccer players and it was the simple method of evaluation and corrections are the literature state of the art. The present study may provide useful information to analyze and correct the various presentations of innominate malalignments in the different sports.

Acknowledgement:

The Authors are very much thankful to Mr.Nandhakumar Kishore and Mr. Kamaraj Soundrapandian for their technical supports to complete this article. The authors are also grateful

to all those articles and journals from where the references for this article has been reviewed and discussed.

References

1. Abdolhamid Daneshjoo et al., Bilateral and Unilateral Asymmetries of Isokinetic strength and Flexibility in Male Young Professional Soccer Players. *Journal of Human Kinetics*. 36, 45-53. 2013.
2. Ajit Kumar, E.Ganesh, T.Malarvani, Manish Kr. Singh. Bilateral Supernumerary heads of Biceps Brachii. *Int J Anat Res*. 2014; 2(4):650-652.
3. Ballantyne, Fiona; Fryer, Gary; McLaughlin, Patrick. "The effect of muscle energy technique on hamstring extensibility: The mechanism of altered flexibility". *Journal of Osteopathic Medicine*. 6 (2): 59–63. 2003.
4. Chowdhury A., Ganesh E. Patterns of calcaneal articular facets and their relationship with sub-talar joint instability in the South-Indian population. *The Journal of Orthopaedics*. Photon.2013; 117: 114-119.
5. Dowling, Dennis J. "Muscle Energy". In DiGiovanna, Eileen L.; Schiowitz, Stanley; Dowling, Dennis J. *An Osteopathic Approach to Diagnosis and Treatment (3rd ed.)*. Philadelphia: Lippincott Williams & Wilkins. 83–85. 2005. ISBN 978-0-7817-4293-1.
6. Fernando Idoate et al., Soccer attenuates the Asymmetry of Rectus abdominis Muscle observed in Non- Athletes. *PLOS ONE*. 6(4), 1-7. 2011.
7. Ganesh Elumalai, Ameet Kumar Jha, Palani Kanagarajan, Sanjoy Sanyal. Soccer Syndrome – 3: Common Sacral Malalignments and Its Manual Diagnostic Techniques. *American Journal of Sports Science*. 4(2): 25-37.2016.
8. Ganesh Elumalai, Malarvani Thangamani, Nirmala Palayathan, Ajit Kumar, Manish Kr Singh. Soccer Syndrome - Common Presentations and Manual Diagnostic Techniques for Pelvic Malalignment Syndrome. *American Journal of Sports Science*. 2(6):141-154. 2014.
9. Ganesh Elumalai, Malarvani Thangamani, Sanjoy Sanyal, Palani Kanagarajan. Deficient Sacral Hiatus Cause Mechanical Low Back Pain: A Radiological Study. *Int J Anat Res*. 2016; 4(1):1758-64.
10. Ganesh Elumalai, Maria Declaro, Sanjoy Sanyal, Melchor Bench Bareng, Aminuddin Mohammad. Soccer Syndrome - 2: Common Innominate Malalignments and Its Manual Diagnostic Techniques in Pelvic Malalignments Syndrome. *American Journal of Sports Science*. 3(6): 120-127. 2015.
11. Gemmel H, Miller P, Nordstrom H. Immediate effect of ischaemic compression and trigger point pressure release on neck pain and upper trapezius trigger point: a randomized controlled trial. *Clin Chiropract*. 11:30–6.2008.
12. Hou CR, Tsai LC, Cheng KF, Chung KC, Hong CZ. Immediate effects of various physical therapeutic modalities on cervical myofascial pain and trigger-point sensitivity. *Arch Phys Med Rehabil*. 83:1406–14. 2002.
13. Julie Hides & Warren Stanton. Muscle imbalance among Elite Australian Rules Football Players, A longitudinal study of changes in trunk muscle size. *Journal of Athletic training*. 47 (3), 314 - 319. 2012.
14. Lenehan KL, Fryer G, McLaughlin P. The effect of muscle energy technique on gross trunk range of motion. *J Osteopath Med*. 6:13–18.2003.
15. Malarvani T, Ganesh E, Nirmala P, Ajit Kumar, Manish Kr. Singh. WhatsAppitis: Recent Study on SMS Syndrome. *Sch. J. App. Med. Sci.*, 2014; 2(6B):2026-203

16. Malarvani T, Ganesh E, Nirmala P. Study of Sacral hiatus in dry human Sacra in Nepal, Parsa Region. *Int J Anat Res.* 2015; 3(1):848-855.
17. Pelvic Evaluation. www.waltfritzseminars.com/myofascial_resource/wp_content/uploads/2010/09/
18. stoneathleticmedicine.com/2014/05/pelvic-upslip-and-rotation-evaluation-and-treatment/.
19. Wilson E, Payton O, Donegan-Shoaf L, Dec K. Muscle energy technique in patients with acute low back pain: A pilot clinical trial. *J Orthop Sports Phys Ther.* 33:502–512.2003.