



“CONGENITAL DIAPHRAGMATIC HERNIA” EMBRYOLOGICAL BASIS AND ITS CLINICAL SIGNIFICANCE

Ganesh Elumalai and Kelly Deosaran

Department of Embryology, College of Medicine, Texila American University, South America.

ARTICLE INFO

Article history:

Received: 12 October 2016;

Received in revised form:

13 November 2016;

Accepted: 23 November 2016;

Keywords

Diaphragmatic hernia,

Bochdalek hernia,

Hiatal hernia,

Pulmonary hyperplasia,

Pulmonary hypertension,

Central tendon defects.

ABSTRACT

Congenital Diaphragmatic Hernia (CDH) is defined by the presence of an orifice in the diaphragm, more often left and posterolateral that permits the herniation of abdominal contents into the thorax. The lungs are hypoplastic and have abnormal vessels that cause respiratory insufficiency and persistent pulmonary hypertension with high mortality. The etiology is unknown although clinical, genetic and experimental evidence points to disturbances in the retinoid-signaling pathway during organogenesis. Chronic respiratory tract disease, neurodevelopmental problems, neuro-sensorial hearing loss and gastro-esophageal reflux are common problems in survivors. Much more research on several aspects of this severe condition is necessary.

© 2016 Elixir All rights reserved.

Introduction

The diaphragm is the dome-shaped sheet made up of muscle and tendon that serves as the main muscle of respiration. It plays a vital role in the course of breathing [1-2]. It's known as the thoracic diaphragm which serves as an important anatomical landmark that separates the thorax or chest from the abdomen [2-4]. Origins of the diaphragm can be found along the lumbar vertebrae of the spine and also the inferior border of the ribs and sternum. There are openings in the diaphragm which allows the esophagus, phrenic and vagus nerves, descending aorta and inferior vena cava to pass between the thoracic and abdominal cavities [3-5]. Structurally, the diaphragm consists of two parts. These include the peripheral muscle and central tendon. The peripheral muscle is made up of many radical muscle fibers (originating on the ribs, sternum and spine) it joins on the central tendon [5-8]. The central tendon (a flat aponeurosis that's made up of collagen fibers) acts as the strong insertion point of the muscles. When oxygen is inhaled into the lungs, the diaphragms muscle contract and thus pull the central tendon inferiorly into the abdominal cavity [9].

As this is happening, the thorax enlarges and allows air to inflate the lungs. The peripheral muscle can then be further divided into the sternal, coastal and lumbar regions [8-10]. Two small muscular segments that attach to the posterior aspect of the xiphoid process makes up the sternal region. The coastal region is made up of several wide muscle segments whose origins are found on the internal surface of the inferior six ribs and the coastal cartilages. The origins of the lumbar region are on the lumbar vertebra by way of two pillars of tendon called the “musculotendinoscrura” [10-15]. These muscles wraps around the aorta as it passes through the diaphragm to form the aortic hiatus. Sometimes, the diaphragm contracts involuntarily due to certain irritations [16].

These contractions can happen due to different reasons which may include us eating too quickly, drinking carbonated beverages, experiencing some acid indigestion or even if we're dealing with a stressful day [15]. If any of these situations occur and we inhale air at the same time of contraction, the space between the vocal cords at the back of the throat suddenly closes, thus producing a noise known as hiccups. Short-lived hiccups are very common whereas longer-term hiccups (can last for days) can also occur and it's usually caused by irritated nerves [16-18]. Medical attention would be highly recommended in order to rule out any other health concerns.

Diaphragmatic hernia is a birth defect (an abnormality that occurs before birth). It develops as a fetus is forming in the mother's uterus. A congenital diaphragmatic hernia (CDH) occurs when the diaphragm does not develop correctly [19]. As it's known, the diaphragm is an important muscle for breathing, and if there's an opening in the diaphragm, organs that are usually in the abdomen can be pushed through the opening into the chest [19-25]. During the growth of the fetus in the mother's uterus before birth, different organ systems will be developing and maturing. During the 7th and 10th week of pregnancy, the diaphragm develops. During this time, the esophagus, the stomach and the intestines are also being developed [25]. In CDH, the diaphragm does not develop properly, thus causing some or all parts of the abdominal organs to move into the chest. Some of these organs may include; the stomach, spleen, intestine and/or liver [26-27]. The dislocation of these organs into the chest can affect how the lungs develop and grow. In most cases of diaphragmatic hernia, it is alleged to be multi-factorial in origin [27]. When multi-fractional is mentioned' it means that many factors, being both genetic and environmental are involved. Multiple genes from both parents and also a number of environmental factors contribute to the development of congenital

diaphragmatic hernia [28]. Though this is believed, scientist do not fully understand why or how it happens.

Incidence

Congenital diaphragmatic hernia is a rare abnormality and occurs 1 in 2000 to 1 in 5000 live births [29].

Ontogenesis for the normal development of diaphragm

In the embryo, the diaphragm is made from a number of complex parts. However, the septum transversum is the most important [30-33]. By understanding the history of the formation of the diaphragm, it will help in explaining why the heart, lungs, gut tube, liver, neck, and fascia all tie together with the diaphragm.

As the diaphragm is growing, it drags the phrenic nerves down from the cervical region unto the thoracic region. Irritation to the diaphragm is frequently referred to as neck and shoulder pain. This irritation is due to the facilitation in the cervical cord induced by the phrenic nerves [33]. Pathology of the spleen or gallbladder is well known to cause referred pain to the shoulder region. Also, the reverse is true. The neck issues can cause referred pain to the diaphragm [34-36].

Closely connected with the heart is the diaphragm. At the cranial end of the embryonic disc, there are very early structures that form from the same area of the mesenchyme [37]. Underneath the septum transversum, the liver grows. A part of the septum transversum then separates into the membrane around the liver.

The diaphragm is a dome-shaped, muscular partition separating the thorax from the abdomen in mammals. It plays a vital role in breathing, as its contraction increases the volume of the thorax and so inflates the lungs [38]. It develops from four major structures. These include the septum transversum, the pleuroperitoneal, the dorsal esophageal mesentery and the body wall.

The septum transversum forms the central tendon. It's first seen as a dense mesodermal plate cranial to the pericardial cavity between the base of the thoracic cavity and the stalk of the yolk sac [39-41]. The septum transversum does not separate the thoracic and abdominal cavities completely. After the head folds forms in the 4th week, it becomes a thick incomplete partition between the cavities with an opening on each side of the gut, therefore known as the pleural canals [41-44]. The septum then fuses dorsally with the primitive mediastinal mesenchyme below the esophagus and then later with the pleuroperitoneal membranes [44]. The pleuroperitoneal membrane now fuses with the dorsal mesentery of the esophagus and with the dorsal part of the septum transversum to complete the partition between the thoracic and abdominopelvic cavities. This forms the primitive diaphragm [45]. Out of the final adult structure, it only represents a small portion.

The dorsal esophageal mesentery also known as the mesoesophagus fuses with both the septum transversum and this mesentery, and it forms the median portion of the diaphragm [42-45]. The muscle fiber which grows into the esophageal mesentery, the crura of the diaphragm is developed from it.

The body wall during the time span of the 9th and 12th week, the pleural cavities expands and enters the lateral body walls [46]. At this time the body wall tissue splits off medially to form the peripheral parts of the diaphragm outside that's formed by the pleuroperitoneal membranes [47]. The costodiaphragmatic recesses are formed from the extensions of the pleural cavities into the body wall.

Innervations and location of the diaphragm during the 4th week, the septum transversum lies opposite the upper cervical somites and during the 5th week, the nerves from the cervical segments, C3, C4, and C5 will grow into the septum and form the phrenic nerve [48]. This nerve then passes to the septum via the pleuropericardial membrane, thus causing the nerves to lie in the fibrous pericardium. An apparent descent of both diaphragm and nerves by the 6th week to the thoracic level may be a result of the rapid growth of the dorsal embryo body compared to its ventral part [49-51]. By the 8th week now, the dorsal part of the diaphragm lies at the level of the first lumbar vertebrae. Thus, causing the nerves carried down with it from the cervical region.

Ontogenesis of the abnormal development of the diaphragm

Congenital diaphragmatic hernia is a common malformation in newborns occurring in about 1/2000 to 1/5000 live births and it's usually as a posterolateral defect of the diaphragm [46-50]. This usually results in a defective formation and/or fusion of the pleuroperitoneal membrane(s) which usually separates the pleural and peritoneal cavities. The defect is usually unilateral with a large opening in the posterolateral part of the diaphragm. This opening is known as the 'foramen of Bochdalek' [50]. More often it is seen on the left because of an earlier closure on the right pleuroperitoneal opening. The intestines may pass into the chest if the pleuroperitoneal membrane is not fused when the intestines return to the abdomen from the umbilical cord during the 10th week [52-55]. You'll rarely see the stomach, spleen, cecum, appendix and parts of the colon in the chest cavity, and if present at birth, there's a high possibility that it will interfere with respiration. The heart and mediastinum are often displaced and the lungs are usually small and hypoplastic [55].

Posterior lateral defect of the diaphragm (Bochdalek) This shortcoming represents over 70% of diaphragmatic hernias. It begins above and lateral to the left lateral arcuate ligament at the vertebral costal trigone [56]. The result occurs during the intestinal return to the abdominal cavity around the 10th week of embryonic life. At that time, the trigone is made up mainly of membranous tissue with rare muscle fibers [56]. The increased intra-abdominal pressure causes the separation of the muscle fibers and creates the defect. The defect can be small in size or sometimes in extreme cases almost the entire hemi diaphragm is involved. Approximately 90% of this defect occurs on the left side while the right side represents less than 10% [57-60]. In 99% of the cases, it is unilateral. Herniation of the small intestines, stomach, colon, spleen and part of the liver may occur (Skandalakis 2004). Subsequently, pulmonary hypoplasia with mediastinal shift arises [60].

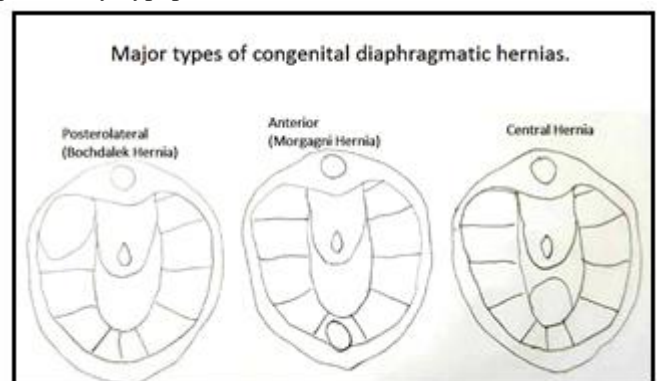


Fig 1. Schematic diagram showing different types of diaphragmatic hernias

Embryological basis for congenital diaphragmatic hernia

Diaphragm formation; Body folding brings the septum transversum caudal to the pericardial cavity. There are five major components of the diaphragm and these include the Septum transversum, two pleuroperitoneal membranes, the esophageal mesentery and the body wall [61-63]. Any failure during the development of these tissues or any weakness in the connection could lead to congenital diaphragmatic hernia and possibly other embryo development. The mid-gut grows more rapidly and larger than the embryo can sustain, thus leading it to extend into the umbilical stalk [65]. Around the 10th week, it returns to the abdominal cavity thus continuing further formation and folding of the GI tract. The premature return of the mid-gut, prior to the formation of the diaphragm will result in congenital diaphragmatic hernia due to the increased pressure from the abdominal cavity thus causing the contents to rupture into the thoracic cavity [64]. Likewise, the appropriate return of the mid-gut with delayed diaphragm formation can also result in the congenital diaphragmatic hernia. If the lungs do not develop correctly later in fetal development, the mechanical pressure from the abdomen, even with a fully formed diaphragm will cause the abdominal contents to shove into the thoracic cavity thus increasing pressure on the thoracic viscera [66]. The Bronchial and alveolar development lag behind much other organ development.

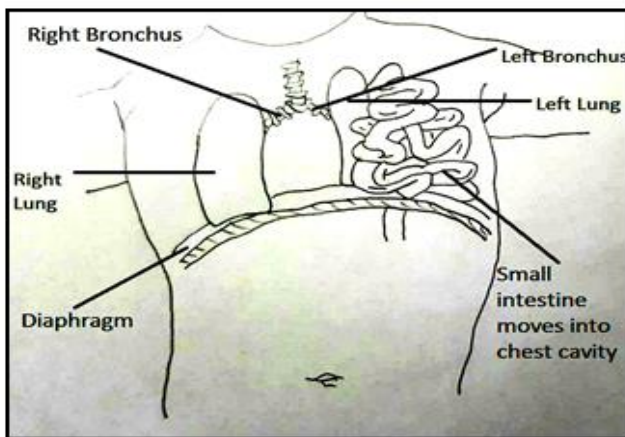


Fig 2. Schematic diagram showing organs from the abdominal cavity moving into the chest through the Diaphragmatic hernia.

Discussion

The diaphragm is the main muscle of respiration and the second most important muscle within the body after the heart. Because the body depends on so much on the diaphragm for respiratory function, having the knowledge of how many different diseases processes eventually result in dysfunction of the diaphragm is extremely important [68-71]. The diaphragm is a modified half-dome of musculofibrous tissue that separates the thorax and the abdomen. Four embryologic components make up the formation of the diaphragm [71]. These components include the septum transversum, two pleuroperitoneal folds, the cervical (and thoracic) myotomes and the dorsal mesentery.

During the 3rd week of gestation, development begins and is finalized by the 8th week. Results of congenital defects occur due to failure of the pleuroperitoneal folds and subsequent muscle migration [69]. The muscular origin of the diaphragm is from the lower six ribs bilaterally, the posterior xiphoid process and from the external and internal arcuate ligaments.

A series of different structures transverse the diaphragm, and these include three distinct apertures that allow the passage of the aorta, the esophagus and the vena cava [69].

The aortic aperture is the bottommost and most posterior of the openings thus lying at the level of T12. The thoracic duct and sometimes the azygos and hemiazygos are transmitted by the aortic opening [70]. The esophageal aperture lies at the level of T10 and is surrounded by diaphragmatic muscle. The highest of the three openings is the vena caval aperture and this lies within the disc space of T8 and T9.

Arterial supply to the diaphragm comes from the right and left phrenic arteries, the intercostal arteries, and the musculophrenic branches of the internal thoracic arteries [70]. Some arterial blood is provided from small branches of the pericardiophrenic arteries that run with the phrenic nerve primarily where the nerves pierce the diaphragm [68]. Venous drainage is via the inferior vena cava whereas azygos vein is on the right and the adrenal/renal and the hemiazygos veins is on the left.

The sole muscular neurologic impulse of the diaphragm is received from the phrenic nerve. This originates primarily from the 4th cervical ramus but also has contributions from the 3rd and 5th rami [67]. Emanating around the level of the scalenus anterior, the phrenic nerve courses inferiorly through the neck and passes into the thorax before reaching its destination, the diaphragm. Because of the long course the phrenic nerve has before arriving at its terminal, any process that disrupts the transmission of neurologic impulse through it, directly affect the diaphragm [66].

CDH is often ultrasonographically diagnosed before birth. The intestine and/or the liver may be in the thorax and the lungs are small. US scan allows detailed assessment of the heart. Lung growth is measured as a proportion of head growth [70]. This lung-to-head ratio (LHR) has some prognostic value because when it is below 1, survival is compromised. However, the accuracy of these measurements is questionable and other alternatives like lung/thorax (L/T) transverse area ratio] or volumetry by MRI have been developed [69]. The position of the liver is also of unquestionable value, since liver-up cases more often require extracorporeal membrane oxygenation (ECMO) support and have worse survival. The intra-thoracic location of the stomach has less value for this purpose. When diagnosis is made in utero, amniocentesis is often performed for detecting chromosomal aberrations and may help to estimate lung maturity [71]. After birth, the diagnosis is readily made on the basis of symptoms and physical signs. A plain X-ray of the thorax and abdomen informs of the position of the herniated viscera. Ultrasonography of the heart is essential for ruling out associated malformations, for measuring the right-to-left shunt and for estimating the severity of pulmonary hypertension [70].

It is hardly necessary to rule out other conditions because CDH is often identified before birth and because diagnosis is easy [69]. Physical exam may avail but passing a nasogastric catheter into the stomach before a plain X-ray of the thorax and abdomen may help to locate it or to detect esophageal displacement. In some rare instances, X-rays may suggest a cystic malformation of the lung but again the position of the stomach and the contour of the intra-abdominal gas bubbles facilitate distinction the conditions [70].

Congenital Diaphragmatic Hernia occurs when the diaphragm doesn't close nor form around the 8th week of

gestation. Thus, causes the organs that are supposed to be in the abdominal cavity to now move freely into the thoracic cavity, taking up valuable lung space. The reason why this happens is still unclear as more research is necessary [70]. Though the cause is still unknown for CDH, it tends to sometimes run in families. Thus being primarily with genetic problems and other families problems. The outcome of some studies show that CDH can also occur due to certain environmental factors. Research is still ongoing for such said reason [66].

Until the cause of CDH is identified and a cure is found, this cannot be prevented. There is just no way of knowing how to prevent CDH right away and parents shouldn't blame themselves for not knowing how to prevent it. You may take pre-natal vitamin but there is no guarantee that congenital diaphragmatic hernia is caused by a vitamin deficiency [68]. Congenital diaphragmatic hernia occurs in about 1 in every 2000 to 1 in 5000 live births, Or less that 5 in 10000 births.

The diaphragm is a multi-function organ, with its main function being its critical role in respiration. During respiration, the actions of the diaphragm are central for inspiration. Contraction of the diaphragm muscle flattens the dome-shaped diaphragm and central tendon, thus expanding the volume of the thoracic cavity, reducing thoracic pressure and allowing air to flow into the lungs [66]. In addition to respiration, the diaphragm (particularly the crural domain) has functional roles in swallowing and emesis. Finally, the diaphragm also has a passive functional role. Thus serves as a barrier between the thoracic and abdominal cavities. The importance of this barrier function is dramatically apparent in newborns with Congenital Diaphragmatic Hernias (CDH), whereby a weak or incompletely formed diaphragm allows abdominal contents to herniate into the thoracic cavity and harm lung development [67].

The presence of a muscularized diaphragm is unique to and, in fact, a defining characteristic of mammals. It has been proposed that the diaphragm evolved in mammals as a stabilizer of the abdominal viscera and an inspiratory muscle [69]. Together these functions of the diaphragm allowed mammals to evolve as high-performance homeotherms, capable of concomitant respiration and locomotion. Thus the question of how the mammalian diaphragm evolved is an important question. Presumably, developmental innovations were critical for the development of a muscularized diaphragm, but the molecular and cellular nature of these innovations is currently unknown [70].

Conclusion

An extensive amount of investigation has been done in order to explain the origins of congenital diaphragmatic hernia. CDH is a complex condition possibly caused by disturbed molecular signaling during organogenesis [70]. The diaphragmatic opening is always accompanied by pulmonary hypoplasia with vascular hyper-reactivity that causes scares gas exchange and persistent pulmonary hypertension. Additionally, other malfunctions that complicate the clinical course may also be present [71]. However, all efforts are directed at enhancing the antenatal lung growth in the prenatally diagnosed cases and also at protecting the lung during the intensive care, pre and post-operative phases all cases. Surgical repair is the only treatment. Delaying surgical treatment until the patient is stable, is associated with better results [70].

References

- [1] Ajit Kumar, E.Ganesh, T.Malarvani, Manish Kr. Singh. Bilateral supernumerary heads of biceps brachii. *Int J Anat Res.* 2014; 2(4):650-52.
- [2] Ajit Kumar, Ganesh Elumalai, Malarvani Thangamani, Nirmala Palayathan, Manish Kr Singh. A Rare Variation in Facial Artery and Its Implications in Facial Surgery: Case Report. *Journal of Surgery.*2014; 2(5): 68-71.
- [3] Ganesh Elumalai, Sushma Chodisetty. Anomalous "Mutilated Common Trunk" Aortic Arch Embryological Basis and its Clinical Significance. *Texila International Journal of Basic Medical Science.* 2016; 1(1): 1-9.
- [4] Ganesh Elumalai, Emad Abdulrahim Ezzeddin. "The sudden soul reaper" - hypertrophic cardiomyopathy – its embryological basis. *Elixir Embryology.* 2016; 99: 43284-43288.
- [5] Ganesh Elumalai, Muziwandile Bayede Mdletshe. "Arteria lusoria"- aberrant right subclavian artery embryological basis and its clinical significance. *Elixir Embryology.* 2016; 99: 43289-43292.
- [6] Ganesh Elumalai, Sushma Chodisetty, Pavan Kumar D.2016. Ganesh Elumalai et al Classification of Type - I and Type - II "Branching Patterns of the Left Arch Aorta". *Imperial Journal of Interdisciplinary Research.* 2(9): 161-181.
- [7] Ganesh E, Sushma C. The deer horn aortic arches" embryological basis and surgical implications. *Anatomy Journal of Africa.*2016; 5(2): 746 – 759.
- [8] Ganesh Elumalai, Sushma Chodisetty. Teratological Effects of High Dose Progesterone on Neural Tube Development in Chick Embryos. *Elixir Gynaecology.* 2016; 97: 42085-42089.
- [9] Ganesh Elumalai, Sushma Chodisetty. "The True Silent Killers" - Bovine and Truncus Bicaroticus Aortic Arches its Embryological Basis and Surgical Implications. *Elixir Physio. & Anatomy.* 2016; 97: 42246-42252.
- [10] Ganesh Elumalai, Sushma Chodisetty, Bridget Omo Usen and Rozminabanu Daud Patel. "Patent Ductus Caroticus" - Embryological Basis and its Clinical significance. *Elixir Physio. & Anatomy.* 2016; 98: 42439-42442.
- [11] Ganesh Elumalai, Sushma Chodisetty, Eliza Arineta Oudith and Rozminabanu Daud Patel. Common anomalies origin of left vertebral artery and its embryological basis. *Elixir Embryology.* 2016; 99: 43225-43229.
- [12] Ganesh Elumalai, Sushma Chodisetty, Sanjoy Sanyal. Common Nasal Anomalies and Its Implications on Intubation in Head and Neck Surgeries. *Journal of Surgery.* 2016; 4 (4): 81-84.
- [13] Ganesh Elumalai, Malarvani Thangamani, Sanjoy Sanyal, Palani Kanagarajan. Deficient sacral hiatus cause mechanical low back pain: a radiological study. *Int J Anat Res.* 2016; 4(1):1758-64.
- [14] "About CDH (Adapted from the New York Presbyterian Morgan Stanley Children's Hospital ICU Parent orientation CD) (2009-2016)". Retrieved from <http://www.cdhgenetics.com/congenital-diaphragmatic-hernia.cfm>
- [15] "Management of congenital diaphragmatic hernia". Adrian T. Bosenberg and Robin A. Brown (2008). Retrieved from http://anessom.ucsd.edu/Intranet/Peds_Resources/Neonatal%20Surg%20Emergencies/Cdh%20overview.pdf
- [16] "Pediatric Congenital Diaphragmatic Hernia." Robin H Steinhorn, MD Raymond and Hazel Speck Berry Professor of Pediatrics, Division Head of Neonatology, Vice Chair of

- Pediatrics, Northwestern University, The Feinberg School of Medicine. Retrieved from <http://emedicine.medscape.com/article/978118-overview?pa=ZCbBbk20Xoyjh%2FZE%2FKVrpSGfvvtjAT2wL%2FKvZjvb2fu85ooVDBonSffPPvgTXfo%2BXNymjIm7g1%2FCBEuDrED11%2FDMAtBBAsM6eN9kpLn%2Fas%3D>
- [17] "CONGENITAL DIAPHRAGMATIC HERNIA Multidisciplinary Management" Jen-Tien Wung, MD, FCCM Division of Neonatology Morgan Stanley Children's Hospital of New York Columbia University Medical Center. Retrieved from <http://www.perinatal.com.br/8simposio/pdf/Aula%207%20Wung%20CDH.pdf>
- [18] "Congenital Diaphragmatic Hernia"
- [19] Manuel A. Molina, M.D. Manuel A. Molina, M.D.
- [20] University Hospital at Brooklyn University Hospital at Brooklyn
- [21] SUNY Downstate. Retrieved from http://www.downstatesurgery.org/files/cases/congenital_diaphragmatic_hernia.pdf
- [22] "Congenital Diaphragmatic Hernia with Emphasis on Embryology, Subtypes, and Molecular Genetics" Bahig M. Shehata and Jenny Lin Children's Healthcare of Atlanta, Atlanta, GA Emory University School of Medicine, Atlanta, GA
- [23] USA. Retrieved from <http://cdn.intechopen.com/pdfs-wm/37826.pdf>
- [24] Vijfhuizen S, Schaible T, Kraemer U, Cohen-Overbeek TE, Tibboel D, Reiss I. Management of pulmonary hypertension in neonates with congenital diaphragmatic hernia. *Eur J Pediatr Surg*. 2012 Oct. 22(5):374-83
- [25] Harrison MR, Keller RL, Hawgood SB, et al. A randomized trial of fetal endoscopic tracheal occlusion for severe fetal congenital diaphragmatic hernia. *N Engl J Med*. 2003 Nov 13. 349(20):1916-24.
- [26] Jelin E, Lee H. Tracheal occlusion for fetal congenital diaphragmatic hernia: the US experience. *Clin Perinatol*. 2009 Jun. 36(2):349-61, ix.
- [27] Gross RE. Congenital hernia of the diaphragm. *Am J Dis Child*. 1946. 71:579-592.
- [28] Areechon W, Reid L. Hypoplasia of the lung associated with congenital diaphragmatic hernia. *Br Med J*. 1963. i:230-3.
- [29] Klaassens M, de Klein A, Tibboel D. The etiology of congenital diaphragmatic hernia: still largely unknown?. *Eur J Med Genet*. 2009 Sep-Oct. 52(5):281-6.
- [30] Jandus P, Savioz D, Purek L, Frey JG, Schnyder JM, Tschoop JM. [Bochdalek hernia: a rare cause of dyspnea and abdominal pain in adults]. *Rev Med Suisse*. 2009 May 13. 5(203):1061-4.
- [31] Fisher JC, Haley MJ, Ruiz-Elizalde A, Stolar CJ, Arkovitz MS. Multivariate model for predicting recurrence in congenital diaphragmatic hernia. *J Pediatr Surg*. 2009 Jun. 44(6):1173-9; discussion 1179-80.
- [32] Keller RL, Tacy TA, Hendricks-Munoz K, et al. Congenital diaphragmatic hernia: endothelin-1, pulmonary hypertension, and disease severity. *Am J Respir Crit Care Med*. 2010 Aug 15. 182(4):555-61.
- [33] Sluiter I, Veenma D, van Loenhout R, Rottier R, de Klein A, Keijzer R, et al. Etiological and pathogenic factors in congenital diaphragmatic hernia. *Eur J Pediatr Surg*. 2012 Oct. 22(5):345-54.
- [34] Clugston RD, Zhang W, Alvarez S, De Lera AR, Greer JJ. Understanding Abnormal Retinoid Signaling as a Causative Mechanism in Congenital Diaphragmatic Hernia. *Am J Respir Cell Mol Biol*. 2009 May 15.
- [35] Mitanchez D. [Neonatal prognosis of congenital diaphragmatic hernia]. *Arch Pediatr*. 2009 Jun. 16(6):888-90.
- [36] Keller RL. Antenatal and postnatal lung and vascular anatomic and functional studies in congenital diaphragmatic hernia: implications for clinical management. *Am J Med Genet C Semin Med Genet*. 2007 May 15. 145C(2):184-200.
- [37] Bryner BS, West BT, Hirschl RB, et al. Congenital diaphragmatic hernia requiring extracorporeal membrane oxygenation: does timing of repair matter?. *J Pediatr Surg*. 2009 Jun. 44(6):1165-71; discussion 1171-2.
- [38] Deprest JA, Gratacos E, Nicolaides K, et al. Changing perspectives on the perinatal management of isolated congenital diaphragmatic hernia in Europe. *Clin Perinatol*. 2009 Jun. 36(2):329-47, ix.
- [39] Walsh-Sukys MC, Tyson JE, Wright LL, et al. Persistent pulmonary hypertension of the newborn in the era before nitric oxide: practice.
- [40] Fliman PJ, deRegnier RA, Kinsella JP, Reynolds M, Rankin LL, Steinhorn RH. Neonatal extracorporeal life support: impact of new therapies on survival. *J Pediatr*. 2006 May. 148(5):595-9.
- [41] Gentili A, Giuntoli L, Bacchi Reggiani ML, Masciopinto F, Lima M, Baroncini S. Neonatal congenital diaphragmatic hernia: respiratory and blood-gas derived indices in choosing surgical timing. *Minerva Anesthesiol*. 2012 Oct. 78(10):1117-25.
- [42] Peetsold M, Huisman J, Hofman VE, Heij HA, Raat H, Gemke RJ. Psychological outcome and quality of life in children born with congenital diaphragmatic hernia. *Arch Dis Child*. 2009 Jun 15.
- [43] Albanese CT, Lopoo J, Goldstein RB, et al. Fetal liver position and perinatal outcome for congenital diaphragmatic hernia. *Prenat Diagn*. 1998 Nov. 18(11):1138-42.
- [44] Bohn DJ, Pearl R, Irish MS, Glick PL. Postnatal management of congenital diaphragmatic hernia. *Clin Perinatol*. 1996 Dec. 23(4):843-72.
- [45] Clark RH, Hardin WD Jr, Hirschl RB, et al. Current surgical management of congenital diaphragmatic hernia: a report from the Congenital Diaphragmatic Hernia Study Group. *J Pediatr Surg*. 1998 Jul. 33(7):1004-9.
- [46] Colvin J, Bower C, Dickinson JE, Sokol J. Outcomes of congenital diaphragmatic hernia: a population-based study in Western Australia. *Pediatrics*. 2005 Sep. 116(3):e356-63.
- [47] Cortes RA, Keller RL, Townsend T, et al. Survival of severe congenital diaphragmatic hernia has morbid consequences. *J Pediatr Surg*. 2005 Jan. 40(1):36-45; discussion 45-6.
- [48] Finer NN, Tierney A, Etches PC, Peliowski A, Ainsworth W. Congenital diaphragmatic hernia: developing a protocolized approach. *J Pediatr Surg*. 1998 Sep. 33(9):1331-7.
- [49] Garred P, Madsen HO, Balslev U, et al. Susceptibility to HIV infection and progression of AIDS in relation to variant alleles of mannose-binding lectin. *Lancet*. 1997 Jan 25. 349(9047):236-40.
- [50] Kapur P, Holm BA, Irish MS, Patel A, Glick PL. Tracheal ligation and mechanical ventilation do not improve the antioxidant enzyme status in the lamb model of congenital diaphragmatic hernia. *J Pediatr Surg*. 1999 Feb. 34(2):270-2.

- [51] Kays DW, Langham MR Jr, Ledbetter DJ, Talbert JL. Detrimental effects of standard medical therapy in congenital diaphragmatic hernia. *Ann Surg.* 1999 Sep. 230(3):340-8; discussion 348-51.
- [52] Kehl S, Becker L, Eckert S, Weiss C, Schaible T, Neff KW, et al. Prediction of mortality and the need for neonatal extracorporeal membrane oxygenation therapy by 3-dimensional sonography and magnetic resonance imaging in fetuses with congenital diaphragmatic hernias. *J Ultrasound Med.* 2013 Jun. 32(6):981-8.
- [53] Kinsella JP, Parker TA, Ivy DD, Abman SH. Noninvasive delivery of inhaled nitric oxide therapy for late pulmonary hypertension in newborn infants with congenital diaphragmatic hernia. *J Pediatr.* 2003 Apr. 142(4):397-401.
- [54] Lally KP. Extracorporeal membrane oxygenation in patients with congenital diaphragmatic hernia. *Semin Pediatr Surg.* 1996 Nov. 5(4):249-55.
- [55] Lally KP, Breaux CW Jr. A second course of extracorporeal membrane oxygenation in the neonate--is there a benefit?. *Surgery.* 1995 Feb. 117(2):175-8.
- [56] Lally KP, Lally PA, Langham MR, et al. Surfactant does not improve survival rate in preterm infants with congenital diaphragmatic hernia. *J Pediatr Surg.* 2004 Jun. 39(6):829-33.
- [57] Langham MR Jr, Kays DW, Ledbetter DJ, Frentzen B, Sanford LL, Richards DS. Congenital diaphragmatic hernia. Epidemiology and outcome. *Clin Perinatol.* 1996 Dec. 23(4):671-88.
- [58] [Guideline] Maisch B, Seferovic PM, Ristic AD, et al. Guidelines on the diagnosis and management of pericardial diseases. *European Society of Cardiology.* 2004.
- [59] NINOS. Inhaled nitric oxide and hypoxic respiratory failure in infants with congenital diaphragmatic hernia. The Neonatal Inhaled Nitric Oxide Study Group (NINOS). *Pediatrics.* 1997 Jun. 99(6):838-45.
- [60] Nobuhara KK, Lund DP, Mitchell J, Kharasch V, Wilson JM. Long-term outlook for survivors of congenital diaphragmatic hernia. *Clin Perinatol.* 1996 Dec. 23(4):873-87.
- [61] Nobuhara KK, Wilson JM. Pathophysiology of congenital diaphragmatic hernia. *Semin Pediatr Surg.* 1996 Nov. 5(4):234-42.
- [62] O'Toole SJ, Irish MS, Holm BA, Glick PL. Pulmonary vascular abnormalities in congenital diaphragmatic hernia. *Clin Perinatol.* 1996 Dec. 23(4):781-94.
- [63] Reickert CA, Hirschl RB, Atkinson JB, et al. Congenital diaphragmatic hernia survival and use of extracorporeal life support at selected level III nurseries with multimodality support. *Surgery.* 1998 Mar. 123(3):305-10.
- [64] Slavotinek AM. The genetics of congenital diaphragmatic hernia. *Semin Perinatol.* 2005 Apr. 29(2):77-85.
- [65] Stege G, Fenton A, Jaffray B. Nihilism in the 1990s: the true mortality of congenital diaphragmatic hernia. *Pediatrics.* 2003 Sep. 112(3 Pt 1):532-5.
- [66] Steinhorn RH, Kriesmer PJ, Green TP, McKay CJ, Payne NR. Congenital diaphragmatic hernia in Minnesota. Impact of antenatal diagnosis on survival. *Arch Pediatr Adolesc Med.* 1994 Jun. 148(6):626-31.
- [67] Stolar CJ. What do survivors of congenital diaphragmatic hernia look like when they grow up?. *Semin Pediatr Surg.* 1996 Nov. 5(4):275-9.
- [68] Van Meurs K. Is surfactant therapy beneficial in the treatment of the term newborn infant with congenital diaphragmatic hernia?. *J Pediatr.* 2004 Sep. 145(3):312-6.
- [69] Weinstein S, Stolar CJ. Newborn surgical emergencies. Congenital diaphragmatic hernia and extracorporeal membrane oxygenation. *Pediatr Clin North Am.* 1993 Dec. 40(6):1315-33.
- [70] Wilcox DT, Irish MS, Holm BA, Glick PL. Pulmonary parenchymal abnormalities in congenital diaphragmatic hernia. *Clin Perinatol.* 1996 Dec. 23(4):771-9.
- [71] Wilson JM, Lund DP, Lillehei CW, Vacanti JP. Congenital diaphragmatic hernia--a tale of two cities: the Boston experience. *J Pediatr Surg.* 1997 Mar. 32(3):401-5.