



## Recurrent Pyogenic Granuloma

Munagala Karthik Krishna<sup>1</sup>, Lumbini Pathivada<sup>2</sup> and Deepali Jain<sup>3</sup>

<sup>1,3</sup>Department of Periodontology, Teerthanker Mahaveer Dental College and Research Centre, Moradabad, India.

<sup>2</sup>Department of Paedodontics, Teerthanker Mahaveer Dental College and Research Centre, Moradabad, India.

### ARTICLE INFO

#### Article history:

Received: 10 September 2016;

Received in revised form:  
5 November 2016;

Accepted: 17 November 2016;

#### Keywords

Epulis,  
Gingival enlargement,  
Hyperplasia,  
Pyogenic granuloma,  
Recurrent lesions.

### ABSTRACT

Pyogenic granuloma (PG) is a benign lesion of the oral cavity that presents as a solitary red or purple nodule. The routine treatment option for PG is excisional biopsy although the lesion may recur due to several factors such as residual tissue after excision or persistent etiologic factors. This case report presents a recurrent PG lesion in a 25-year old male with significant recurrence of swelling observed several months after excision. A combination procedure of excision and open flap debridement prevented further recurrence.

© 2016 Elixir All rights reserved.

### Introduction

Pyogenic granuloma (PG) is an 'inflammatory hyperplasia', a term commonly used to describe a group of enlargements of the oral mucosa that are characterized by fibrous and granulomatous tissue. It includes fibrous inflammatory hyperplasia, palatal papillary hyperplasia, giant cell granuloma, pregnancy epulis and PG [1,2]. Originally considered as an infection by pus-forming micro-organisms, it is now believed to be unrelated to infection but a hyperplastic tissue response to local irritation or trauma [3].

PG occurs commonly on the skin. Intra-orally, it is seen most frequently on the gingiva, with a higher prevalence in the maxilla. It has a female predilection and a high degree of occurrence is observed in the second decade of life. These lesions have tendency to involve the facial gingivae whereas some extend between the teeth and involve both the facial and lingual gingivae [4]. PG presents as a smooth or lobulated mass that is usually pedunculated, although some lesions are sessile. The color may vary depending on their age, ranging from young reddish granulomas to older, fibrous and pale lesions. Their size varies from a few millimeters to several centimeters in diameter [5].

Most lesions are painless in nature although exposure to secondary trauma such as during mastication may cause pain and ulceration. Because of their highly vascular nature, PGs have a tendency to bleed spontaneously or on slight provocation. Pyogenic granulomas may exhibit rapid growth which may create alarm for both the patient and clinician [3].

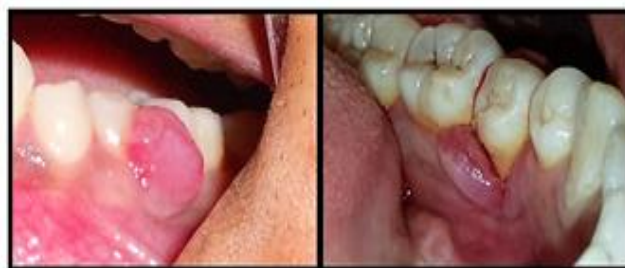### Case Report

A 25-year old male patient presented with the chief complaint of swollen and bleeding gums in his lower left back teeth region. The swelling was first noticed 5 months back and increased in size gradually. Patient appeared apparently healthy with no significant medical history.

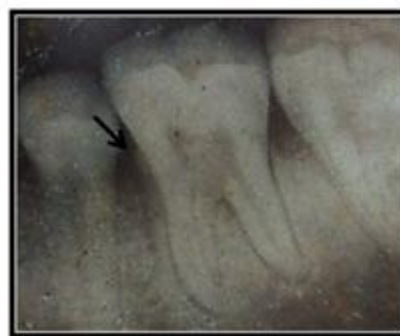
Intraoral examination revealed an enlargement of interdental gingiva in relation to the lower left second premolar and the first molar. The swelling extended onto the lingual aspect, hence resembling a 'dumb-bell' in shape.

The swelling was reddish, well-circumscribed, sessile, with a smooth and shiny surface (Figure 1). Patient complained of pain while mastication and occasional bleeding during brushing.

Radiological examination revealed flattening of the interdental alveolar bone, indicating mild bone loss (Figure 2). Based on the observed clinical findings a provisional diagnosis of pyogenic granuloma was given.



**Figure 1. Intra-oral buccal and lingual views of the growth in relation to interdental region of mandibular second premolar and first molar.**



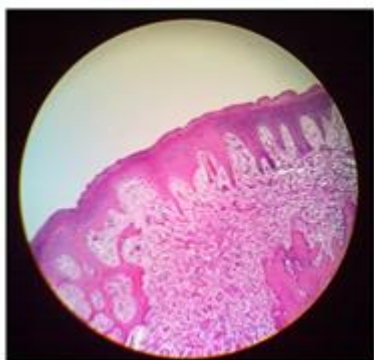
**Figure 2. Intra-oral periapical radiograph depicting interdental bone loss at the site of the lesion.**

Oral hygiene instructions were given and thorough scaling and root planning were carried out during the first visit.

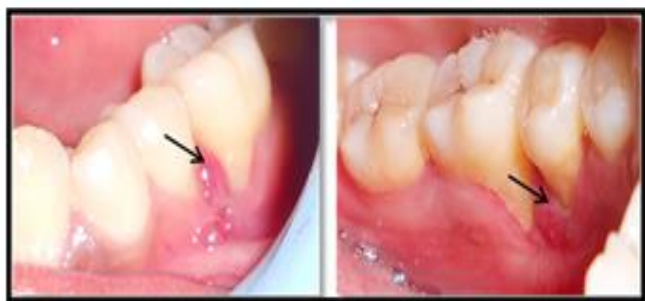The patient was prescribed a 0.2% chlorhexidine mouthrinse to be used twice daily and was recalled after one week. On examination in the recall visit, a noticeable reduction in the size of the lesion was observed and also the patient reported less discomfort during eating. It was decided to perform an excisional biopsy procedure during this visit for histopathological evaluation. The enlargement was excised with a Bard-Parker blade no.15 under local anesthesia. Patient was prescribed analgesics and recalled for regular monthly visits.

Stained section of the biopsy specimen revealed a parakeratinized stratified squamous epithelium overlying the connective tissue stroma. The connective tissue was dense and consisted of collagen fiber bundles alongwith fibroblasts, numerous young capillary vessels and inflammatory cells comprising mainly of plasma cells and lymphocytes (Figure 3).

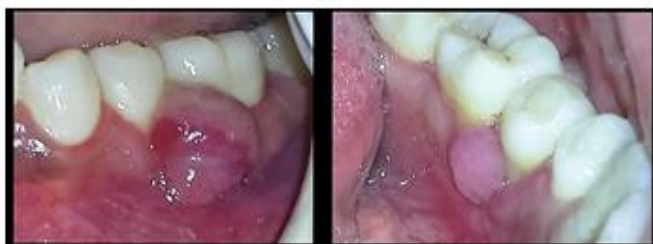Checkup during the first recall visit revealed reddish discoloration and mild overgrowth of the gingiva in the region of the excised tissue, suggesting recurrence (figure 4). Thorough root planning was done, oral hygiene instructions were reinforced and patient was recalled again after a month in the hope that the recurrence might regress. Patient failed to keep his recall appointment but reported after 6 months complaining of severe swelling in the same region. Intraoral examination revealed gingival overgrowth in the area, resembling the original lesion, but with ulceration on its surface suggesting trauma (Figure 5).



**Figure 3.** stained section showing dense fiber bundles, several capillary vessels and cells.



**Figure 4.** Mild recurrence of the lesion (black arrows) at the 1-month post-operative visit.



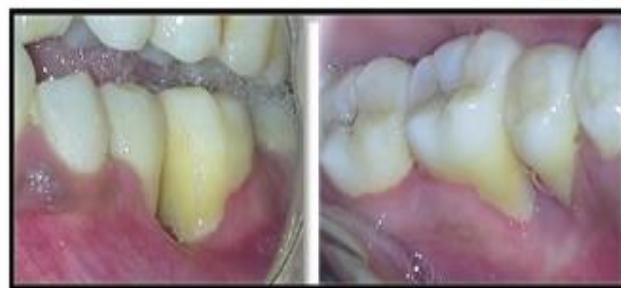**Figure 5.** Significant regrowth of the granuloma after 6 months.

After reviewing the case, a decision was made to perform surgical excision combined with open flap debridement (OFD). The growth was excised employing scalpel and electrocautery and flaps with sulcular incisions was reflected buccally and lingually. Granulomatous tissue was curetted and the root surfaces were thoroughly planed. Simple interrupted sutures were placed and the patient was prescribed antibiotics and analgesics. No subsequent recurrence was noted for a post-operative period of three months (Figure 6).

### Discussion

The term “pyogenic granuloma” or “granuloma pyogenicum” was introduced by Hartzell in 1904 [6]. However, now the term is considered as a misnomer as there is no formation of pus and it does not represent a true granuloma histologically. Although believed by some as a benign neoplasm, PG is widely regarded as a reactive lesion which occurs in response to stimuli such as a chronic low-grade local irritation, trauma or hormonal factors [7]. The associated gingival inflammation caused by plaque bacteria is non-specific and secondary instead of being the main etiology as was believed earlier [8].

Recurrence of PG may occur due to several causes such as incomplete excision leaving behind residual tissue resulting in regrowth, failure to detect and completely remove causative agents such as calculus or post-excision trauma of the area [9,10]. Some dermal cases of PG may occur as multiple satellite lesions mainly on torso and manifest as painless, reddish, intact papules.



**Figure 6.** Post-op view several months after flap surgery showing no signs of recurrence.

However, this phenomenon has rarely been reported in the oral cavity. The pathogenesis of satellitosis remains unclear, but there may be a relationship to an angiogenic factor elaborated by the primary lesion [11].

In the present case, recurrence of the lesion was evident 1 month after the excisional biopsy procedure. The decision for repeating excision combined with OFD was made with the objective of direct visual examination of the root surface for deposits and correction of any surface morphology favoring plaque re-accumulation. This approach allowed the detection of deep subgingival calculus deposits on the second premolar and their subsequent removal with root planing, thereby minimizing the chances of further recurrence of the lesion as was observed during subsequent recall visits.

### Conclusion

PG is a commonly occurring reactive lesion of the oral cavity. The recommended treatment for the lesion is surgical excision although recurrence may occur due to several factors, including incomplete removal of subgingival deposits. OFD may prove to a valuable add-on procedure after excision of PG for proper subgingival visualization and removal of calculus and minimize the chances of recurrence. Also, it is recommended that cases of PG be regularly followed-up to check for early signs of regrowth.

**References**

1. Greenberg MS, Glick M, Ship JA. Burket's Oral Medicine. 11 th Ed, BC Decker, Hamilton 2008:141-142.
2. Eversole LR, Rovin S. Reactive lesions of the gingiva. J Oral Path 1972; 1: 30-38.
3. Neville BW, Douglas DD, Allen CM, Bouquot JE. Oral and Maxillofacial Pathology. W.B. Saunders Company :447.
4. Saravana GHL. Oral pyogenic granuloma: a review of 137 cases. Br J Oral Max Surg 2009; 47(4):318-319.
5. Núñez G, Antonio M; Carvalho D, Benevenuto M, Gomes T; Lopes M, et al. Oral pyogenic granuloma: a retrospective analysis of 293 cases in a brazilian population. J Oral Max Surg 2010; 68(9):2185-2188.
6. Hartzell MB. Granuloma pyogenicum. J Cutan Dis Syph 1904; 22: 520-525.
7. Pearlman BA. An oral contraceptive drug and gingival enlargement; the relationship between local and systemic factors. J Clin Periodontol; 1974; 1: 47-51.
8. Vilmann A, Vilmann P, and Vilmann H. Pyogenic granuloma: evaluation of oral conditions. Br J Oral Max Surg 1986; 24(5): 376-382.
9. Ong MA, Chai WL, Ngeow WC. Recurrent gigantic pyogenic granuloma disturbing speech and mastication: a case report and literature review. Ann Acad Med Sing 1998;27(2):258-61.
10. Lee KH, Polonowita AD. A case of recurrent pyogenic granuloma. N Z Dent J 2007; 103(4):98-100.
11. Parisi E, Glick PH, Glick M. Recurrent intraoral pyogenic granuloma with satellitosis treated with corticosteroids. J Craniofac Surg 2011;22(6):2356-2358.