

## Pleomorphic Adenoma of Minor Salivary Gland of Hard palate: Case Report and Review

Sandeep Kaur<sup>1</sup>, Kirandeep Kaur<sup>2</sup> and Gurdeep Singh<sup>3</sup>

<sup>1</sup>Department of Oral Medicine & Radiology, Indira Gandhi Government Dental College & Hospital, Jammu (J&K), India.

<sup>2</sup>Department of Periodontology & Implantology, Jammu & Kashmir (J&K) - 180004, India.

<sup>3</sup>Department of Community medicine, Acharya shri chander college of medical sciences, Sidhra Jammu & Kashmir (J&K) - 180004, India.

### ARTICLE INFO

#### Article history:

Received: 5 April 2017;

Received in revised form:

3 May 2017;

Accepted: 13 May 2017;

#### Keywords

Pleomorphic adenoma

### ABSTRACT

Pleomorphic adenoma is a benign mixed tumor, which is composed of myoepithelial and epithelial cells. A fibrous capsule separates these cells from the surrounding tissues. Pleomorphic adenoma has unusual histopathologic features. It is the most common benign tumor affecting both major and minor salivary glands. Parotid salivary gland is affected mostly in the major group, and palate is the most common site affected in minor salivary glands. In this case report, a female patient aged 27 years who reported with a complaint of painless swelling in the right palate is presented.

© 2017 Elixir All rights reserved.

### Introduction

Pleomorphic adenoma is also called as benign mixed tumor. Minor salivary gland tumors are rare clinical entities, representing 10-25% of all the tumors of salivary glands.<sup>1</sup> Pleomorphic adenoma accounts for approximately 60% of all salivary gland neoplasms.<sup>2</sup> Palatal adenoma occurs mostly in the palate followed by upper lip and buccal mucosa.<sup>3</sup> Pleomorphic adenoma of the parotid gland may cause atrophy of the mandibular ramus. Intra-orally it may also occur at the floor of the mouth, retromolar area, and pharynx. This tumor is always mobile except when it occurs in the palate. Pleomorphic adenomas can occur at any age, even in the newborn.<sup>4</sup> However, patients in their fifth and sixth decades of life are commonly affected, and 60% of them are women. Malignant degeneration of this tumor is a potential complication. Here, a case of benign pleomorphic adenoma of the palate in a 27 years female patient is reported.

### Case Report

A 27 years old female patient named Madhubala, reported to the department of oral medicine and radiology with chief complaint of swelling over hard palate since 3 years. (Fig 1) Patient gives history of painless swelling which was small to start and progressive in nature and has reached the present size.

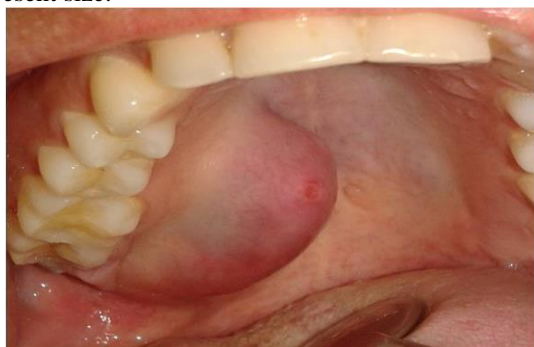

Fig 1. Intra oral view of swelling.

Patient had no relevant medical and family history. Intraoral examination revealed large swelling on the right side of hard palate around 3x4 cms in size, oval in shape extending from the marginal gingival of 13 upto 18 and maxillary tuberosity till the mid palatine region. The colour of overlying skin is normal to bluish. On palpation, swelling was sessile, non tender, firm to hard in consistency. The differential diagnosis of palatal abscess and hemangioma was given.

Fine needle aspiration cytology (FNAC) was done using 2ml syringe. Cytology smear shows clusters and scattered round to oval cells with regular nuclei and tiny fragments of stroma suggestive of Pleomorphic adenoma.

Occlusal radiograph revealed no bony erosion of the palate. (Fig 2) Plain CT PNS & PALATE report showed both maxillary sinuses are clear and patent ostia, bony wall intact. No mass lesion observed. Sphenoid ethmoid sinuses clear. No breach in Cribiformplate. Nasal Bones intact. Nasal Septum intact and deviated to right side. No mass lesion seen in nasal cavity and nasopharyngeal region. Inferior Nasal turbinates revealed mucosal hypertrophy. Hiatus Semilunaris compromised on both sides. Uncinate processes are normal. Lobulated irregular soft tissue attenuation value (+51to+62HU) mass is seen in relation to the soft palate.

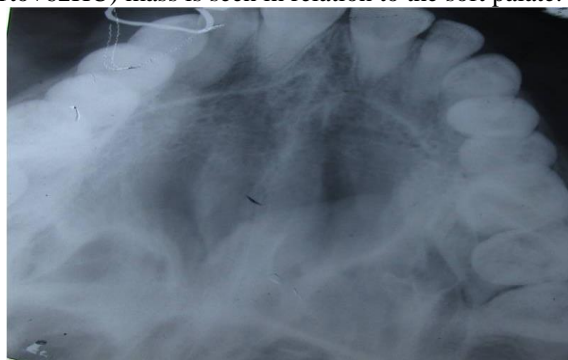

Fig 2. Occlusal Radiograph.

The hard palate & other neighbouring osseous structures are not eroded by the mass. Pterygoid plates are intact on both sides. Both Orbits show normal intraorbital contents. (Fig 3,4&5) The patient was referred to oral surgery department for wide excision of the tumor under general anaesthesia.

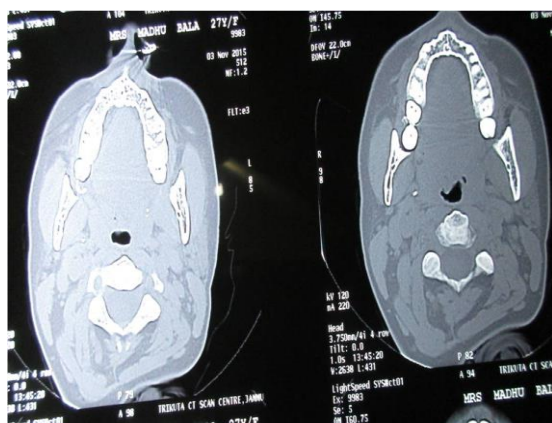
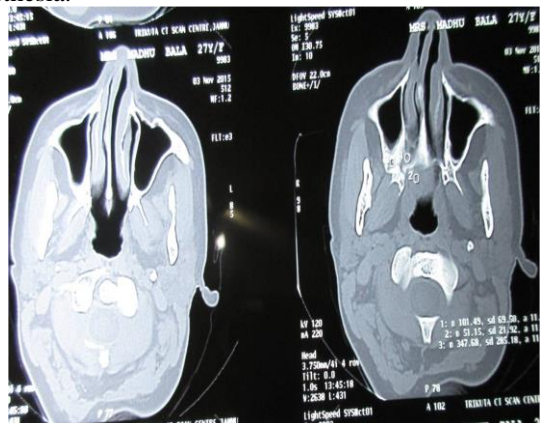
Figure 3&4. Axial Plain CT PNS scan.

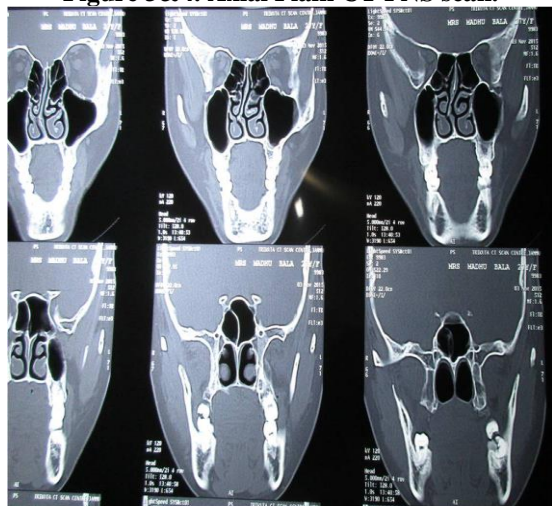


Figure 5. Coronal CT scan.

## Discussion

Tumours arising in the minor salivary glands account for upto 22% of all salivary gland neoplasm<sup>4,5,6,7</sup>. Majority are malignant with only 18% being benign. The commonest site of occurrence of pleomorphic adenomas of minor salivary glands is the palate followed by lip, buccal mucosa, floor of the mouth, tongue, tonsil, pharynx, retromolar area and nasal cavity<sup>4,6,7</sup>.

Pleomorphic adenomas involving minor salivary glands are painless and slow growing ones. Sometimes the growth rate could be fast.

Rapid increase in size of the mass should lead to suspicion of intra lesional bleed / malignant transformation. The term pleomorphic adenoma is used to indicate the histological presence of both epithelial and mesenchymal tissues. Histological features of pleomorphic adenoma shows islands of spindle cells over myxoid background, inner layer of epithelial cells and outer layer of myoepithelial cells.

Imaging helps in ruling out palatal erosion. In all radiological images of these lesions one should look out for the presence of intact fat plane the presence of which rules out malignancy.<sup>8</sup> Sialography demonstrates displacement of the ducts around the benign tumor which itself is well delineated with definitive margins (ball-in-hand appearance). CT shows a similar picture, with a higher degree of attenuation within the tumor mass that demonstrate homogeneous density. A lobulated appearance is also not unusual. The margins may appear vague if there is associated inflammation or hemorrhage. Differentiation from a malignant lesion becomes difficult. Occasionally, the mass appears with lower attenuation similar to cyst. A mixed appearance is also noted if cystic change or necrosis exist. MRI, on the other hand, can clearly demonstrate the benign nature of the lesion with distinct margins as it aids in determining the extent and nature of the lesion, local spread and also the neoplastic status.<sup>9,10</sup> The tumours involving the soft palate and the adjoining areas especially the parapharyngeal space are also known to arise as an extension from the deep lobe of the parotid gland. Such tumours have to be distinguished from those arising de novo. This can be differentiated by a distinct fine lucent line representing the compressed layer of fibro adipose tissue between the tumour and the deep lobe of parotid when seen on a MRI scan.<sup>9</sup>

The treatment of choice for pleomorphic adenoma should be wide local excision with the removal of periosteum or bone if they are involved. Simple enucleation of this tumor may lead to high recurrence rate and should be avoided.<sup>11</sup>

These tumours are encapsulated and hence complete removal ensures cure. Care should be taken to leave at least 1mm margins around the lesion. While removing the mass rupture of the capsule is to be avoided to minimize recurrence. Palatal reconstruction is considered in cases of large palatal defects arising after surgical excision in very aggressive tumors. In the present case, patient did not require any reconstruction of the palate as the bony invasion was minimal which lead to regeneration of the palatal mucosa without any fistula formation

## Conclusion

Since the majority of malignant neoplasms arise from minor salivary glands, it is therefore advised to evaluate the patient, note the detailed history and investigate the case radiographically and histopathologically. Imaging helps in ruling out bone erosions in these patients. Complete extirpation of the mass is curative. One word of caution is that capsule should not be breached when attempting to surgically remove the mass because breach of capsule is associated with increasing recurrence rates.

## References

1. Sourav Sharma. Pleomorphic Adenoma of Hard Palate: A Case Report and Review of Literature. IJSS Case Reports & Reviews 2015 ;1 ( 12):12-14.
2. Yadavalli Guruprasad. Pleomorphic Adenoma of Hard Palate. Archives of Dental Sciences.2010; Vol.1 Issue 1 ; 73-74.

3. Balasubramania Thiagarajan. Pleomorphic adenoma hard palate a case report and literature review. *Rhinology* 2013; 26(3):1-4.
4. Spiro SH. Salivary Neoplasm: overview of a 35 years experience with 2807 patients. *Head Neck Surg*, 1986; 8(3):177–184.
5. Waldron CA, el-Mofty SK, Gnepp DR. Tumours of the intra-oral salivary glands: A demographic and histologic study of 426 cases. *Oral Surg Oral Med Oral Pathol* 1988; 66(3):323–333.
6. Cohen MA. Pleomorphic adenoma of the cheek. *Int J Oral Maxillofac Surg* 1986;15(6): 777–779.
7. Varghese BT, Sebastian P, Abraham EK, Mathews A. Pleomorphic adenoma of minor salivary gland in the parapharyngeal space. *World J Surg Oncol* 2003; 1(1): 2
8. Hakeem AH, Hazarika B, Pradhan SA, Kannan R. Primary pleomorphic adenoma of minor salivary gland in the parapharyngeal space. *World J surg Oncol* 2009; 7:85
9. Heeneman H (1987) Parapharyngeal space tumours. Kerr AG, editor. *Scott Brown's Otolaryngology*. Butterworth & Co, 380–391.
10. Som PM, Bergen RT (1991) *Head and neck imaging* 2nd edn. St Louis, Mosby 277–348.
11. Ogata H, Ebihara S, Mukai K. Salivary gland neoplasms in children. *Japan J Clin Oncol* 1994;24:88-93.