

## Penile Metastasis of Right Colon Adenocarcinoma: A Rare Case Report and Review of the Literature.

Hicham El Bote<sup>1</sup>, Sihem Atik<sup>2</sup>, Fatine Ouiazza<sup>3</sup>, Rami Fares<sup>4</sup>, Montembault Sarah<sup>5</sup>, Irimescu Daniela<sup>6</sup> and Thelu Francoise<sup>6</sup>

<sup>1</sup>Department of Urology A, Ibn Sina University Hospital, Rabat, Morocco.

<sup>2</sup>Department of Medical Oncology, Central Hospital of army, Algiers, Algeria.

<sup>3</sup>Department of Gastro-enterology, Ibn Sina University Hospital, Rabat, Morocco.

<sup>4</sup>Department of Urology, Hospital Center of Soissons, France.

<sup>5</sup>Department of Oncology, Hospital Center of Soissons, France.

<sup>6</sup>Pathologie Nord-Unilabs laboratory of Lille, France.

### ARTICLE INFO

#### Article history:

Received: 24 March 2017;

Received in revised form:

19 April 2017;

Accepted: 27 April 2017;

#### Keywords

Penile,

Metastasis,

Right colon adenocarcinoma.

### ABSTRACT

We report the case of a 86-year-old man with previously diagnosed an adenocarcinoma of the right colon with metastasis to the penis. The patient underwent right hemicolectomy with negative margins and completed 12 cycles of adjuvant chemotherapy with Oxaliplatin and a Fluoropyrimidine (FOLFOX IV). Two years later after the surgery, the patient presented tumoral progression and apparition of multiple metastases on liver and peritoneal carcinosis, the patient is since on supportive and palliative care. Few months later the clinical examination showed an indurated lesion of glans penis, whose resection was consistent with metastatic colon adenocarcinoma.

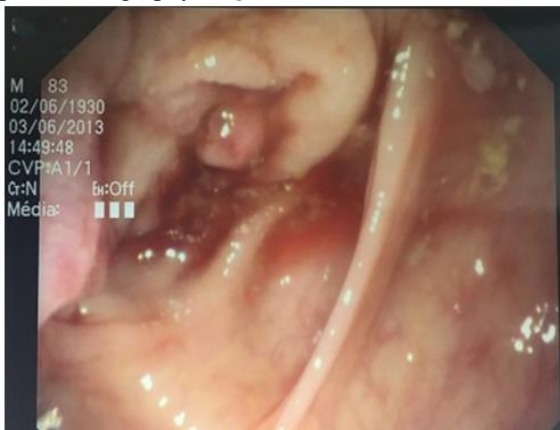© 2017 Elixir All rights reserved.

### Introduction

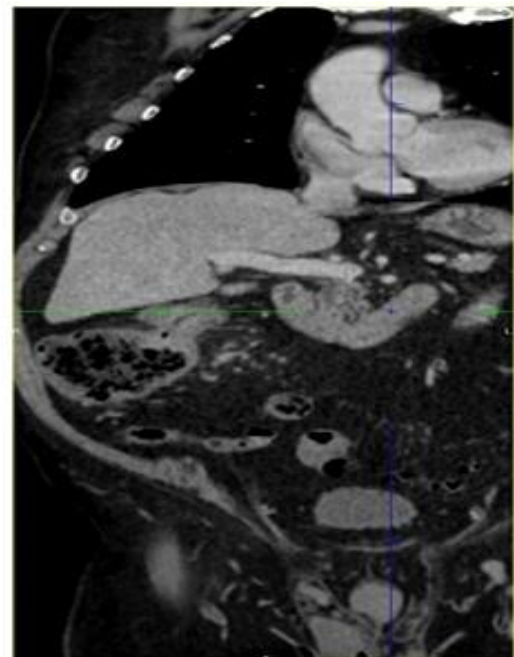
Metastatic involvement of the penis is a rare disease; the majority of metastases originate from adjacent urogenital organs. The prognosis remains very poor, as it typically indicates a disseminated malignancy. The treatment options are usually local tumour excision, partial or total penectomy, external beam radiation therapy, brachytherapy or chemotherapy. We present the case of metachrone penile metastasis of right colon adenocarcinoma.

### Case presentation

An 86-year-old man with any comorbidity was admitted for a mass of the glans penis. Four years earlier, the patient presented with pain and lump abdomen caused by right colon neoplasm diagnosed by colonoscopy (Figure 1) and computed tomography (Figure 2).



**Figure 1.** Colonoscopy: Annular and obstructive tumor of the right colon.

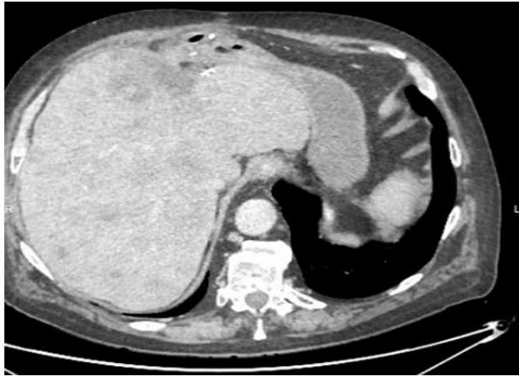

**Figure 2.** Coronal tomography view showing the right colon cancer.

Right hemicolectomy was performed. Pathohistological analysis revealed a Liberkuhnian adenocarcinoma undifferentiated, the tumor invaded all the bowel wall and was perforated, with positive lymph nodes and the presence of vascular and perineural invasion. Resection margins were negative (pT4N2M0 R0). The patient underwent 12 cycles of

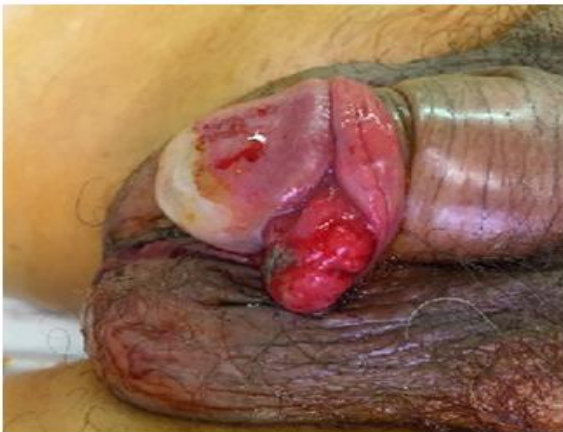adjuvant chemotherapy with Oxaliplatin and a Fluoropyrimidine (FOLFOX IV).

Two years later after the initial procedure, the patient presented a tumoral progression and apparition of multiple metastases on liver and peritoneal carcinosis (*Figure 3*) treated with a systemic chemotherapy, the patient is since on supportive and palliative care.



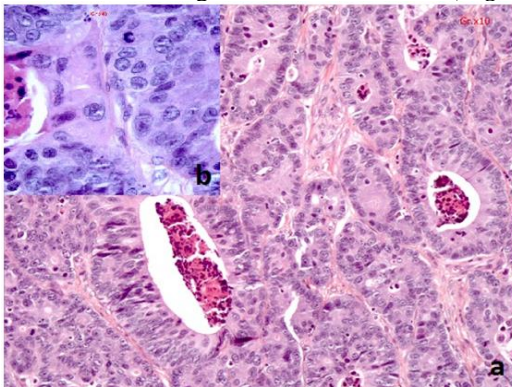
**Figure 3.** Cross-sectional tomography view showing multiple metastases on liver.

Few months later the clinical examination showed an indurated and painful lesion of glans penis on balanopreputial groove (*Figure 4*).

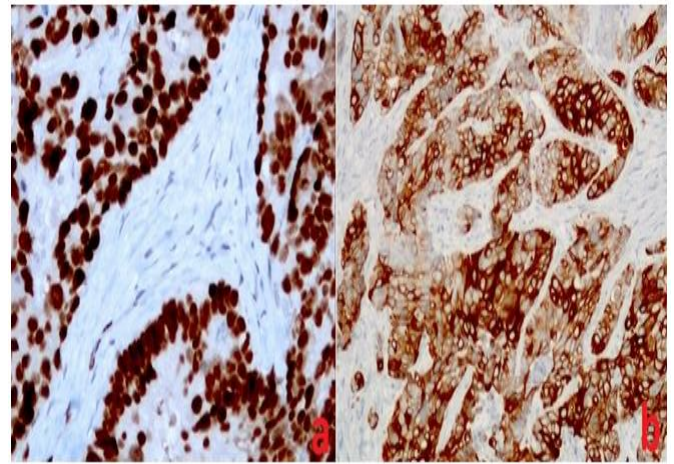


**Figure 4.** Tumor of glans penis on balanopreputial groove.

The pathohistological study of local excision revealed metastatic of adenocarcinoma indicating metastasis from the right colon adenocarcinoma (*Figure 5*). Immunohistochemical study demonstrated positive staining of the tumor cells for carcino-embryonic antigen [CEA], CK20 and CDX2 and negative for P63, CK5/6, PSA, TTF1 in favor of metastasis of gastro-intestinal tractus (*Figure 6*).



**Figure 5.** Microscopic analysis of the nodule of glans penis showing metastatic adenocarcinoma. (HES Coloration; a  $\times 10$ , b  $\times 40$ ).



**Figure 6.** Immunohistochemically the malignant cells were positive for CDX20 (a) and Cytokeratin 20 (b).

### Discussion

Despite the rich blood supply to the penis, metastatic carcinoma to the penis is rare and most often associated with disseminated malignancy and have a poor prognosis [1-2]. The most common tumor to metastasize to the penis is bladder cancer, prostate (30%), gastrointestinal (21%), kidney (11%) and lung (4%) [2-3]. Fewer than 60 cases of penile metastasis from colon cancer have been reported [4]. The exact mechanism of spread is unknown. A number of mechanisms of metastasis have been suggested including direct tumor extension, retrograde venous spread, and arterial, lymphatic spread [5].

In order of frequency, presenting symptoms of penile metastasis are: malignant priapism (40%), penile nodules, ulceration, perineal pain, urinary retention, edema, generalized swelling, broad infiltrative enlargement, dysuria and hematuria [6].

Ultrasound and computed tomography can be used in the evaluation of penile lesions. Magnetic resonance imaging has a superior soft tissue contrast to assess the extent of penile metastasis and it allows an appropriate staging before surgery [7].

Positron emission tomography is also useful for detection of clinically silent metastatic sites in hypermetabolic cancer [8].

Anatomopathological examination and immunohistochemical study are necessary to confirm diagnosis and determine the primary tumor site.

We have to differentiate penile metastasis from primary penile cancer, chancre, chancroid, Peyronie's disease, tuberculosis and other inflammatory and suppurative diseases [9].

The treatment depends on the performance status and primary cancer state of the patient. Treatment modalities include local excision, penectomy, chemotherapy, brachytherapy and radiotherapy [10].

Penile metastatic lesion represents the advanced form of tumoral progression, approximately half of the patients died of their disease within 1 year of the diagnosis of penile metastasis [11].

### Conclusion

Penile metastasis from colon cancer is extremely rare. The mechanism of dissemination is still unclear. It is frequently associated with widespread metastatic disease and poor prognosis. Complete excision is palliative treatment in case of solitary and distal nodule.

**Conflict of Interests**

The authors declare that there is no conflict of interests regarding the publication of this paper.

**References**

1. Chau A, Amin M, Cubilla AL, et al. Metastatic tumors to the penis: a report of 17 cases and review of the literature. *Int J Surg Pathol.* 2011;19:597–606.
2. Zhu YP, Yao XD, Zhang HL, et al. Penile metastasis from primary bladder cancer: a study of 8 cases and review of the literature. *Onkologie.* 2012;35:196–199.
3. Cardoso Guimarães G, Rodrigues De Souza R, Paiva Gadêlha Guimarães A, et al. Penile metastasis of chondrosarcoma of the jaw. *Urology.* 2003;61:837.
4. Ji CP, Wook HL, Min KK, et al. Priapism secondary to penile metastasis of rectal cancer. *World J Gastroenterol.* 2009 Sep 7; 15(33): 4209–4211.
5. Chan PT, Begin LR, Arnold D, et al. Priapism secondary to penile metastasis: a report of two cases and a review of the literature. *J Surg Oncol* 68: 51-59, 1998.
6. Burgers JK, Badalament RA, Drago JR. Penile cancer. Clinical presentation, diagnosis, and staging. *Urol Clin North Am* 1992; 19: 247-256
7. Singh AK, Gonzalez-Torrez P, Kaewlai R, Tabatabaei S, Harisinghani MG. Imaging of penile neoplasm. *Semin Ultrasound CT MR* 2007; 28: 287-296
8. Pai A, Sonawane S, Purandare NC, Rangarajan V, Ramadwar M, Pramesh CS, Mistry RC. Penile metastasis from esophageal squamous carcinoma after curative resection. *Ann ThoracCardiovascSurg*2008; 14: 238-241
9. Abeshouse BS, Abeshouse GA. Metastatic tumors of the penis: a review of the literature and a report of two cases. *J Urol*1961; 86: 99-112
10. Mukamel E, Farrer J, Smith RB, deKernion JB. Metastatic carcinoma to penis: when is total penectomy indicated? *Urology* 1987;29:15-8.
11. Ke Z, Jun D, Hai-jun Y, et al. Metastatic Tumors of the Penis A Report of 8 Cases and Review of the Literature. *Medicine (Baltimore).* 2015 Jan; 94(1): e132.