

## Infected Urachal Cyst: Case Report

Abdelouahed Lasri, Slaoui Amine, Yddoussalah Othmane, Tarik Karmouni, Khalid Elkhader, Abdellatif Koutani and Ahmed Ibn Attya Andaloussi

Department of Urology B – Ibn Sina Hospital - Faculty of medicine and pharmacy of Rabat – Mohammed V University

### ARTICLE INFO

#### Article history:

Received: 6 March 2017;

Received in revised form:  
29 May 2017;

Accepted: 10 June 2017;

#### Keywords

Pathology of the Urachus,

Urachal cyst,

Antibiotics,

Surgical excision.

### ABSTRACT

Urachal cyst is one of a spectrum of urachal abnormalities most commonly found in children. But it is a rare pathologic disease entity in the adult, which may present only with abdominal pain. We describe a case of a 49 year old male who presented with abdominal pain, fever and dysuria. Diagnosis of an infected urachal cyst was confirmed on Computed tomography of the pelvis. He was treated initially with broad spectrum antibiotics in order to allow sepsis to resolve prior to surgical excision of the cyst and fibrous tract. Histology of the excised specimen showed chronic inflammation with no evidence of malignancy. Postoperative recovery was uneventful. Urachal abnormalities are rare in adults. Clinical presentation is non-specific and must be considered as a rare differential for abdominal pain, when diagnosed, surgical excision is advised because of the risk of malignant transformation.

© 2017 Elixir All rights reserved.

### Abbreviation

UC, Urachal cyst.

### Introduction

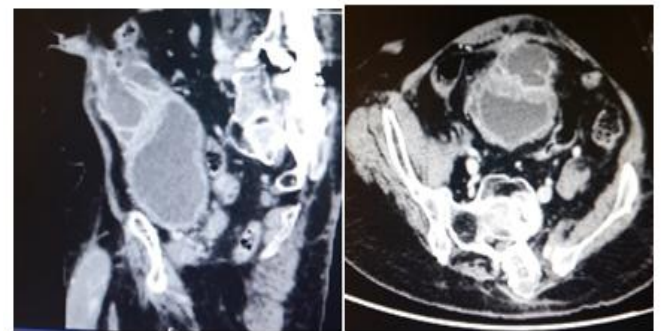
Urachal abnormalities result from incomplete regression of the foetal urachal. They are more common in children than in adults, due to urachal obliteration in early infancy [1]. In adults, urachal cyst (UC) is the commonest variety, with infection being the usual mode of presentation [2]. Diagnosis remains challenging due to the rarity of this lesion and the non-specific nature of its symptomatology.

We report a case of urachal cyst presenting with abdominal pain and fever.

### Observation

Mr. M.A, a 49-year-old patient, had a history of epileptic disease and mental retardation, a spinal osteosynthesis for spinal deformity. Presented to the emergency with fever, increasing abdominal distension, abdominal pain, and dysuria. Physical examination revealed a temperature of 38.8°C, pulse rate of 100 beats/min, respiratory rate of 28 breaths/min, blood pressure 128/67 mm Hg. He had a firm abdomen in the periumbilical region with tenderness but without other peritoneal signs. There was a nonfluctuant mass at the suprapubic area measuring 10 cm. There was no erythema or bruises in this area and no discharge from the umbilicus. His bowel sounds were normal. Hematology showed a raised C-reactive protein of 189 mg/l, WBC count is  $15.8 \times 1000/\text{ml}$ . Urine was sterile at the culture. Computed tomography of the pelvis revealed a 10 x 8 cm fluid collection, immediately above the bladder, which extended up to the region of the rectus muscle. This was associated with a very thickened bladder wall without any communication between. (Figure 01)

The patient was initially treated with intravenous antibiotics accompanied by percutaneous drainage followed by a 2 week course of oral antibiotics with surgical excision planned at the end of this period.



**Figure 1. CT abdo/pelvis showing a large inflammatory mass right of midline inseparable from the rectus sheath and bladder.**

There were no postoperative complications, and Histopathological analysis of the resected specimen showed chronic inflammation with no evidence of malignancy.

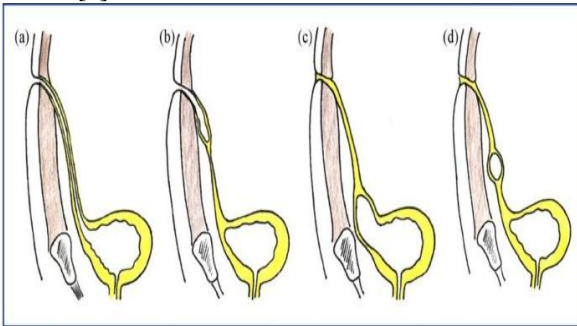
### Discussion

The urachus, developmentally is the upper part of the bladder, both of which arise from the ventral part of the cloaca [3]. Descent of the bladder from the 5th month of development into the foetal pelvis pulls the urachus with it resulting in the formation of the urachal canal. The lumen of this canal progressively obliterates during foetal life, with eventual formation of a fibrous tract in early adult life.

At the end of development, the urachus lies between the transverse fascia anteriorly and the peritoneum posteriorly (space of Retzius), surrounded by loose areolar tissue attaching the umbilicus to the bladder dome, being 3–10 cm in length and 8–10 mm in diameter.

Histologically, it is composed of 3 layers; an innermost layer of modified transitional epithelium similar to urothelium, a middle fibroconnective tissue layer and an outer layer of smooth muscle continuous with the detrusor [1,3].

Urachal remnants can present as one of four primary recognized pathologies; patent urachus, urachal sinus, vesicourachal diverticulum, and urachal cyst. Patent urachus involves free communication between the bladder and the umbilicus, and presents with urine leakage through the umbilicus or occasionally with a urinary tract infection. Urachal sinus and vesicourachal diverticulum are variations in incompletely patent connections, the former communicates with the umbilicus, but not the bladder. Conversely, a vesicourachal diverticulum communicates between the urachus and the bladder, but not with the umbilicus. Urachal cysts are the last and most common type of urachal anomalies [4].



**Types of urachal anomalies: (a) patent urachus, (b) urachal sinus, (c) urachal diverticulum, (d) urachal cyst**

The incidence of UC in adults is unknown but it is rare. It is more common in men than women [5, 6]. In a 31-year review, Risher et al [5], found 12 adults with urachal anomalies, of which 5 were UC. Modes of presentation of urachal anomalies in adults differ from those seen in children. In adults, the commonest variety is urachal cyst, with infection being usual mode of presentation [5, 7]. The route of infection is haematogenous, lymphatic, direct or ascending from the bladder. The commonly cultured microorganisms from the cystic fluid include *Escherichia coli*, *Enterococcus faecium*, *Klebsiella pneumoniae*, *Proteus*, *Streptococcus viridans* and *Fusobacterium* [6, 7]. In our case, *Bacteroides sp* was cultured.

Patients with infected urachal cysts can present with a wide range of symptoms, most commonly abdominal pain, fever, umbilical discharge and the feeling of a midline mass. Owing to the low incidence and heterogeneous presentation patients can be misdiagnosed [8].

History taking, a detailed clinical exam, and computed tomography may aid in raising clinical suspicions. Ultrasound scan can help to make diagnosis in 77% of patients [6]. In our case, ultrasound scan was not specific and CT scan was used to make both diagnosis and define its relationship to surrounding structures.

UC can be complicated by rupture into the peritoneal cavity leading to peritonitis. Other reported complications include uracho-colonic fistula, stone formation and neoplastic transformation [9-10].

The differential of urachal abscess should include hematoma, urachal carcinoma, sarcoma of the abdominal wall, peritoneal tumor, metastatic carcinoma, ventral or umbilical hernia, and inflammatory lesions [11, 12, 13].

Appropriate treatment includes antibiotics, percutaneous drainage, and eventual surgical excision because of the high incidence of recurrences.

Traditionally, open excision has been the approach of choice, however, a laparoscopic approach is also an attractive alternative [14, 15], in cases where a pre-operative diagnosis has been made, a staged approach with antibiotics followed by surgery has been recommended [3, 16].

## Conclusion

Urachal anomalies are rare in adults. Presentation is atypical; it should be considered in the differential of abdominal pain to ensure timely and appropriate management. Ultrasound and Computed tomography are the gold standard diagnostic tools for suspected cases of urachal lesions. Complete surgical excision is the treatment of choice due to the risk of malignant transformation. Urologists should remain the masters of the diagnostic and therapeutic approach of these pathologies. Gradually, new imaging techniques and laparoscopy must be integrated in the clinical practice.

## Conflict of Interests

The authors declare no conflict of interest.

## Authors Contribution

All authors mentioned have contributed to the development of this manuscript. All authors also declare to have read and approved the final manuscript.

## References

1. Hammond G, Yglesias L, Davis JE: The urachus, its anatomy and associated fascia. *Anat Rec* 1941, 80:271-274.
2. Risher WH, Sardi A, Bolton J: Urachal abnormalities in adults: the Ochsner experience. *South Med J* 1990, 83:1036-1039.
3. Begg RC: The Urachus: its Anatomy, Histology and Development. *J Anat* 1930, 64:170-183.
4. Goldberg R, Pritchard B, Gelbard M. Umbilical inflammatory conditions: Case report and differential diagnosis. *J Emerg Med.* 1992 Mar-Apr; 10(2):151-1566.
5. Risher WH, Sardi A, Bolton J: Urachal abnormalities in adults: the Ochsner experience. *South Med J* 1990, 83:1036-1039.
6. Ashley RA, Inman BA, Routh JC, Rohlinger AL, Husmann DA, Kramer SA: Urachal anomalies: a longitudinal study of urachal remnants in children and adults. *J Urol* 2007, 178:1615-1618.
7. Yoo KH, Lee SJ, Chang SG: Treatment of infected urachal cysts. *Yonsei Med J* 2006, 47:423-427
8. Ash A., Gujral R., Raio C. Infected urachal cyst initially misdiagnosed as an incarcerated umbilical hernia. *Journal of Emergency Medicine.* 2012; 42:171-173
9. Flanagan DA, Mellinger JD: Urachal-sigmoid fistula in an adult male. *Am Surg* 1998, 64:762-763.
10. Mazzucchelli R, Scarpelli M, Montironi R: Mucinous adenocarcinoma with superficial stromal invasion and villous adenoma of urachal remnants: a case report. *J Clin Pathol* 2003, 56:465-467
11. Hsu CC, et al. Urachal cyst a cause of adult abdominal pain that cannot be ignored. *Am J EM* 2005; 23, 299-230
12. Hale JA, Calder IM. Synovial sarcoma of the abdominal wall. *BR J Cancer.* 1970; 24:471.
13. Yeh HC, Rabinowitz JG. Ultrasonography and computed tomography of inflammatory abdominal wall lesions. *Radiology* 1982; 144:85
14. Groot-Wassink T., Deo H., Charfare H., Foley R. Laparoscopic excision of the urachus. *Surgical Endoscopy.* 2000; 14:680-681.
15. Janes V.A., Hogeman P.H., Achten N.B., Tytgat S.H. An infected urachal cyst—a rare diagnosis in a child with acute abdominal pain. *European Journal of Pediatrics.* 2012; 171: 587-588.
16. Ekwueme K.C., Parr N.J. Infected urachal cyst in an adult: a case report and review of the literature. *Cases Journal.* 2009; 2:6422.