

The Buschke-Löwenstein tumor

Youssef Kadouri and Idriss Ziani

Department of Urology A, Ibn Sina Hospital, CHU Rabat, Morocco

ARTICLE INFO

Article history:

Received: 10 July 2017;

Received in revised form:

3 September 2017;

Accepted: 16 September 2017;

Keywords

Buschke-Löwenstein tumor,
Giant Acuminate Condyloma.

ABSTRACT

The Buschke-Löwenstein tumor (TBL) or giant acuminate condyloma (GAG) is a pseudo-epitheliomatous proliferation belonging to the group of verrucous carcinomas. Its first description dates back to 1896. It was in 1925 that Buschke and Löwenstein made it a characteristic entity. It is of viral origin (HPV), of sexual transmission reaching mainly the ano-genital zones. It is characterized by its degenerative potential and its recurrence after treatment. TBL is a relatively rare condition and always preceded by condylomata acuminata, its annual incidence appears to be 0.1% among the sexually active adult population. It occurs at any age after puberty and predominates between the 4th and 6th decades. The infection can reach both sexes, it is frequently seen in the male sex. The development, persistence and recurrence of condylomas largely reflect the immune status of the host. Immunosuppression, chronic inflammation, lack of hygiene and HIV infection appear to be risk factors for this condition. The implication of the papillomavirus and in particular of its serotypes HPV 6 and 11 is accepted in the genesis of the TBL. Its prevention is imperative based on the treatment of condylomata acuminata and the fight against sexually transmitted diseases. The treatment must be early, it is essentially surgical requiring a wide excision. We report the case of a 55-year-old patient with a history of sexual vagrancy and repeated urethritis who consults for a penile tumor that has been evolving for 8 years. The clinical examination noted several infiltrated tumor lesions, cauliflower papillomatous lesions of the root and ventral surface of the penis, fetid and painless. The ganglionic areas were free. HIV, syphilitic and hepatitis B and C serology were negative. Treatment consisted of surgical excision with skin covering adjacent to the skin. The histological examination of the excision piece revealed an important papillomatous hyperplasia of the epidermis and some koilocytes in favor of a giant condyloma. After 2 years of retreat, we did not find any recurrence.

© 2017 Elixir All rights reserved.

Introduction

Medical Image

The Buschke-Löwenstein tumor (TBL) or giant acuminate condyloma (GAG) is a pseudo-epitheliomatous proliferation belonging to the group of verrucous carcinomas. Its first description dates back to 1896. It was in 1925 that Buschke and Löwenstein made it a characteristic entity.

It is of viral origin (HPV), of sexual transmission reaching mainly the ano-genital zones. It is characterized by its degenerative potential and its recurrence after treatment. TBL is a relatively rare condition and always preceded by condylomata acuminata, its annual incidence appears to be 0.1% among the sexually active adult population. It occurs at any age after puberty and predominates between the 4th and 6th decades.

The infection can reach both sexes, it is frequently seen in the male sex.

The development, persistence and recurrence of condylomas largely reflect the immune status of the host. Immunosuppression, chronic inflammation, lack of hygiene and HIV infection appear to be risk factors for this condition. The implication of the papillomavirus and in particular of its serotypes HPV 6 and 11 is accepted in the genesis of the TBL. Its prevention is imperative based on the treatment of

condylomata acuminata and the fight against sexually transmitted diseases.

The treatment must be early, it is essentially surgical requiring a wide excision.

We report the case of a 55-year-old patient with a history of sexual vagrancy and repeated urethritis who consults for a penile tumor that has been evolving for 8 years.

The clinical examination noted several infiltrated tumor lesions, cauliflower papillomatous lesions of the root and ventral surface of the penis, fetid and painless.

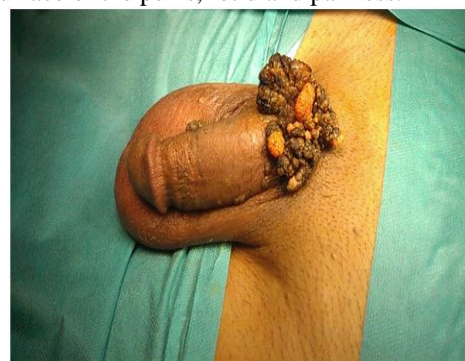


Figure 1: Buschke-Löwenstein tumor: kerato-verrucous cauliflower lesion at the root of the rod.

The ganglionic areas were free. HIV, syphilitic and hepatitis B and C serology were negative.

Treatment consisted of surgical excision with skin covering adjacent to the skin. The histological examination of the excision piece revealed an important papillomatous hyperplasia of the epidermis and some koilocytes in favor of a giant condyloma. After 2 years of retreat, we did not find any recurrence.

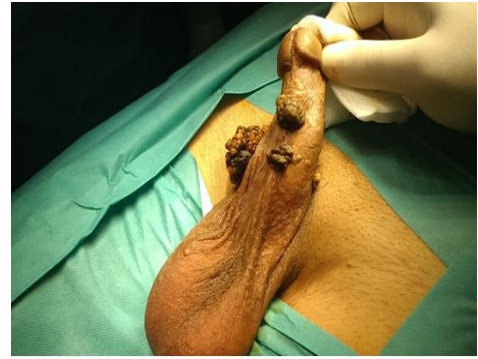

Figure 2: Buschke-Lowenstein tumor: kerato- verrucous cauliflower lesions on the ventral surface of the penis.