



Axillary Aneurysm Due to Behcet's Disease Revealed by Nerve Compression

T.Madani¹, D.Jeddi¹, T.Grimi¹, M.A.Bardouni¹, MS.berrada¹, O.Zahdi² and Y.Bensaid²

¹Department of Orthopaedic surgery and Traumatology, Ibn Sina hospital, Rabat, Morocco.

²Department of vascular surgery, Ibn Sina hospital, Rabat, Morocco.

ARTICLE INFO

Article history:

Received: 06 November 2017;

Received in revised form:
20 April 2018;

Accepted: 1 May 2018;

Keywords

Aneurysm,
Behcet,
Compression.

ABSTRACT

Aneurysms of the axillary artery are rare, most often they are pseudo-aneurysms of post-traumatic origin, The pathophysiology of aneurysms in Behcet's disease remains poorly understood and rare in axillary localization. We report the case of a patient who consults for signs of nerve compression of the left upper limb due to an axillary aneurysm, the patient suffers also of Behcet's disease, the revealing mode of the aneurysm and the rarity of this complication prompted us to report this interesting observation.

© 2018 Elixir All rights reserved.

Introduction

Aneurysms of the axillary artery are dominated in adults by closed trauma and wounds, most often they are pseudo-aneurysms of post-traumatic origin, true aneurysms are rare. We report the case of a patient who consults for signs of nerve compression of the left upper limb due to an axillary aneurysm, the patient suffers also of Behcet's disease

Materials and methods

We report the case of a 44-year-old patient with a history of Behcet's disease since adolescence, who consulted in orthopedic surgery unit for paresthesia of the left upper limb with amyotrophy of the thenar and hypothenar eminence that had been evolving for 6 months without concept of trauma.

An electromyogram, revealed a block of conduction. Diagnosis of axillary artery aneurysm was confirmed by echodoppler findings and CT angiography, which showed the existence of an aneurysm of the left axillary artery (Figure A and B).

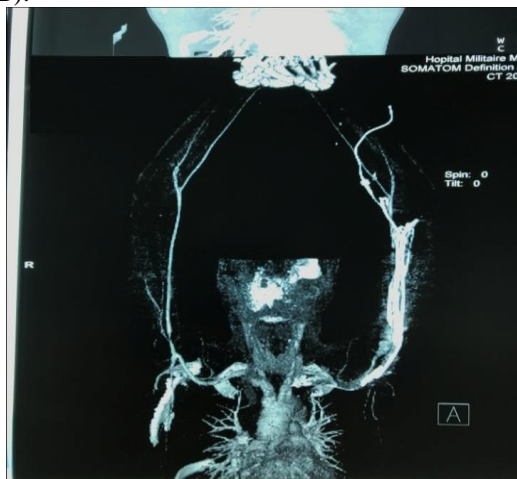


Figure A. CT angiography: axillary aneurysm of left upper limb.

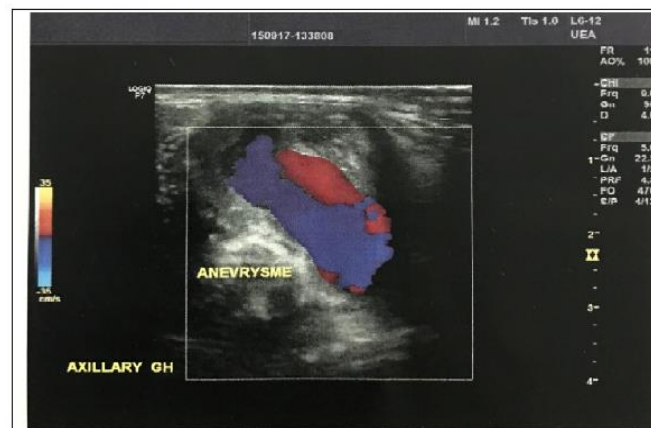


Figure B. ultrasound coupled to Doppler:axillary aneurysm of left upper limb.

The revealing mode of the aneurysm and the rarity of this complication prompted us to report this interesting observation.

Discussion

Aneurysms of the axillary artery are rare. Etiologies include atherosclerosis [1], post-stenotic dilatation related to thoracic outlet syndrome [2], elastopathy (Marfan, Ehler Danlos), infections, and penetrating or closed trauma [3].

The pathophysiology of arterial vascular disease in Behcet disease remains poorly understood. Some authors believe that the anatomic substratum of these arterial lesions is the abnormalities of the arterial wall involving in particular parietal factors [4,5]. The role promoting local trauma has been highlighted, such as the occurrence of aneurysm at the point of arterial puncture when performing arteriography, measurement of blood gases or trauma [6]. The involvement of blood hypercoagulability is not clearly established [4]. The treatment of these lesions is the surgical excision of the aneurysm.

With the significant development of endovascular treatment, endovascular excision is now the treatment of choice for this type of lesion [7].

Conclusion

Aneurysmal lesions of the axillary artery and its branches are rare and may be related to several etiologies, but they may also be the consequence of systemic vasculitis such as Behcet's disease. The physician must always bear in mind this diagnosis in order not to venture to perform biopsies or punctures of any axillary mass before performing a minimum morphological assessment including at least one ultrasound coupled to Doppler.

Declaration

The authors declare that they have no conflict of interest.

References:

1. Michalakis D, Lerais J, Goffette P, Royer V, Brenot R, Kastler B. [True isolated atherosclerotic aneurysm of the axillary artery]. *J Radiol.* 2003;84:1016-9
2. Durham J, Yao J, Pearce W, Nuber G, McCarthy W. Arterial injuries in the thoracic outlet syndrome. *J Vasc Surg.* 1995;21:57-69;

3. Pairolero P, Walls J, Payne W, Hollier L, Fairbairn J. Subclavian-axillary artery aneurysms. *Surgery.* 1981;90:757-63
4. M. Hamza. *Maladie de Behçet.* 4th ed. In: Kahn MF, Peltier AP, Meyer O, Piette JC, editors. *Maladies et syndromes systémiques.* Paris: Flammarion Médecine-Sciences; 2000. p. 883–924.
5. McNeil HP, Chesterman CN, Krilis SA. Immunology and clinical importance of antiphospholipid antibodies. *Adv Immunol* 1991;49:193–280.
6. Le Thi Huong D, Wechsler B, Papo T, Piette JC, Blétry O, Vitoux JM, et al. Arterial lesions in Behçet's disease. A study in 25 patients. *J Rheumatol* 1995;22:2103–13.
7. Z. Amoura, M. Guillaume, S. Caillat-Zucman, B. Wechsler, J.-C. Piette. *Physiopathologie de la maladie de Behçet.* *La Revue de médecine interne* 27 (2006) 843–853