

## Fahr's Syndrome: A Rare Case of Basal Ganglia Calcification Due to Hypoparathyroidism

Muhammed Yasir K, Murtaza Kamal, Ajay Kumar and Srilatha Bajaj  
Department of Pediatrics, Safdarjung Hospital & VMMC, New Delhi, India.

### ARTICLE INFO

#### Article history:

Received: 12 March 2018;

Received in revised form:  
20 April 2018;

Accepted: 1 May 2018;

#### Keywords

Fahr's syndrome,  
hypoparathyroidism.

### ABSTRACT

Fahr's syndrome is a rare neurodegenerative disorder characterized by bilateral, symmetrical deposition of calcium in the basal ganglia, thalamus, cerebral cortex, dentate nucleus, cerebellum subcortical white matter, and hippocampus. It usually presents in the fourth or fifth decade with seizures and extra pyramidal symptoms initially and then gradually progressive cognitive impairment. It is mostly associated with a disorder of calcium and phosphate metabolism, but can also be due to infectious, metabolic, or genetic diseases. A 10 year old girl presented with history of recurrent seizures, headache, and tetany since the age of 6 years. On examination Chvostek and Trousseau signs were positive, bilateral cataract and papilledema were present. Laboratory tests showed ionic calcium of 0.47 mmol/L. Electrocardiography showed prolonged QT interval. Computed tomography scan of the brain showed bilateral symmetric calcification of lentiform nuclei and the subcortical fibers of fronto-parietal region. Final diagnosis of our case was Fahr's syndrome secondary to hypoparathyroidism based on further investigations.

© 2018 Elixir All rights reserved.

### Introduction

Fahr's syndrome is a rare neurodegenerative disorder characterized by bilateral, symmetrical deposition of calcium in the basal ganglia, thalamus, cerebral cortex, dentate nucleus, cerebellum subcortical white matter, and hippocampus and usually present in the fourth or fifth decade of life. It is mostly associated with a disorder of calcium and phosphate metabolism, but can also be due to infectious, metabolic, or genetic diseases. The clinical manifestations can be paresthesias, seizures, myoclonus, tetany, parkinsonism, and neuropsychiatric disorders[1]. Early treatment can reverse neurological symptoms and prevent irreversible alterations thus emphasizing the need to recognize early clinical manifestations[1, 2,3].

Hypoparathyroidism (HP) is an endocrine disorder, caused by a heterogeneous group of conditions, in which low calcium and high phosphate levels occur as the result of insufficient parathyroid hormone (PTH) secretion. Idiopathic hypoparathyroidism is a term for a rare deficient PTH secretion without definitive cause and may be genetically inherited or may have an autoimmune cause. Radiologically, this state may cause calcifications, predominantly in globus pallidus of the basal ganglia. Symptoms attributable to their involvement are uncommon at the clinical presentation. Histological findings in the form of symmetrical brain calcifications, were observed for the first time by Bomberger in 1855. Clinical manifestations of Fahr's syndrome was first described in 1930 by German neurologist Karl Theodor Fahr[1,2,3]. The association of basal ganglia calcifications with chronic HP, was described for the first time by Eaton et al. in 1939. Today, there are two entities associated with basal ganglia calcification.

The primary form, also called Fahr's disease, is characterised by idiopathic calcifications of brain tissue and it is considered as familial or sporadic disorder.

Fahr's syndrome is the secondary form of brain calcifications, that is caused by some other known disease[4,5]. We are presenting the case of an adolescent girl with Fahr's syndrome caused by hypoparathyroidism.

### Case Report

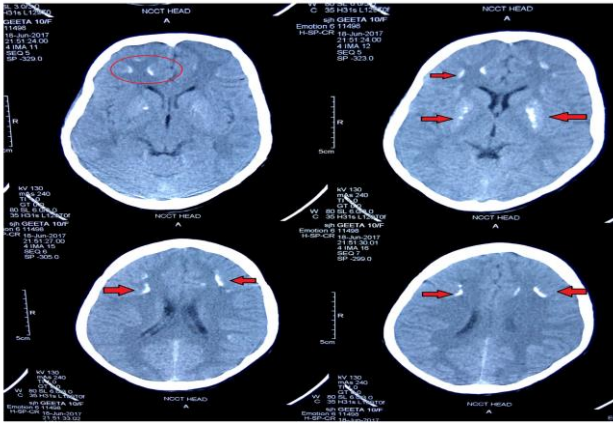
A 10-year-old girl presented with seizure and altered sensorium with past history of headache, seizures and tetany. Physical examination revealed positive Chvostek and Trousseau sign, bilateral papilledema and cataract. She had a blood pressure of 100/ 68 mmHg and heart rate 76 beats per min. Electrocardiogram revealed prolonged QT interval (QTc 630 ms) (Figure 1) Laboratory tests showed decreased levels of Serum calcium (3.6 mg/dl; normal range 8.5–11mg/dl), ionized calcium (0.47 mmol/L; normal range 1.00–1.30 mmol/L) and parathyroid hormone (0.1 pg/ml; normal range 75.1 pg/ml) [5/17, 10:02 PM] drmuhammedyasirk. Serum phosphorus level was high 10.8 mg/dl (2.5-5.5 mg/dl). The results of all other hormone tests were normal.

Computer tomography of the brain revealed bilateral symmetric calcification of lentiform nuclei and subcortical fibers of fronto-parietal region (Figure 2). Other secondary causes of brain calcifications were excluded by laboratory testing. Chest radiography and ultrasound examination of the neck, abdomen and pelvis were normal. Echocardiography showed mild LV dysfunction probably due to chronic hypocalcemia. On the basis of clinico-radiological and biochemical findings, diagnosis of primary hypoparathyroidism and Fahr's syndrome was suggested.

Tele:

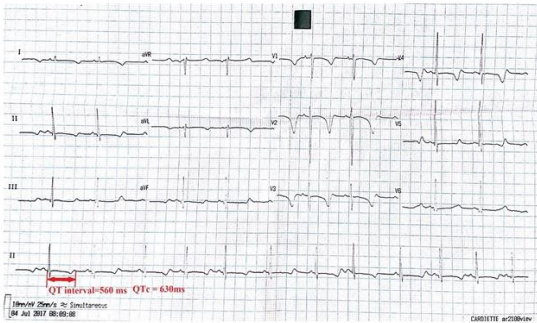
E-mail address: [drmuhammedyasirk@gmail.com](mailto:drmuhammedyasirk@gmail.com)

© 2018 Elixir All rights reserved

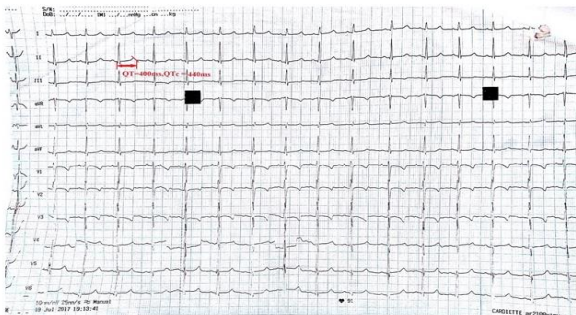


**Figure 1. NCCT of brain showing bilateral symmetric calcification of lentiform nuclei and subcortical fibers of fronto-parietal region**

Immediately after admission to the hospital, the patient got intravenous rehydration, calcium infusion followed by oral supplemental calcium and calcitriol. Gradually after two weeks, all laboratory tests, clinical signs, and electrocardiogram finding went back to normal (Figure 3). Patient was discharged on oral calcium and calcitriol. Serum calcium and ionized calcium levels came to be at the lower reference limits on follow up visit.



**Figure 2. ECG showing prolonged QT interval**



**Figure 3. ECG after treatment showing normal QT interval**

## DISCUSSION

The term Fahr's disease refers to idiopathic calcifications in the basal ganglia and other brain regions. It can be sporadic or inherited in an autosomal dominant pattern[6,7,8,9,10]. Fahr's syndrome is defined as bilateral and symmetric calcifications of basal ganglia and other brain regions, secondary to various metabolic, infectious, or degenerative diseases like endocrine disorders, mitochondrial myopathy, some dermatological disorders, brucellosis, toxoplasmosis, etc [ 7, 11,12]. The essential difference between the disease and the syndrome is the presence of the family history of

BGC (Fahr's disease) and evidence of some other, known cause (Fahr's syndrome).

The most commonly reported metabolic disorders that cause Fahr's syndrome are hypoparathyroidism and pseudo hypoparathyroidism[6, 13].

Hypoparathyroidism may be due to genetic, autoimmune, post-surgical or idiopathic causes [4,6,12]. It may be inherited as autosomal dominant, autosomal recessive or X-linked pattern, and may occur in childhood or later in life. Autoimmune hypoparathyroidism may be isolated, or exist as a part of autoimmune polyglandular syndrome type 1 or type 2. The former disorder is also inherited, but it usually occurs by early adolescence and always before the age of 25. The latter presents in adulthood in combination with adrenal insufficiency, type 1 diabetes mellitus, or thyroid autoimmune diseases[8,12,14,15].

In patients with idiopathic form of HP, adequate oral calcitriol and calcium supplementation is needed in order to restore calcium/phosphorus ratio and reduce the risk of basal ganglia calcification[4,12,16]. There is no clear explanation for the mechanism of brain calcification and hypocalcemia association. It is suggested that increased calcium-phosphorus complex formation plays an important role[4,12].

Most common clinical features are neurological, including seizures, spasticity, choreoathetosis, tremor, headache, vertigo, dysarthria, loss of consciousness. psychiatric features include depression, manic symptoms, irritability, aggression, or deterioration of intelligence[ 6,7,10,11,15]. The impact of changes in calcium levels in the QT interval in ECG recording is well-known. In our case, electrocardiogram revealed prolonged QT interval, fully reversed with normal serum calcium levels. Other features include, positive Trousseau sign, decreased serum calcium, and PTH levels. CT finding of bilateral brain calcifications completed the diagnosis towards Fahr's syndrome due to hypoparathyroidism.

There is no standard course of treatment for Fahr's syndrome/disease. Recommended treatment is directed towards symptomatic control of neurological manifestations using anticonvulsant and antipsychotics treatment and maintenance of electrolyte, and hemodynamic balance[7,15,17]. In cases of Fahr's syndrome due to hypoparathyroidism, the neurological and psychiatric symptoms usually improve with normalisation of plasma calcium and phosphorus levels. It is recommended to obtain a target serum calcium level in the low normal range[4,18]. The subcutaneous application of synthetic PTH analogs are recommended only in refractory forms with chronic hypercalciuria and kidney complications[8,12,14,19,20]. Our patient was initially managed with intravenous calcium and continued with oral calcium supplement and calcitriol preparations for maintenance of serum calcium in the low to normal range.

## References

1. Swami A, Kar G. Intracranial hemorrhage revealing pseudohypoparathyroidism as a cause of fahr syndrome. Case Rep Neurol Med. 2011;2011: 407567.
2. Ramisa J, Ibanez AE, Irigoína RR, Artigasa CF, Comasa LM. Extrapyramidal symptoms due to calcinosiscerebri in a patient with unknown primary hypoparathyroidism. Endocrinol Nutr. 2012;59(1):69-71.
3. Senoglu M, Tuncel D, Orhan FO, Yuksel Z, Gokçe M. Fahr's Syndrome: A Report of Two Cases. Firat Tip Dergisi. 2007;12(1):70-72.

4. Goswami R, Sharma R, Sreenivas V, Gupta N, Ganapathy A, Das S. Prevalence and progression of basal gangliacalcification and its pathogenic mechanism in patients with idiopathic hypoparathyroidism. *Clin Endocrinol (Oxf)* 2012;77(2):200-206.
5. Fahr TK. Idiopatische Verkalkung der Hirngefasse. *Zentralblattg Path u path anat* 1930;50:129-133.
6. Saleem S, Aslam HM, Anwar M, Anwar S, Saleem M, Saleem A, et al. Fahr's syndrome: Literature review of current evidence. *Orph J Rare Dis* 2013; 8(1): 156.
7. Kumar S, Sher K, Ahmed S, Naik S, Ayub S, Fatima BM, et al. Fahr's Disease: A Rare Neurological Disease Frequently Misdiagnosed as Acute Psychosis, or Mood Disorder. *J Neurol Disord* 2013; 1: 130.
8. Shoback D. Clinical practice. Hypoparathyroidism. *N Engl J Med* 2008; 359(4): 391-403.
9. Moskowitz MA, Winickoff RN, Heinz ER. Familial calcification of the basal ganglions: A metabolic and genetic study. *N Engl J Med* 1971; 285(2): 72-7.
10. Mufaddel AA, Al-Hassani GA. Familial idiopathic basal ganglia calcification (Fahr's disease). *Neurosciences (Riyadh)* 2014; 19(3): 171-7.
11. Kavirayani DK, Jammulapati S. Fahr's syndrome with psychotic features: Review and Case report. *NMJ* 2014; 3(2): 71-4.
12. Soares FB, Amorima FF, Santana AR, de Moura EB, Margalho SB, Amorim AP, et al. Fahr's Syndrome due to Hypoparathyroidism Following Thyroidectomy. *J Med Cases* 2013; 4(6): 380-4.
13. Rastogi R, Singh AK, Rastogi UC, Mohan C, Rastogi V. Fahr's syndrome: A rare clinico-radiologic entity. *Med J Armed Forces India* 2011; 67: 159-61.
14. Mitchell DM, Regan S, Cooley MR, Lauter KB, Vrla MC, Becker CB, et al. Long-term follow-up of patients with hypoparathyroidism. *J Clin Endocrinol Metab* 2012; 97(12): 4507-14
15. Rizvi I, Ansari NA, Beg M, Shamim MD. Widespread intracranial calcification, seizures and extrapyramidal manifestations in a case of hypoparathyroidism. *N Am J Med Sci* 2012; 4(8): 369-72.
16. Ghosh K, Sengupta N, Sau TJ, Chatterjee A. Rare presentation of a common disease: Idiopathic hypoparathyroidism presenting with extrapyramidal symptoms and status epilepticus. *Indian J Endocr Metab* 2012; 16(6): 1035-6.
17. Caliskan T, Gurbuz S. Fahr's Disease. *J Contemp Med* 2013; 3(2): 133-5
18. Ahad MA, Bala CS, Karim SR. Fahr's Syndrome. *Bang Med J (Khulna)* 2012; 45(1-2): 33-5.
19. Winer KK, Zhang B, Shrader JA, Peterson D, Smith M, Albert PS, et al. Synthetic human parathyroid hormone 1-34 replacement therapy: a randomized crossover trial comparing pump versus injections in the treatment of chronic hypoparathyroidism. *J Clin Endocrinol Metab* 2012; 97(2): 391-9
20. Winer KK, Cutler GB. Treatment of Hypoparathyroidism with Parathyroid Hormone 1-34. In: Brandi ML, Brown EM, editors. *Hypoparathyroidism*. Milano: Springer-Verlag Italia; 2015. p. 319-31.