

## Rare case of a giant superficial leiomyosarcoma of the thigh: Diagnostic difficulties and management.

F Saoudi<sup>1</sup>, A Lagdid<sup>1</sup>, R.Bassir<sup>2</sup>, M. Boufettal<sup>2</sup>, M.Kharmaz<sup>1</sup>, M.O Lamrani<sup>1</sup>, M.Ouadghiri<sup>1</sup>, M. Mahfoud<sup>1</sup>, A.Elbardouni<sup>1</sup> and M.S. Berrada<sup>1</sup>

<sup>1</sup>Department of Orthopaedic Surgery and Traumatology, Ibn Sina UHC, Mohamed V University, Rabat.

<sup>2</sup>Anatomy Laboratory, Faculty of Medicine and Pharmacy of Rabat. Morocco.

### ARTICLE INFO

#### Article history:

Received: 4 June 2018;

Received in revised form:  
01 July 2018;

Accepted: 11 July 2018;

#### Keywords

Leiomyosarcoma,  
Skin,  
Superficial.

### ABSTRACT

A Primary cutaneous leiomyosarcoma located in the left thigh is reported in a 83-year-old patient. The clinical examination found a voluminous ulcero-budding infected tumor, measuring 15 cm long axis. The result of the histological examination and the immuno-histochemical profile revealed the diagnosis of a leiomyosarcoma. The patient underwent extensive excision with cutaneous margins of three to five cm and carried the Gracilis muscle deep down. After one year of control we did not notice local recurrence. The prognosis remains poor. We recommend long-term follow-up of patients to prevent recurrence. The purpose of this work is to show the difficulties to make the diagnosis and describe our management of this rare case.

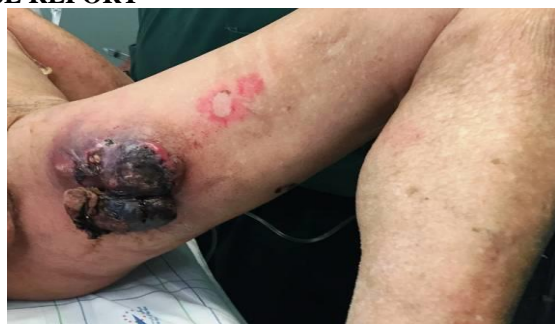© 2018 Elixir All rights reserved.

### INTRODUCTION

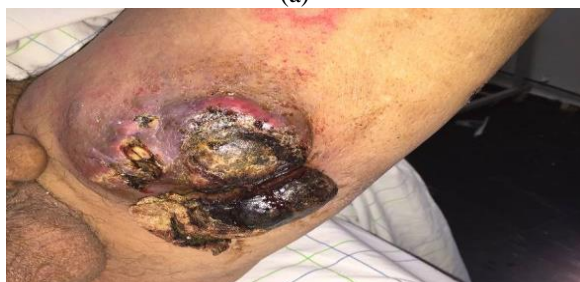Primary cutaneous leiomyosarcoma (PCL) is a rare malignancy. It accounts for 2 to 3% of all soft tissue sarcomas [1]. They can come from the erector smooth muscle of the hair at the origin of the dermal leiomyosarcoma also called cutaneous leiomyosarcoma or smooth muscles of the adipose tissue vessels giving the subcutaneous or hypodermic leiomyosarcoma.

We report a particular case of giant superficial leiomyosarcoma of the thigh with highlighting the diagnostic and management difficulties.

### CASE REPORT



(a)



(b)

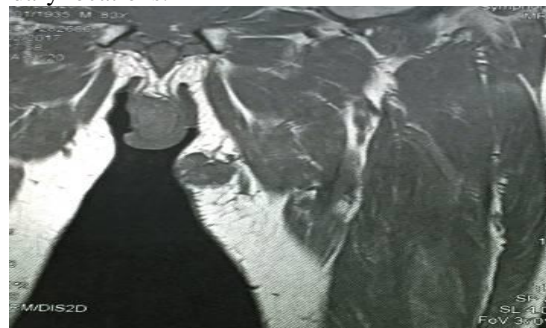
Figure 1a-b. Ulcerated tumor budding and infected on the inside of the thigh.

84-year-old patient without pathological history in good general condition, presenting with ulcerated swelling of the left thigh, which has been evolving for eight months.

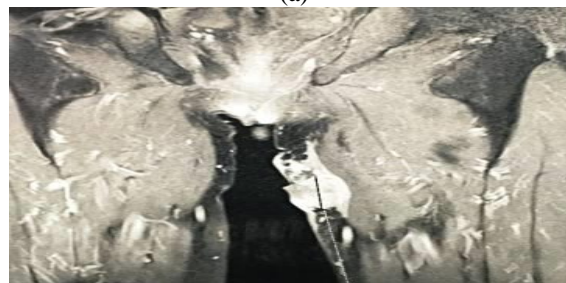
The clinical examination found a voluminous ulcero-budding infected tumor, measuring 15 cm long axis sitting on the inner side of the left thigh (fig1).

MRI showed a malignant dermo-hypodermic malignancy of the inner thigh with close contact with the Gracilis muscle (Fig. 2).

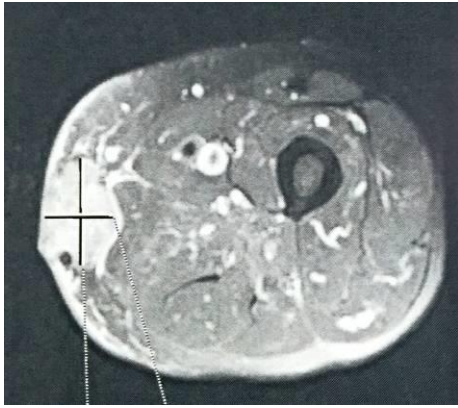
The result of the histological examination revealed a cutaneous sarcoma with spindle cell of high malignancy and the immuno-histochemical profile confirmed the diagnosis of a leiomyosarcoma. The extension assessment did not show secondary locations.



(a)



(b)

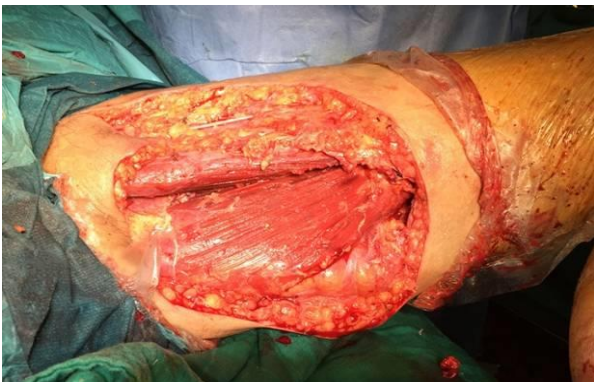


(c)

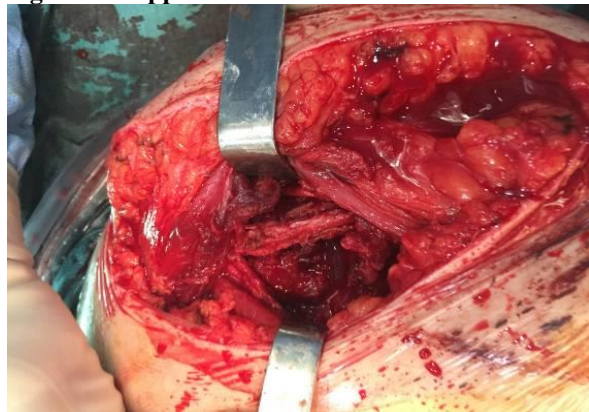
**Figure 2a-b-c. MRI aspect of the tumor showing its contact with the Gracilis muscle.**

The result of the histological examination revealed a cutaneous sarcoma with spindle cell of high malignancy and the immuno-histochemical profile confirmed the diagnosis of a leiomyosarcoma. The extension assessment did not show secondary locations.

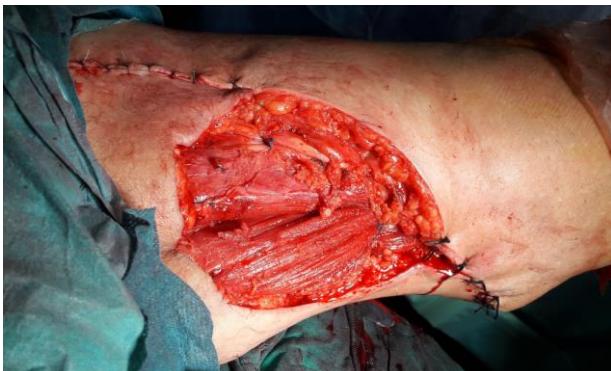**RESULTS**



**Figure 3a. Appearance after resection of the tumor.**

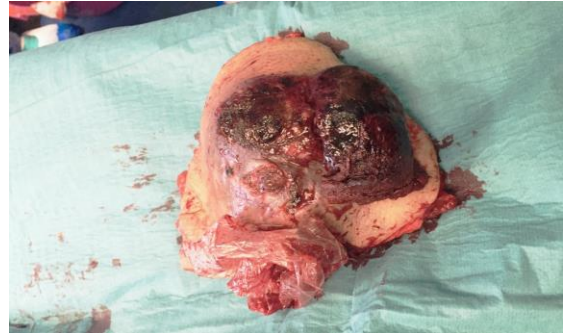

**Fig 3b. Image showing the vascular pedicle of the thigh which is intact.**

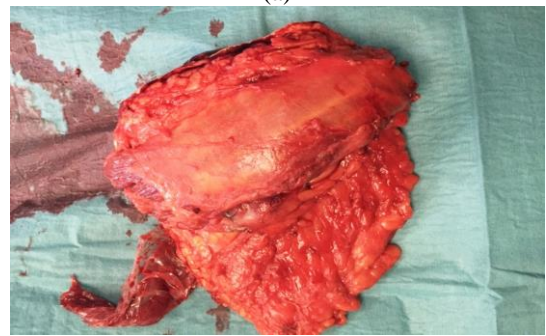

**Figure 4. Residual skin loss after the nearing of the wound edges.**

The patient underwent extensive excision with cutaneous margins of three to five cm and carried the Gracilis muscle deep down. The vascular pedicle and the large sciatic nerve were intact at a safe distance from the tumor (Fig. 3). After nearing the wound edges the loss of cutaneous substance is estimated at 20 \* 15cm (Fig. 4). The exeresis limits were healthy on histological examination of the surgical specimen (Fig 5).



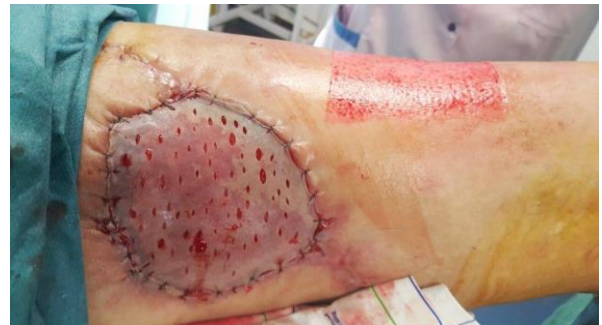(a)



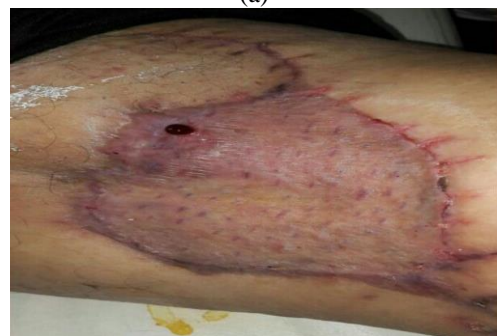(b)

**Figure 5. Macroscopic appearance of the operative specimen including the Gracilis muscle.**

The patient is kept in the trauma department for local wound care; the monitoring is marked by good post-operative follow-up including no signs of infection. After budding of the residual wound bed, a thin skin graft was performed with very good aesthetic and functional results (Fig. 6). After one year of control we did not notice local recurrence.



(a)



(b)

**Figure 6a. Wound cover by a thin skin graft. b. result after three months.**

## DISCUSSION

LCP occurs in people of all ages but with a peak between 60-70 years old. Superficial leiomyosarcomas have two subdivisions, the cutaneous and subcutaneous forms. Subcutaneous tumors have been associated with a higher risk of local recurrence and distant metastases compared to the cutaneous form [2].

The clinical aspect is not specific with a wide range of differential diagnoses: squamous cell carcinoma, achromic melanoma, and basal cell carcinoma [3]. LCP is generally considered a solitary nodule; the nodule may be lobulated, pedunculated or umbilicated with a surface that may be smooth, indurated, ulcerated, scaly, verrucous or hemorrhagic [4]. In our patient, we observed the solitary and nodular character with ulcerated smooth surface. It is a fast growing mass and the prognosis is poor if the mass size is greater than five cm [4]. For our case the size is voluminous, to our knowledge; no case in the literature has been reported with such a volume. The risk of relapse is not zero even in the case of R0 exeresis of dermal LCPs which is not very recurrent [5]. This is perhaps why some authors argue for a wide excision with margins of three to five cm and a depth that includes the subcutaneous tissue and fascia [6].

Adjuvant therapies include radiotherapy, chemotherapy [4]. However, LCP has been reported as radio-resistant; also chemotherapy with doxorubicin has failed in some cases [1].

## CONCLUSION

Primary cutaneous leiomyosarcoma is a rare entity whose clinical presentation may seem nonspecific, making diagnosis difficult.

Anatomo-clinical correlation and immunohistochemical examination are mandatory for the definitive diagnosis.

Surgical excision with wide margins of safety is the standard treatment. Other therapeutic methods, such as radiotherapy or chemotherapy, are described but without significant benefits. Despite radical surgical treatment, because of recurrence rates, the prognosis remains poor. We recommend long-term follow-up of patients to prevent recurrence.

## REFERENCES

1. Lin JY, Tsai RY. Léiomyosarcome sous-cutané sur le visage. *Dermatol Surg*. 1999;25:489-91.
2. Torres T, Oliveira A. Superficial cutaneous leiomyosarcoma of the face: report of three cases. *J Dermatol*. 2011;38:373-37
3. Kuflik JH, Schwartz RA, Rothenberg. Léiomyosarcome. *J Am Acad Dermatol*. 2003;48:51-3.
4. Vraa S, Keller J, Nielsen OS, Jurik AG, Jensen OM. Soft-tissue sarcoma of the thigh: surgical margin influences local recurrence but not survival in 152 patients. *Acta Orthop Scand*. 2001;72:72-7.
5. Cochereau D, Battistella M, Morelot Q, Pagès C, Basset-Seguín N, Marco O, et al. Pronostic et risque de rechute locale dans les léiomyosarcomes cutanés sus-aponévrotiques en résection complète. *Ann Dermatol Vénéreol*. 2015;142:S453.
6. Poisson FS. Sarcomes des tissus mous en dermatologie. *Dermatol Surg*. 1996;22:268-73