

Intradural Disc Herniation: A Case Report and Literature Review

Oujidane Zamani, Sarah Mounna, benaissa leila, Semlali Siham and Jamal El
Radiology Department, Mohammed V Military Hospital, Rabat, Morocco.

ARTICLE INFO

Article history:

Received: 19 June 2018;

Received in revised form:
01 August 2018;

Accepted: 10 August 2018;

Keywords

Intradural,
Disc,
Herniation,
MRI,
Surgery.

ABSTRACT

Intradural disc herniation (IDH) is a rarely reported cause of radicular pain. Preoperative imaging can be useful for diagnosis, but differentiation of intra-dural tumors from large disc hernias is difficult and intraoperative findings are required for definitive diagnosis. We present here a case of IDH, which was depicted by high-resolution MRI. It is very representative of the difficulty to make the diagnosis and illustrates the added value of high-resolution MRI when an atypical disc herniation is suspected.

© 2018 Elixir All rights reserved.

Introduction

Intradural disc herniation is a rare complication of intervertebral disc hernia. Since the first description by Dandy in 1942, over hundred cases have been reported in literature [1]. The diagnosis of intradural disc herniation in most case reports has been an intra-operative finding. In the case of a lumbar extradural disc hernia, cranial or caudal migration of the ruptured disc fragment is usually seen. We report the case of an excluded intradural disc hernia with caudal migration of the disc fragment illustrated by MRI.

Patient and observation

A 45 years-old patient with a medical history of low back pain was admitted to the neurosurgery unit for an acute exacerbation of radicular pain. At muscular testing, there was no deficit. Osteotendinous reflexes were present. Computed tomographic (CT) exploration showed a right paramedian disc hernia at the L4–L5 and L5/S1 levels. Because the Clinical symptoms doesn't decrease with intravenous analgesia, an MRI examination of the lumbar spine was performed in our unit.

MRI revealed a rupture of posterior annulus fibrosus at L4–L5 level with extruded nuclear in anterior epidural space, and gadolinium-enhanced MRI showed ring enhancement. There were signs of degenerative lesions at the L4–L5 and L5–S1 intervertebral discs.

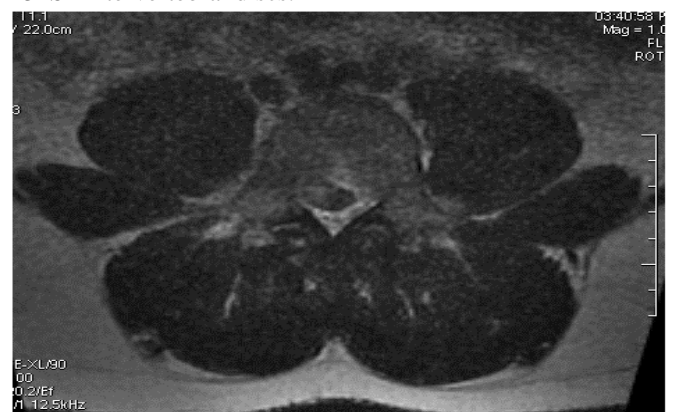


Figure 2 .T2 –weighted MRI showing the fragmented disc at L4/L5 level which filling the intrathecal nerve roots.

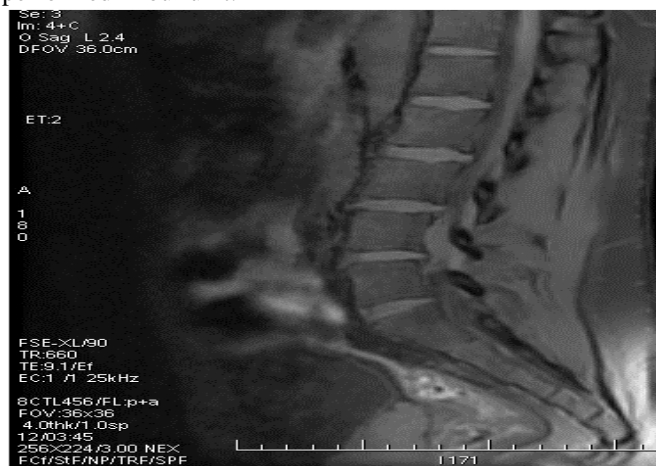

Figure1. T1-weighted MRI showing hypointense fragmented disc at L4–L5 level with a rupture of posterior annulus fibrosus.

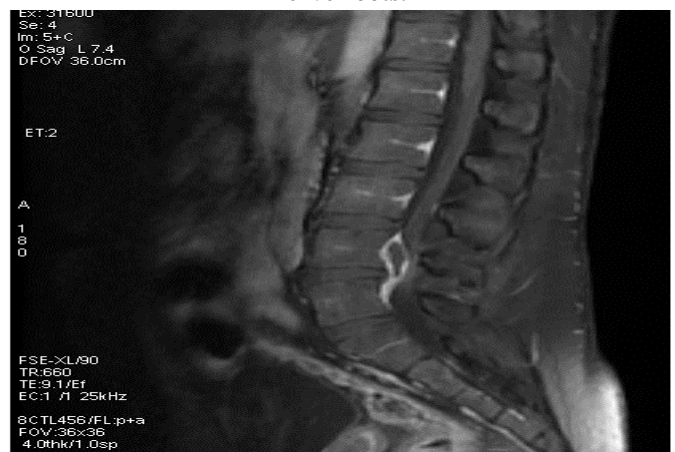

Figure 3. Peripheral enhancement of the herniated material on post gadolinium MRI.

Tele:

E-mail address: oujdanezamani@gmail.com

© 2018 Elixir All rights reserved

Discussion

The first case of an intradural disc rupture was reported by Dandy [2] in 1942. The incidence of this complication is around 1% for all lumbar disc hernias according to the series [3]. Average age of presentation is usually in the fifth and the sixth decade. Males represent 76% of the reported cases [4]. In majority of cases, the lumbar spine is affected and the commonest levels being L3-4 and L4-5. The lumbosacral region has lower incidence of these complications which can be due to narrower canal at higher lumbar regions [5].

The pathogenesis of intradural herniation (IDH) is unclear. In most instances the dural erosion may be precipitated by intradiscal calcification, previous herniation, adhesions between the dura and the posterior longitudinal ligament [6].

In our case, Preexisting degenerative spondilotic changes and the chronic herniated disc may have contributed to adhesions. Perhaps the most likely cause was mechanical irritation due to the chronic disc herniation against the ventral wall of the dura.

Clinical history consists of chronic low back pain, acute radicular pain and progressive neurologic deficit. There are no differentiating clinical signs between an extradural and intradural disc herniation although certain clinical findings are more commonly found in the latter. The severity of neurological deficit is higher in intradural disc herniation [7]. Cauda equina syndrome occurs significantly more frequently (30%) as compared to higher level extradural herniation (<1%).

MRI is the gold standard for the diagnosis. Typical IDH imaging features include ring enhancement on gadolinium-enhanced MRI, which is required for differential diagnosis of herniated discs from tumors such as schwannoma and meningioma [8, 9]. Ring enhancement is caused by chronic granulation tissue and peripheral neovascularization [8]. In IDH, air images with the sequestrum in the intradural space or spinal canal are sometimes seen on CT, at six times the frequency observed in normal disc herniation [10] authors have reported a striking association of intradural disc herniation and the presence of gas within the spinal canal on CT scan [10,11]. The presence of air within the spinal canal on CT scans, and of an intradural mass on MRI, is almost diagnostic of a herniation rather than a tumor. Any of the intradural cauda equina tumors can mimic the appearance of intradural disc herniation. The differential diagnosis includes schwannoma, meningioma, ependymoma, epidermoid and dermoid tumors. In contrast to intradural disc herniation, these lesions present with gradually progressive leg pain, back pain or neurological deficits as they are slowly growing lesions.

MRI helps to establish a differential diagnosis. Schwannoma and meningioma are the most frequent intradural tumors. Schwannomas are isointense on T1 and hyperintense on T2 whereas meningiomas are isointense on both T1 and T2 wt images. These lesions demonstrate a homogenous enhancement. Ependymomas are hyperintense on T2 (unlike disc material) and enhance markedly. Although unlikely, there have been two reports of intradural disc herniation demonstrating increased signal intensity on T2-weighted images [12]. Epidermoid and dermoid tumors do not enhance on contrast imaging.

The final diagnosis of IDH is typically made intra-operatively [13]. Surgical treatment of IDH involves removal

of the intradural disc sequestrum. It is also important to initially find the anterolateral portion of the dural sheath. Care is also required with the nerve roots and intervertebral foramen to avoid injury in cases of lumbar herniation. Treatment of ventral dural defects differs widely in case reports and include closure with an autogenous fascial or fat graft, closure with an artificial membrane, and direct suturing [14]

Conclusion

Intradural lumbar disc herniations are uncommon presentations of a relatively frequent pathology. Although MRI findings can be helpful for the preoperative diagnosis, the confirmation occurs only in the intra-operative period. One should pay attention to some characteristics of this pathology, mainly the intraoperative difficulty on dissecting the anterolateral aspect of the dural sac from the annulus fibrosus of the intervertebral disc.

References

- [1] CReema, PPrabodhan, CKshitij, BMihir. *MRIDiagnosisOfIntr radural Lumbar Disc Herniation. Report Of Three Cases With Review Of Literatur*. The Internet Journal of Orthopedic Surgery. 2010 Volume 18 Number 2.
- [2] Dandy WE. Serious complication of ruptured intervertebral disc. *JAMA* 1942; 119:474-7.
- [3] Schisano G, Franco A, Nina P. Intradicular and intradural lumbar disc herniation: experiences with nine cases. *Surg Neurol* 1995; 44:536-43.
- [4] Clatterbuck RE, Belzberg AJ, Ducker TB. Intradural cervical disc herniation and Brown-Séquard's syndrome. Report of three cases and review of the literature. *J Neurosurg*. 2000 Apr; 92(2 Suppl):236-40.
- [5] Almond LM, Hamid NA, Wasserberg J. Thoracic intradural disc herniation. *Br J Neurosurg*. 2007 Jan; 21(1):323-4.
- [6] Jenkins LE, Bowman M, Cotler HB, Gildenberg PL. Intradural herniation of a lumbar intervertebral disc. *J Spinal Disord*. 1989 Sep; 2(3):196-200.
- [7] Mut M, Berker M, Palaoglu S. Intradicular disc herniations in the lumbar spine and a new classification of intradural disc herniations. *Spinal Cord*. 2001 Oct; 39(10):545-8.
- [8] Jain SK, Sundar IV, Sharma V, Goel RS, Gupta R. Intradural disc herniation: a case report. *Turk Neurosurg* 2013; 23:389-91.
- [9] Liu CC, Huang CT, Lin CM, Liu KN. Intradural disc herniation at L5 level mimicking an intradural spinal tumor. *Eur Spine J* 2011; 20:326-9.
- [10] Hidalgo-Ovejero AM, García-Mata S, Gozzi-Vallejo S, Izco-Cabezón T, Martínez-Morentín J, Martínez-Grande M. Intradural disc herniation and epidural gas: something more than a casual association? *Spine* 2004; 29:463-7.
- [11] Borota L, Jonasson P, Agolli A. Spontaneous resorption of intradural lumbar disc fragments. The spine journal: official journal of the North American Spine Society. 2008 Jan; 8(2):397-403.
- [12] Aydin MV, Ozel S, Sen O, Erdogan B, Yildirim T. Intradural disc mimicking: a spinal tumor lesion. *Spinal Cord*. 2004 Jan; 42(1):52-4.
- [13] D'Andrea G, Trillò G, Roperto R, Celli P, Orlando ER, Ferrante L. Intradural lumbar disc herniations: the role of MRI in preoperative diagnosis and review of the literature. *Neurosurgery* 2004; 27:75-82.
- [14] Whitmore RG, Williams BJ, Lega BC, Sanborn MR, Marcotte P. A patient with thoracic intradural disc herniation. *J Clin Neurosci* 2011; 18:1730-2.