



## Clinical Images in Medicine Giant Bladder Stone

Sumba Harrison, Souhail Regragui, Tariq Karmouni, Kadir El Khader, Abdelatif Koutani and Ahmed Ibn Attiya Andaloussi

Department of Urology "B" Ibn Sina University Hospital, Rabat, Morocco.  
Mohamed V University Faculty of Medicine and pharmacy, Rabat Morocco.

### ARTICLE INFO

#### Article history:

Received: 15 October 2018;

Received in revised form:

12 November 2018;

Accepted: 22 November 2018;

#### Keywords

Bladder,  
Urinary stones,  
Cystolithotomy.

### ABSTRACT

Urinary stones are frequent. Prevalence rates vary from 1% to 20%. Young adults are the most frequent affected with about 11% of male and 7% of female population. Stone incidence depends on geographical, climatic, ethnic, dietary and genetic factors. Diagnosis is based on imaging, biochemical laboratory work-up and stone analysis via infrared spectroscopy. Bladder stones are generally of small sizes caused by bladder outlet obstruction and their treatment is relatively easy via endoscopic instrumentation. Giant bladder stones are rare in current urological practice. We here-in report a case of a 80-year-old male patient who presented to our department with lower urinary tract symptoms mainly pollakiuria and dysuria evolving for 5 years. Clinical examination revealed hypogastric pain at palpation and an enlarged prostate. Computed tomography bladder imaging showed a 6-cm giant bladder stone and 150 g enlarged prostate. Open cystolithotomy was performed to concomitantly extract the stone weighing 400 g and treat the enlarged prostate.

© 2018 Elixir All rights reserved.

### Introduction

#### Images in medicine

Urinary stones are frequent. Prevalence rates vary from 1% to 20%. Young adults are the most frequent affected with about 11% of male and 7 % of female population. Stone incidence depends on geographical, climatic, ethnic, dietary and genetic factors. Diagnosis is based on imaging, biochemical laboratory work-up and stone analysis via infrared spectroscopy. Bladder stones are generally of small sizes caused by bladder outlet obstruction and their treatment is relatively easy via endoscopic instrumentation. Giant bladder stones are rare in current urological practice. They take several years to form. They start to grow when there is urinary stasis that is caused by an underlying medical condition that prevent complete emptying of the bladder. Bladder obstruction by benign prostatic enlargement and urethral stricture are the most commonly found causes. Neurogenic bladder with stones have also been reported. Most of these bladder stones measure between 2 to 3 cm. Giant bladder stones are better treated by open surgery.

We here-in report a case of a 80-year-old male patient who presented to our department with lower urinary tract symptoms mainly pollakiuria and dysuria evolving for 5 years. Clinical examination revealed hypogastric pain at palpation and an enlarged prostate. Computed tomography bladder imaging showed a 6-cm giant bladder stone and 150 g enlarged prostate. Open cystolithotomy was performed to concomitantly extract the stone weighing 400 g and treat the enlarged prostate. Post-operative course was an eventful. Three weeks later he had good urination without storage or voiding symptoms. We encourage early consultation especially in males presenting with lower urinary tract symptoms to minimize similar incidents. General preventive measures such as dietary and hydration are encouraged to reduce the risk of urinary stone formation.

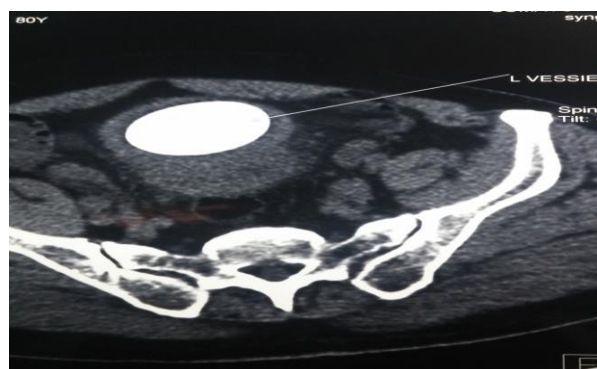


Figure 1. CT scan image showing a bladder stone.

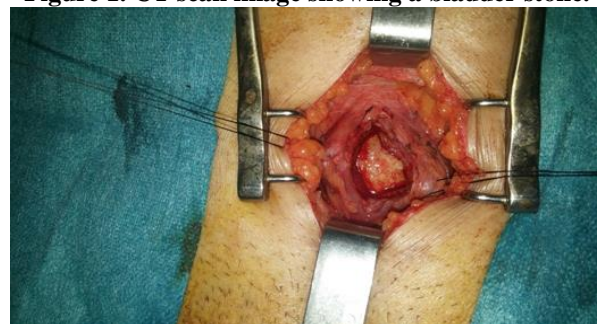

Figure 2. Per-operative aspect of bladder stone on open cystolithotomy.

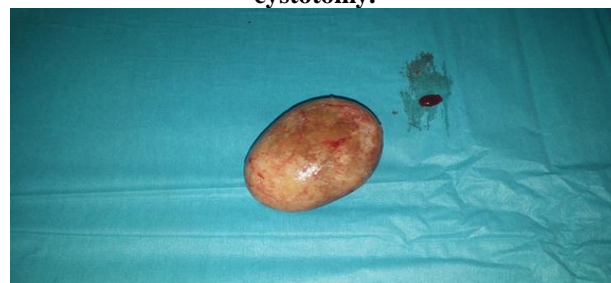


Figure 3. Post-operative aspect of bladder stone of weight 400 g.

Tele:

E-mail address: [harrysumba98@gmail.com](mailto:harrysumba98@gmail.com)

© 2018 Elixir All rights reserved