

Infectious Endocarditis Revealed Late After Dramatic Meningoencephalitis Complicated by Irreversible Blindness

Majdoub Kawtar, El Ghacham El Amrani Sihame, El Hattab Fatima Zahra, Ktiri Mohamed Amine, Sadeli Mustapha and Fellat Nadia

Department of cardiology A, CHU Ibn Sina, Mohammed V University, Rabat, Morocco.

ARTICLE INFO

Article history:

Received: 10 November 2018;

Received in revised form:

26 November 2018;

Accepted: 1 December 2018;

Keywords

Endocarditis,
Meningitis,
Brain abscess,
Tuberculosis,
Blindness.

ABSTRACT

Neurological complications of infectious endocarditis (IE) occur in 20% to 40% of patients with IE and increase their risk (1). Most often, it is about embolisms, at the origin of ischemic vascular accidents, sometimes secondarily hemorrhagic. Central nervous system infections during IE are relatively rare (2,3,4): 6-7% for meningitis (2,4) and 1-4% for brain abscess (2,4). We report the case of a 34-year-old patient whose diagnosis of endocarditis complicated by massive mitral insufficiency by ruptured cordage was retained after a dramatic episode of meningoencephalitis, the origin of which was described as tuberculosis surgical treatment. The interest of this case lies in the importance to be accorded to the cardiovascular examination in the context of neurological emergencies, the scarcity of the tubercular origin of this affection and the medical and surgical challenge to raise in front of a patient carrying a massive mitral insufficiency, a candidate for cardiac surgery and subjected to an anti-bacillary treatment of difficult management.

© 2018 Elixir All rights reserved.

Case Report

This is a patient aged 36, who presented 6 months before admission to the cardiology service a febrile syndrome with deterioration of the general condition and profuse sweats, mild disorders of consciousness, right eyelid edema and disorders walking paraparesis type. A biological assessment was requested objectifying a CRP at 134, white blood cells at 21830 / mm³, the lumbar puncture was positive with bacterial formula: gram positive cocci, negative culture. Cerebral CT was unremarkable, but cerebral MRI showed millimeter nodules suggestive of either micro-abscesses or tuberculomas (figure 1)

In front of this biological picture of bacterial meningo-encephalitis, the patient was put under a third generation cephalosporin with a meningeal dose. The evolution was marked by clinical worsening with progressive blindness and before MRI images suggestive of tuberculoma; anti bacillary

treatment associated with corticosteroid therapy was instituted with good neurological evolution: recovery of walking and consciousness with persistence of the endoscopic optic atrophy entailed a definitive blindness.

Five months after this episode, the patient was admitted to the cardiology department in a global heart failure flare chart, with a holosystolic murmur in the mitral area at cardiac auscultation and pulmonary B2 glow, ECG found right bundle branch block, transthoracic ultrasound and transoesophageal ultrasound demonstrated massive mitral regurgitation by prolapse of the anterior mitral valve leaflet (AMVL) secondary to a ruptured cordage with presence of a 13 mm mobile vegetation on the free edge of the (AMVL), left ventricle not dilated of good systolic function, ejection fraction: 67%, left atrium of limited size, dilated right cavities with good systolic function right ventricle, RT grade III, significant pulmonary hypertension (figure 2).

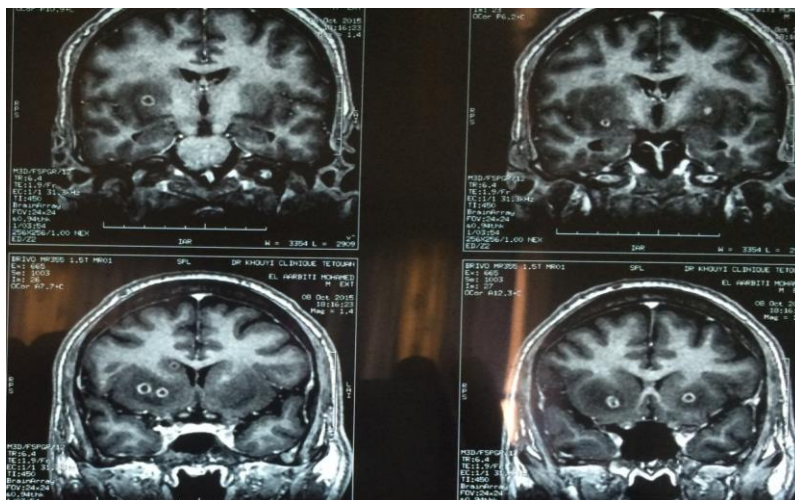


Figure 1. Brain MRI: multiple nodular lesions suggestive of micro-abscesses or tuberculomas.

Tele:

E-mail address: kawtar.majd@hotmail.fr

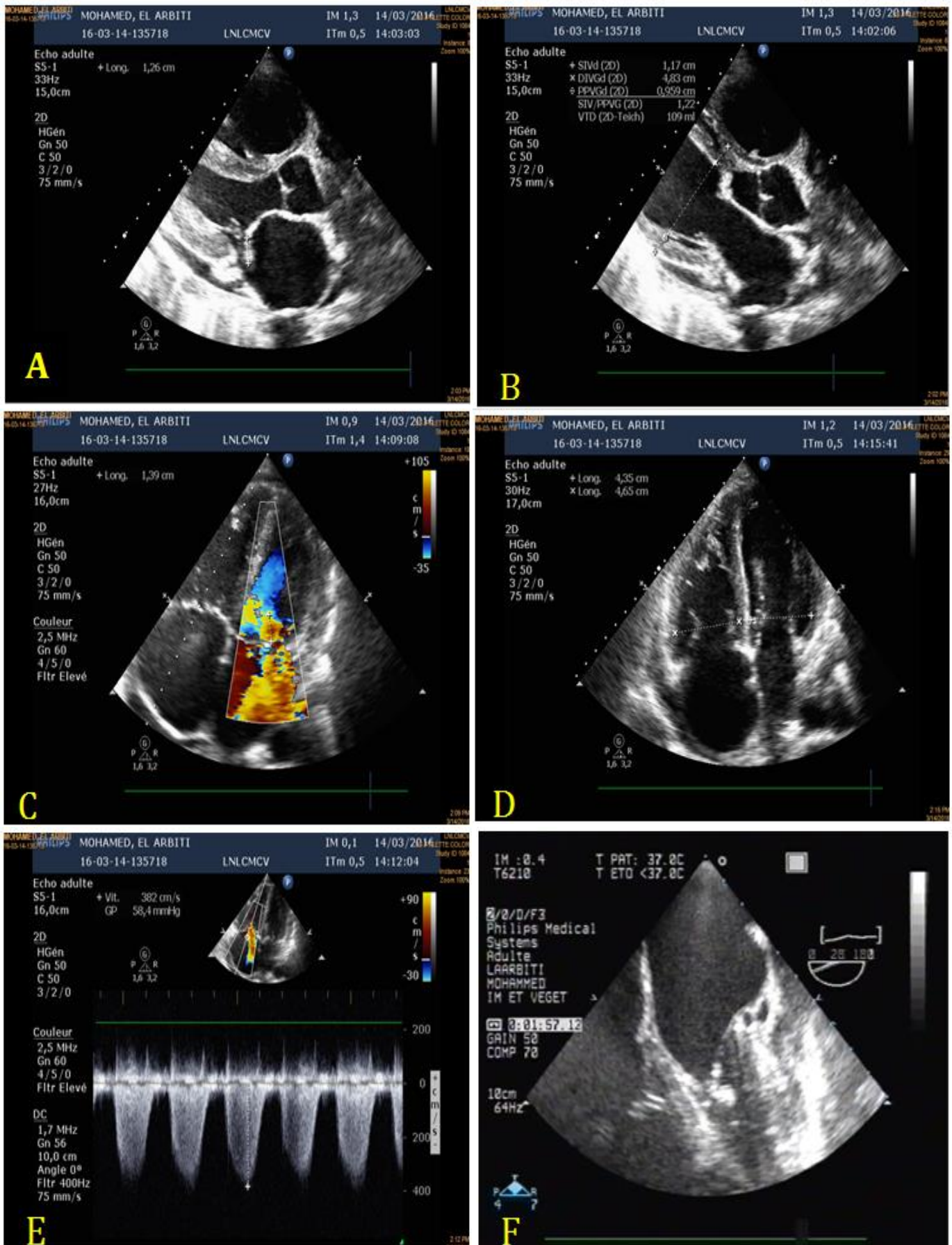


Figure 2. Transthoracic echocardiogram showing

A: a mass attached to the tip of the anterior mitral valve leaflet with severe anterior leaflet prolapse consistent with flail mitral valve. **B:** left ventricle not dilated 48 mm. **C:** mitral regurgitation severe, pisa radius: 14 mm. **D:** dilated right cavities with good systolic function right ventricle. **E:** significant pulmonary hypertension 60 mmHg. **F:** transesophageal echography showing a masse attached to the tip the anterior mitral valve leaflet evoking vegetation.

In view of its hemodynamic instability, the patient underwent surgery with resection of the vegetation and the achievement of a double mitral and tricuspid annuloplasty, the post-operative evolution was marked by the death of the patient at 48 hours after by multiorgan failure on septic and cardiogenic shock with severe biventricular dysfunction at high doses of drugs.

Discussion

Our observation suggests 4 points of discussion:

- Endocarditis and neurological complications such as abscess and meningitis.
- Infectious endocarditis and ophthalmological involvement.
- Clinical improvement under anti-tuberculosis treatment: it is an tubercular endocarditis?
- And peri-operative management of a patient under anti-tuberculosis treatment

Endocarditis and neurological complications such as abscess and meningitis

Neurological complications are the most severe extra cardiac complications of left-sided IE, occurring in 15 to 20% of patients (5,6). They can be due to various mechanisms: ischemic stroke or transient ischemic attack, cerebral hemorrhage, mycotic aneurysm, meningitis, cerebral abscess, or encephalopathy (7,8). Most of these occur early in the course of IE and are considered as major risk factors for increased morbidity and mortality (9,10).

Infection of the nervous system is rare and presents either as meningitis or as brain abscess.

In a group of patients presenting with meningitis, Carpenter and PetersdorfB found that 6% had bacterial endocarditis. Early detection of endocarditis in patients with meningitis patients may lower the rate of complications and of unfavorable outcome. This is why IE should always be ruled out in the presence of unexplained staphylococcal or streptococcal meningitis.

Brain abscesses are rare and occur in 5% of patients presenting with IE (11). They are mostly observed in IE and are caused by Sauers. Abscesses are often multiple and result from septic embolism. IE should always be ruled out for patients presenting with multiple abscesses, when no obvious source can be identified (11).

Hence the interest to be given to the cardiovascular examination in the context of neurological emergencies.

Systematic computed tomography (CT) should be performed at the acute phase of IE to thoroughly search for asymptomatic embolisms (12). MRI is a more sensitive and specific method of detecting neurological event in IE [13,14,15]. Early brain MRI led to modifications of diagnosis or therapeutic scheme in up to 28% of cases in the IMAGE study. Furthermore, MRI revealed an extended involvement of the brain (type and number of lesions), compared to clinical signs and/or CT-scan (16).

Infectious endocarditis and ophthalmological involvement

Because the optic fundus is closely related to the nervous system and because a significant percentage (20%) of patients with bacterial endocarditis have abnormalities of the fundus, some of which are so characteristic as to be of diagnostic importance, I have included these changes as a separate item. Small round or splinter hemorrhages (15%) or soft exudates (5%) result from occlusion or erosion, or both, of a retinal artery. A small hemorrhage with a whitish center, called a

Roth spot (figure 2), is characteristic of subacute bacterial endocarditis or septicemia; it occurs in about 2 to 3 percent of patients. Papilledema, noted only rarely (2%), is associated with abscess or meningitis.

In our observation, the patient presented with right eyelid edema with ophthalmologic examination posterior optic atrophy of inflammatory origin with irreversible blindness.

Clinical improvement under anti-tuberculosis treatment: it is an tubercular endocarditis?

Valvular endocarditis due to *Mycobacterium tuberculosis* is a rare clinical entity. It is usually manifest in the context of disseminated tuberculosis in immunocompromised patients. In 1826, Laennec was the first to describe cardiac tuberculosis, assigning the heart as the 13th organ affected in the order of frequency.(17) In 1906, a large series of 7683 cases of tuberculosis reported myocardial involvement in 0.62% cases. (18)

Tuberculous valvular endocarditis is usually manifest in the context of miliary tuberculosis and after valve replacement with an infected prosthetic homograft.(19,20) Porcine prosthetic valves and water used in the cardioplegia cooling solution have been reported as sources of atypical mycobacterial contamination.(21,22)

Two reports have been found in the literature of tuberculous valvular endocarditis in immunocompetent alive patients in the absence of miliary tuberculosis.(23,24)

In our observation, tuberculous endocarditis was evoked before the presence on MRI images suggestive of cerebral tuberculomas, and the lack of clinical improvement under antibiotic treatment, so anti-bacillary treatment was established with a clear clinical improvement with a CT scan control that was performed at the 6th month of the treatment objectivizing the radiological cleaning of the previous brain images (figure 3), which does not plead in favour of the diagnosis, indeed according to the various series published in the literature the progressive involution of the tuberculoma is slow and is done over several months, it accelerates between the 2nd and the 5th month then slows down after the 6th month, then disappears from any image of tuberculome in the 11th month (25)

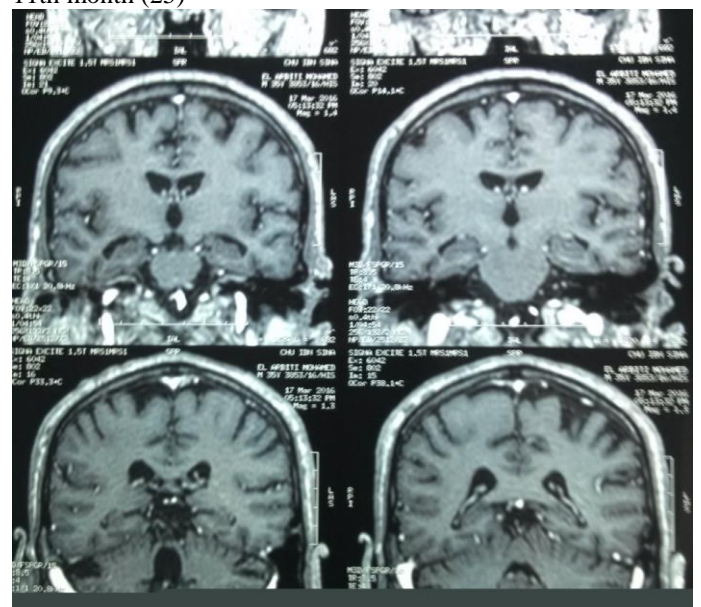


Figure 3. CT scan control that was performed at the 6th month of the treatment objectivizing the radiological cleaning of the previous brain images.

Perioperative management of a patient under anti-tuberculosis treatment

When anesthetic agents are administered to patients taking anti-tuberculosis drugs, the main challenge is to avoid the hepatotoxicity added by some anesthetic agents; suspected hepatotoxicity. only volatile halogenated agents are suspected. Halothane and Enflurane.

According to the recommendations of the French anesthesia society, the action to be taken depends on the determination of transaminases:

-In a patient without digestive signs, in case of high levels of transaminases treated with SGOT <3 times normal: continued treatment at the same doses and close monitoring of the liver.

-SGOT between 3 and 6 times normal: decrease of 2 times the dose of isoniazid and close monitoring of the liver.

-SGOT > 6 times normal (10 times for WHO): theoretically requires stopping isoniazid, but a specialist opinion is necessary to perform the substitution according to the antibiogram. (26)

According to the news sheet phramceutique (february 2015) recommends to stop treatment carefully one week before the procedure and to resume it only 15 days after.

Effectively. In our observation, antituberculous treatment was stopped 8 days before surgery and replaced by clavulanic amoxicillin and sublactam ampicillin.

Conclusion

In light of this observation, we emphasize the importance of evoking and seeking an infectious endocarditis in the presence of neurological manifestations. A febrile neurological picture can be the complication of an infectious endocarditis and be revealing.

Thus an infectious endocarditis is to be evoked in front of the appearance of a heart murmur or before brain lesions evocative by the multiple character and their varied aspect. Early diagnosis allows the initiation of appropriate antibiotic therapy and improved prognosis.

References

1. Heiro M, Nikoskelainen J, Engblom E, et al. Neurological manifestations of infectious endocarditis: a 17-years experience in a teaching hospital in Finland. *Arch Intern Med* 2000;160:2781-7.
2. Loire R, Tabib A. L'endocardite infectieuse mortelle: aspects anatomiques actuels a propos de 63 observations. *Sem Hôp Paris* 1985; 62: 2463-2466.
3. Roth B, Guego M, El Mouden M, Mahfoud A, Hadj-Slimane Z, Berkelmans F et al. Syndrome méningé fébrile et hémiplégié compliquant une endocardite infectieuse: histoire d'une infection liée au cathéters La revue de médecine interne 26 (2005) 327-330.
4. Francioli P.B. Complications of infective endocarditis. In: W.M Scheld, R.J Whitley and D.T Durack, Editors, *Infections of the Central Nervous System*, Lippincot- Raven, Philadelphia (1997), pp. 523-553.
5. Thuny F, Avierinos JF, Tribouilloy C, Giorgi R, Casalta JP, Milandre L, et al. Impact of cerebrovascular complications on mortality and neurologic outcome during infective endocarditis: a prospective multicentre study. *Eur Heart J* 2007;28(9):1155-61.
6. Sonnevile R, Mourvillier B, Bouadma L, Wolff M. Management of neurological complications of infective

endocarditis in ICU patients. *Ann Intensive Care* 2011;1(1):10.

7. Thuny F, Di Salvo G, Belliard O, Avierinos JF, Pergola V, Rosenberg V, et al. Risk of embolism and death in infective endocarditis: prognostic value of echocardiography: a prospective multicenter study. *Circulation* 2005;112(1):69-75.

8. Dickerman SA, Abrutyn E, Barsic B, Bouza E, Cecchi E, Moreno A, et al. The relationship between the initiation of antimicrobial therapy and the incidence of stroke in infective endocarditis: an analysis from the ICE Prospective Cohort Study (ICE-PCS). *Am Heart J* 2007;154(6):1086-94.

9. Murdoch DR, Corey GR, Hoen B, Miro JM, Fowler Jr VG, Bayer AS, et al. Clinical presentation, etiology, and outcome of infective endocarditis in the 21st century: the International Collaboration on Endocarditis-Prospective Cohort Study. *Arch Intern Med* 2009;169(5):463-73.

10. Mourvillier B, Trouillet JL, Timsit JF, Baudot J, Chastre J, Regnier B, et al. Infective endocarditis in the intensive care unit: clinical spectrum and prognostic factors in 228 consecutive patients. *Intensive Care Med* 2004;30(11):2046-52.

11. Tattevin P, Bruneel F, Clair B, Lellouche F, de Broucker T, Chevret S, et al. Bacterial brain abscesses: a retrospective study of 94 patients admitted to an intensive care unit (1980 to 1999). *Am J Med* 2003;115(2): 143-6.

12. Steckelberg JM, Murphy JG, Ballard D, Bailey K, Tajik AJ, Taliercio CP, et al. Emboli in infective endocarditis: the prognostic value of echocardiography. *Ann Intern Med* 1991;114(8):635-40.

13. Snygg-Martin U, Gustafsson L, Rosengren L, Alsio A, Ackerholm P, Andersson R, et al. Cerebrovascular complications in patients with left-sided infective endocarditis are common: a prospective study using magnetic resonance imaging and neurochemical brain damage markers. *Clin Infect Dis* 2008;47(1):23-30.

14. Duval X, Iung B, Klein I, Brochet E, Thabut G, Arnoult F, et al. Effect of early cerebral magnetic resonance imaging on clinical decisions in infective endocarditis: a prospective study. *Ann Intern Med* 2010;152(8):497-504 [W175].

15. Cooper HA, Thompson EC, Laureno R, Fuisz A, Mark AS, Lin M, et al. Subclinical brain embolization in left-sided infective endocarditis: results from the evaluation by MRI of the brains of patients with left-sided intracardiac solid masses (EMBOLISM) pilot study. *Circulation* 2009;120(7):585-91.

16. Goulenok T, Klein I, Mazighi M, Messika-Zeitoun D, Alexandra JF, Mourvillier B, et al. Infective endocarditis with symptomatic cerebral complications: contribution of cerebral magnetic resonance imaging. *Cerebrovasc Dis* 2013;35(4):327-36.

17. Laennec RTH. Traite de l'auscultation mediate. 1826. *Bull Acad Natl Med* 1967; 151:393-8.

18. Raviart G. La tuberculose du myocarde. *Arch Med Exper* 1906;29:141.

19. Kannangara DW, Salem FA, Thadepalli H. Cardiac tuberculosis: tuberculosis of the endocardium. *Am J Med Sci* 1984;287:45-7.

20. Yamane H, Fujiwara T, Doko S, Inada H, Nogami A, Masaki H et al. Two cases of miliary tuberculosis following prosthetic valve replacement. *Kokyu to Junkan* 1989; 37:803 -5.

21. Laskowski LF, Marr JJ, Spernoga JF, Frank NJ, Barner HB, Kaiser G et al. Fastidious mycobacteria grown from

porcine prosthetic heart valve cultures. *N Engl J Med* 1997;297:101.

22. Kuritsky JN, Bullen MG, Broome CV, Silcox VA, Good RC, Wallace RJ. Sternal wound infections and myocarditis due to organisms of the *Mycobacterium fortuitum* complex. *Ann Intern Med* 1983;98:938-9.

23. Klingler K, Brandli O, Doerfler M, Schluger N, Rom WN. Valvular endocarditis due to *Mycobacterium tuberculosis*. *Int J Tuberc Lung Dis* 1998;2:435-7.

24. Sogabe O, Ohya T. A case of tuberculous endocarditis with acute aortic valve insufficiency and annular

subvalvularleft ventricular aneurysm. *Gen Thorac Cardio-vasc Surg* 2007;55:61-4.

25. Moufid, F., Oulali, N., El Fatemi, N., Gana, R., Maaqili, R., & Bellakhdar, F. (2012). Les tuberculomes intracrâniens: à propos de 125 cas. *Pan African Medical Journal*, 12(1).

26. Mimoz, P. O., Bronchard, R., Carles, M., Dahyot-Fizelier, C., & Lasocki, S. Société Française d'Anesthésie Réanimation Comité des référentiels.