

Inferior Wall Myocardial Infarction Masked by Subclinical Hypothyroidism

Fz. EL HATTAB, S. ECHERKI, L. HARA, J. ZARZUR and M. CHERTI

Department of Cardiology B, Ibn Sina University Hospital center, Mohamed 5 University, Rabat, Morocco.

ARTICLE INFO

Article history:

Received: 1 February 2019;

Received in revised form:

7 April 2019;

Accepted: 17 April 2019;

Keywords

 Thyroid Hormones,
 Subclinical Hypothyroidism
 (SCH).

ABSTRACT

Thyroid hormones play a major role in the metabolism, growth and development of the human body. Subclinical hypothyroidism (SCH) is diagnosed when peripheral thyroid hormone levels are within normal reference laboratory range but serum thyroid-stimulating hormone (TSH) levels are mildly elevated. The pathogenesis of SCH in the development of coronary artery disease has been the subject of several studies whose results remain contradictory. We report the case of a 50-year-old women admitted for complete atrioventricular block secondary to an acute coronary syndrome of lower topography whose exploration revealed subclinical hypothyroidism.

© 2019 Elixir All rights reserved.

Introduction

Thyroid hormones play a major role in the metabolism, growth and development of the human body. The deficiency of these hormones leads to elevated levels of homocysteine, cholesterol and blood pressure, which partly explains the relationship between hypothyroidism and atherosclerotic coronary disease [2]. Subclinical hypothyroidism (SCH) is diagnosed when peripheral thyroid hormone levels are within normal reference laboratory range but serum thyroid-stimulating hormone (TSH) levels are mildly elevated [1]. The association between SCH and coronary artery disease has been the subject of much debate. Some studies have shown a relationship between SCH and the development of coronary atherosclerosis and others have reversed this association [1].

Case report

Mrs. M.F, 50 years old, hospitalized in our formation for syncopal complete atrioventricular block. She had; as cardiovascular risk factor; a dyslipidemia type hypercholesterolemia discovered three months before her admission. The cardiovascular examination was with no abnormality. Electrocardiogram records complete atrioventricular block with sequelae of necrosis in the inferior leads (Figure 1).

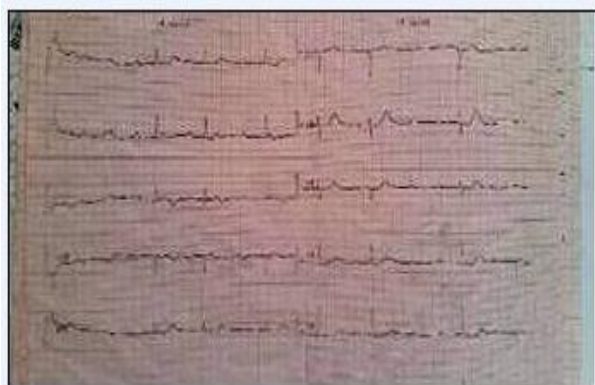


Figure 1. Complete atrioventricular block with Q wave in DIII, AVF.

Biology showed a subclinical hypothyroidism; the TSH level is high with a normal free T4 level; troponin at 30 ng/L, CKMB at 402 IU/L, ASAT at 90IU/L and hypercholesterolemia at 3g/L. Transthoracic echocardiography revealed hypokinesia of the inferior wall with preserved systolic function. Coronary angiography objectified an occlusion of the right coronary artery at its second segment (Figure 2).

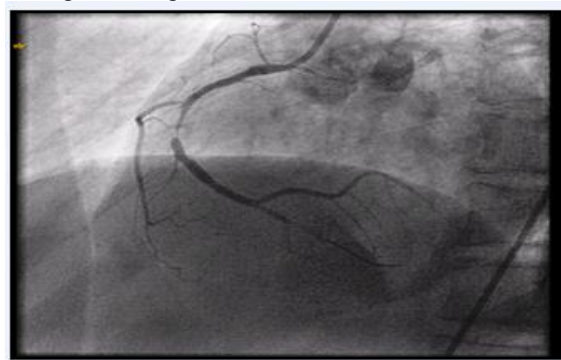


Figure 2. Occlusion of the right coronary artery at its second segment.

We proceeded to the desobstruction and coronary angioplasty with active stenting (Figure 3).

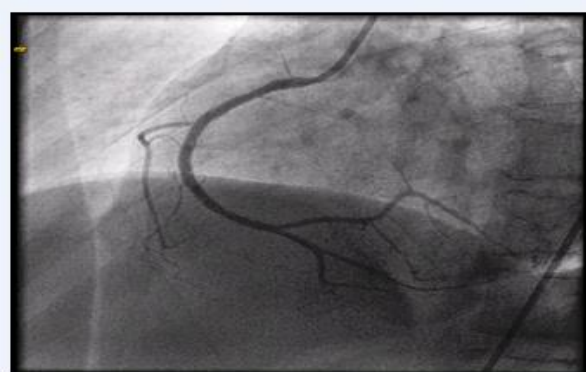


Figure 3. Successful removal of the right coronary artery with placement of an active stent.

The evolution was marked by regression of the atrioventricular block (Figure 4). The patient is also receiving thyroxin replacement therapy.

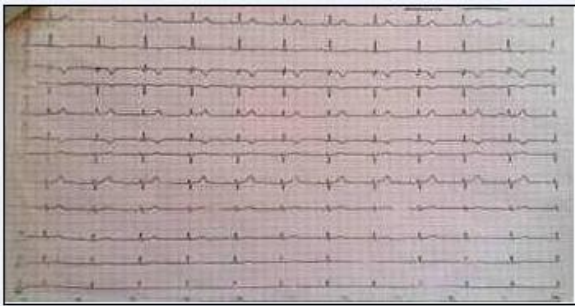


Figure 4. Regression of atrioventricular block with recovery of sinus rhythm.

Discussion

Thyroid hormones have many effects on cardiovascular hemodynamic; they affect heart rate, cardiac output, systemic vascular resistance and blood pressure [2]. Hypothyroidism induces a cardiac hypometabolism and a decrease in oxygen consumption which protects the myocardium against acute events. It is also responsible for increasing cholesterol levels as is the case in our patient [3].

Dyslipidemia is the only cardiovascular risk factor in our observation, suggesting that subclinical hypothyroidism is the cause of the evolution of coronary disease in our patient.

Forty years ago, it was suggested that subclinical hypothyroidism is a cardiovascular risk factor and the controversy supported by the results of the various studies has continued since. Whickham's investigation found no relationship between SCH and coronary heart disease development over a 20-year follow-up, while the Rotterdam study of 5000 women over 55 years found that in 11% of this population, SCH was a strong indicator of the atherosclerosis risk and myocardial infarction [2].

In 2005, the debate was further raised by the simultaneous publication of two large studies that assessed the relationship between SCH and cardiovascular risk. The Rodondi's study; in which 2730 patients were followed for 4 years; showed a relationship between high TSH level and the incidence of heart failure. On the other hand, the study by Walsh et al. evaluated 2108 patients over 20 years and showed that those who had SCH had a high incidence of coronary events. This association is independent of other cardiovascular risk factors [3].

More recently, Cappola et al. analyzed data from 3233 elderly patients in the Cardiovascular Health Study and found no relationship between TSH level and coronary heart disease risk. However, the first meta-analysis published on this topic in 2007 concludes that SCH is associated with a high prevalence of coronary artery disease due to the high frequency of coronary events during follow-up [2].

The only study that objectively evaluates the possible relationship between subclinical hypothyroidism and coronary disease; confirmed by coronary angiography; is published in 2003 by Auer et al. It studied 100 patients referred for cardiac catheterization for chest pain and analyzed the relationship between the presence and the importance of coronary disease and the level of TSH and free T4, T3. The level of these hormones varies with the severity of coronary involvement but the association is significant only for T3 and T4. These authors concluded that variations of these hormones within the limits of normal are associated with the existence and severity of coronary involvement [1].

In our observation; the SCH appeared to be responsible for evolution of the coronary disease, but it masked the myocardial infarction which is discovered by complete atrioventricular block.

Conclusion

Hypothyroidism is associated with many cardiovascular effects. The pathogenesis of SCH in the development of coronary artery disease has been the subject of several studies whose results remain contradictory. Our observation raises this association but its particularity lies in the mode of revelation of the coronary involvement.

References

1. Ant3nio Jos3 Fiarresga, Joana Feliciano, et al. Relationship between coronary disease and subclinical hypothyroidism: an angiographic study. *Rev Port Cardiol* 2009; 28 (5): 535-543
2. Cappola AR, Ladenson PW. Hypothyroidism and atherosclerosis. *J Clin Endocrinol Metab.* 2003;88 :2438-2447.
3. Walsh JP, Bremner AP, Bulsara MK, et al. Subclinical Thyroid Dysfunction as a Risk Factor for Cardiovascular Disease. *Arch Intern Med.* 2005; 165:2467-2472.