

Anomalous Origin and Course of the Right Coronary Artery: Interest of the Coroscanner

Jihad Raoui ,MD¹,Bouthayna Mesmoudi MD², Elizabeth O. Ugoani MD³,Lamdak Soufiane MD⁴,Daoud Leila MD⁵
and Rokya Fellat DM⁶

^{1,4}Resident doctor Cardiology B Department, IbnSina Teaching Hospital Rabat

^{2,5,6}Resident doctor Cardiology Center in the Mohammed V Military Instruction Hospital of Rabat.

³Resident doctor Cardiology A Department, IbnSina Teaching Hospital Rabat.

ARTICLE INFO

Article history:

Received: 24 January 2020;

Received in revised form:

27 February 2020;

Accepted: 7 March 2020;

Keywords

Dual-source Scan,
Intra-atrial,
Right Coronary Artery.

ABSTRACT

Anomalous coronary arteries are rare but potentially life-threatening abnormalities of coronary circulation. Most variations are benign; however, some may lead to a myocardial ischemia and/or a sudden cardiac arrest. The coronary angiography is the standard reference investigation with an excellent spatial and temporal resolution. However, the determination of the origin and pathological course of the coronary arteries is sometimes difficult with the coronary angiography because it is a bidimensional exam; hence the importance of complementing it with a coronary scan. The coronary scan is the most widely used technology for specifying the anomalous course and the interactions with the large vessels. We report the case of an elderly woman who had a coronary angiography, followed by a coronary multi-detectors scan for chest pain. The coronary angiography showed an anomalous origin without specifying the course and the interactions with the large mediastinal vessels. The multi-detectors scan improved the diagnostic accuracy, especially in the visualisation of some pathological courses at risk of sudden death. Our case defends the complementarity of the coronary angiography and the multi-detector scan in the exploration of the coronary congenital anomalies. The coronary angiography is used in emergency situations, whereas the scan is deployed as part as the exhaustive assessment of a suspected anomaly after a cardiac catheterization .

© 2020 Elixir All rights reserved.

Introduction

The coronary congenital anomalies are rare diseases (0,3% à 2% according to the authors) (1). These anomalies are very varied. There are anomalies of the origin, the course of the epicardial coronary arteries, and the distal connexion. The coronary angiography is the standard reference investigation with an excellent spatial and temporal resolution.

However, the determination of the origin and pathological course of the coronary arteries is sometimes difficult with the coronary angiography because it is a bidimensional exam. Some courses are at risk of sudden death and have to be absolutely identified. An anatomic exhaustive assessment is necessary before any treatment (surgery, interventional percutaneous radiology, or therapeutic abstention).

It seemed to us appropriate to evaluate the performances of the coronary angiography and the contribution of the multidetector scan in the evaluation of congenital anomalies of coronary arteries, especially when the coronary angiography is at fault.

Case report

We report the case of a 75 year old patient who has high blood pressure under treatment, and an atrial fibrillation. She presented with an atypical angina and a class II NYHA shortness of breath. The clinical examination was unremarkable.

The electrocardiogram showed an atrial fibrillation with an abrasion of the R wave in the antero-septal territory . The echocardiography revealed an hypokinesia of the anterior and septal walls. The coronary angiography showed an insignificant lesion of the medium left anterior descending coronary artery IVA2 with difficulty in intubating the right coronary artery which present an anomalous origin (Figure 1).

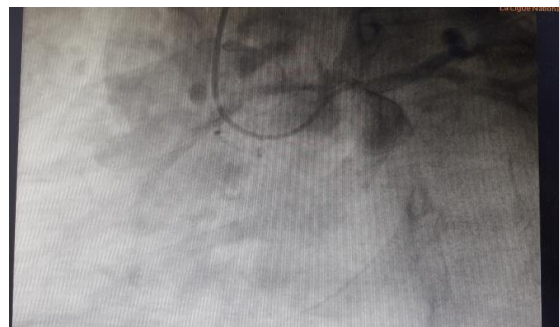


Figure 1 . Coronary angiography image showing an anomalous origin of the right coronary artery.

We completed the investigation by a coronary scan which revealed an anomalous origin of the right coronary artery , taking origin from the common coronary trunk, insinuating itself forward , between the aorta and the trunk of the pulmonary artery ; with a good opacification distally , and of the rest of the common trunk and the circumflex artery (Figure 2 and 3).

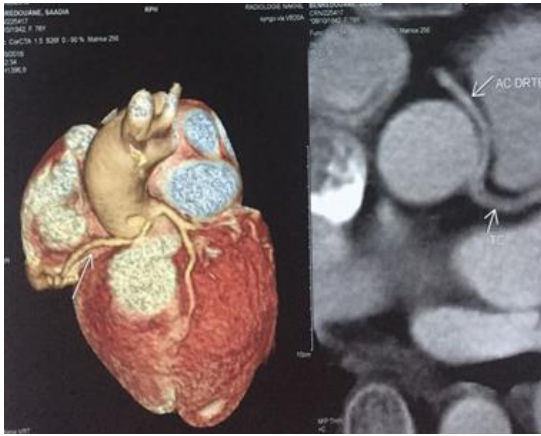


Figure 2 et 3 . Coronary CT images showing an anomalous origin and course of the right coronary artery. Discussion

The anomalous origin of the coronary arteries are rare congenital defects .They are found in 0,3 to 1 % , or even 1 to 2 % of the general population according to the authors(1,2) .A lot of classifications of these anomalies exist , including the modified one of Greenberg(3,4) and Angelinila's , which is more recent (5) .

The congenital coronary artery anomalies concern their origin, their course, and their termination .Yamanaka (6) made a study involving 126.595 patients with congenital coronary artery anomalies who underwent a coronary angiography. He categorized these anomalies according to their origin and their course .These coronary anomalies are also classified on the hemodynamic plan in significant or not (6) .The significant hemodynamic anomalies represent about 20 to 46 % of coronary congenital anomalies (7).They can be associated to a shunt and be responsible of malignant arrhythmia , syncope, myocardial ischemia with a risk of sudden death (6,7) .The anomalous origin can be aortic or not (8) . It can also be systemic and responsible of coronary vol or a flow competition. When the coronary artery takes origin from the pulmonary artery, it is very serious: its prevalence is about one in 300 000 with 90 % of death before one year if not treated (9,10).

The coronary angiography is the standard reference investigation for coronary artery imaging thanks to its unrivalled spatial resolution, its lower irradiation comparing to the scan, and its hemodynamic analysis . However, the identification of the origin and the course of the aberrant coronary arteries with invasive coronary angiography is difficult sometimes (8) . It is also limited in the spatial study of the artery's path and its relationships with the big trunks.

The multi-detector scan synchronised with the electrocardiogram has revolutionised the diagnosis of these anomalies with its non-invasive approach, compared with the coronary angiography and its relative economy (4) . It showed its superiority in visualizing the ostia, especially that of the common trunk, and the congenital coronary anomalies, in particular the anomalous origin of the right coronary artery from the left sinus (8) . According to the north American recommendations, despite the irradiation and the need of using the iodinated contrast agent, the scan represents one of the best imaging means for the diagnosis of known or suspected coronary anomalies.(Class II , level of evidence C) (11) .

There are four types of anomalies of course: inter-arterial, retro-aortic or retro-cardiac, pre-pulmonary or pre-cardiac and intra-septal or sub-pulmonary. The inter-arterial course by passage of the coronary artery between the pulmonary trunk and the ascending aorta with arterial compression between the two large vessels can lead to sudden death.It is called "killer" because it is responsible of an exertional arterial spasm by an angle closure between the coronary course and the ostium or the ostial valve, paroxysmal cardiac arrhythmias and a chronic ischemic heart disease (12). The symptomatology is manifested in precordial pain, tachypnea, cardiac arrhythmias, and synopes (1,9) .This segmental coronary compression during the systole could be suspected with the coronary angiography , and well identified with the multi-detector scan .(13). According to Eckart (14), 33% of non-accidental sudden deaths in young adults are cardiac related, including a coronary origin from the contralateral cusp with an inter-arterial course between the aorta and the pulmonary artery. ("killing course") . The evaluation of the origin and course of the coronary arteries shall be performed in any person who survived a sudden death, or who has a potentially deadly arrhythmia , a symptomatic coronary ischemia , or a left ventricular dysfunction (Class I, level of evidence B) (15).

The main disadvantage of the cardiac scan is the significant irradiation of the patient and the injection of iodinated contrast product (16). However, the current techniques for prospective acquisition (the "Step and Shot") and retrospective (by modulation of the rate according to the EKG) can reduce from 30 to 50 % . The irradiation can thus reduce 5 to 7 mSv without compromising the quality of images (17). Some authors report that it is currently possible to achieve a coronary scan of about 1 to 4 mSv in a patient with a heart rate lower than 65 per minute with a 256slice scan, using a high pitch. (18)

The surgical treatment with coronary revascularization is indicated for an anomalous course of the common trunk between the aorta and the pulmonary artery or a coronary ischemia with a documented coronary compression (Class I, level of evidence B) (19).

Conclusion

Our observation showed the complementarity of the coronary angiography and the multi-detector scan in the exploration of the coronary congenital anomalies. The coronary angiography is used in emergency setting whereas the scanner is applied for an exhaustive assessment of a suspected anomaly after a cardiac catheterization. In some cases of impracticable coronary angiography because of the impossibility of catheterizing a coronary artery, the multi-detector scan seems to be an excellent alternative in the evaluation of the coronary arteries.

References

1. Angelini P, Velasco JA, Flamm S. Coronary anomalies: incidence, pathophysiology, and clinical relevance. *Circulation* 2002; 105: 2449-54.
2. Fujimoto S, Kondo T, Orihara T, et al. Prevalence of anomalous origin of coronary artery detected by multi-detector computed tomography at one center. *J Cardiol* 2011; 57:69-76.
3. Greenberg MA, Fish BG, Spindola-Franco H. Congenital anomalies of coronary artery: classification and significance. *Radiol Clin North Am* 1989; 27:1127-46.
4. Kim SY, Seo J, Do K-H, Heo J-N, Lee JS, Song J-W, Choe

- Y H, TaeHoon Kim and al. Coronary artery anomalies: Classification and ECG-gated multi-detector row CT findings with angiographic correlation. *RadioGraphics* 2006; 26: 317-34.
5. Angelini P. Coronary anomalies: an entity in search of an identity. *Circulation* 2007; 115:1296-305.
6. Shriki JE, Shinbane JS, Rashid MA, Hindoyan BA, Withey JG, DeFrance A et al. Identifying, characterizing, and classifying congenital anomalies of the coronary arteries. *RadioGraphics* 2012; 32:453-68.
7. Erol C, Koplay M, Paksoy Y. Evaluation of anatomy, variation and anomaly of the coronary arteries with coronary computed tomography angiography. *Anadolu Kardiyol Derg* 2013; doi:10.5152/akd.2013.041
8. Mizouni H, Ben Slima H, Mahmoud M, Omri I, Chemli S, Kharrat R, Baccar H, Menif E. Poster électronique SFR : Le scanner en complément à la coronarographie dans la prise en charge des patients cardiaques: à propos de 30 cas. Service d'Imagerie Médicale CHU La Rabta Tunis Tunisie. <http://pe.sfrnet.org/Data/ModuleConsultationPoster/pdf/2011/1/8a6f64c4-cfbd-4a2a-8069-082440637ede.pdf>
9. Dodge-Khatami A, Mavroudis C, Backer CL. Anomalous origin of the left coronary artery from the pulmonary artery: collective review of surgical therapy. *Ann Thorac Surg* 2002; 74:946-55.
10. Bland EF, White PD, Garland J. Congenital anomalies of the coronary arteries: report of an unusual case associated with cardiac hypertrophy. *Am Heart J* 1933; 8: 787-801.
11. Budoff MJ, Achenbach S, Blumenthal RS, Jeffrey Carr J, Goldin JG, Greenland P et al. Assessment of coronary artery disease by cardiac Computed Tomography. *Circulation* 2006; 114:1761-1768. doi:10.1161/CIRCULATIONAHA.106.178458.
12. Mennesson N. Variantes anatomiques des artères coronaires: description et pronostic. Poster SFR. <http://pe.sfrnet.org/Data/ModuleConsultationPoster/pdf/2009/1/242564bd-1bdb-4fa1-996a-5045c1164164.pdf>
13. Lee H-J, Hong YJ, Kim HY, Lee J, Hur J, Choi BW et al. Anomalous origin of the right coronary artery from the left coronary sinus with an interarterial course: subtypes and clinical importance. *Radiology* 2012; 262: 101-108. <http://radiology.rsna.org/lookup/suppl/doi:10.1148/radiol.11110823/-/DC1>.
14. Eckart RE, Scoville SL, Campbell CL, et al. Sudden death in young adults: a 25-year review of autopsies in military recruits. *Ann Intern Med* 2004; 141: 829-34
15. Warnes CA, Williams RG, Bashore TM, Child JS, Connolly HM, Dearani JA et al. ACC/AHA 2008. Guidelines for the management of adults with congenital heart disease: A report of the American College of Cardiology/ American Heart Association task force on practice guidelines. *Circulation*. 2008; 118: e714-e833. doi: 10.1161/CIRCULATIONAHA.108.190690
16. Budoff MJ, Achenbach S, Blumenthal RS, Jeffrey Carr J, Goldin JG, Greenland P et al. Assessment of coronary artery disease by cardiac Computed Tomography. *Circulation* 2006; 114:1761-1768. doi:10.1161/CIRCULATIONAHA.106.178458
17. Jakobs TF, Becker CR, Ohnesorge B, et al. Multislice helical CT of the heart with retrospective ECG gating: reduction of radiation exposure by ECG-controlled tube current modulation. *Eur Radiol* 2002; 12:1081-86.
18. Coles DR, Smail MA, Negus IS, et al. Comparison of radiation doses from multislice computed tomography coronary angiography and conventional diagnostic angiography. *J Am Coll Cardiol* 2006; 47: 1840-5.
19. Warnes CA, Williams RG, Bashore TM, Child JS, Connolly HM, Dearani JA et al. ACC/AHA 2008. Guidelines for the management of adults with congenital heart disease: A report of the American College of Cardiology/ American Heart Association task force on practice guidelines. *Circulation*. 2008; 118: e714-e833. doi:10.1161/CIRCULATIONAHA.108.190690