



Malleus Head Fixation- A Case Report

Mahiou Nouredine¹, Bolzer Adrien², Stringini Robert² and Essakalli Leilla¹

¹Department of Otolaryngology, Head and Neck Surgery, Ibn Sina University Hospital, Mohammed V University, Rabat, Morocco

²Department of Otolaryngology, Head and Neck Surgery, Regional Hospital Center of METZ-THIONVILLE France

ARTICLE INFO

Article history:

Received: 26 October 2019;

Received in revised form:

26 April 2020;

Accepted: 2 May 2020;

Keywords

Malleus head fixation,
House syndrome,
Conductive hearing loss.

ABSTRACT

Malleus head fixation is a rare but not exceptional pathology. It may be apparently congenital or acquired, and can be associated with stapes fixation. In the acquired secondary process two histological types of malleus head fixation were found: the first corresponded to non-tympanosclerotic bone remodeling and the second to localized tympanosclerosis.

© 2020 Elixir All rights reserved.

Introduction

HOUSE syndrome is a rare clinicopathological entity described initially by Goodhill [2] in 1966.

The congenital origin seems to be the most commonly accepted, but may also be found on healthy ear malformation pathology.

It is mainly found when working on a suspicious ear otosclerosis and represents a significant cause of revision surgery in this disease. Diagnostic confirmation of House Syndrome is operative. The aim of our study was to analyze the findings of middle ear exploration and the frequency of ossicular and footplate area anomalies in patients with suspected otosclerosis.

Case report

It's about young men, 19 years old, which presents as a medical history otitis media repeated in childhood ;no family history of deafness , consulting for unilateral hearing loss in right side worsening the last four years without other associated signs as vertigo or tinnitus. Otoscopic exam find normal ear drums. The rest of the ENT examination was unremarkable.

The audiogram includes conductive hearing loss of 45 dB in the right ear and normal in another ear.

Temporal bone CT scan right reveal fixation of the Malleus in tegmen tympani by a bone bridge and attical filling (Figure 1).

The surgery consists of a middle ear exploration. All of the three chain bone was explored. Stapes footplate was normal and no otosclerosis was found. The head of the malleus may be fixed to the bony walls of the epitympanic recess (Figure 2). An ossiculoplasty was done, by section of the Malleus neck with interposition with Incus.

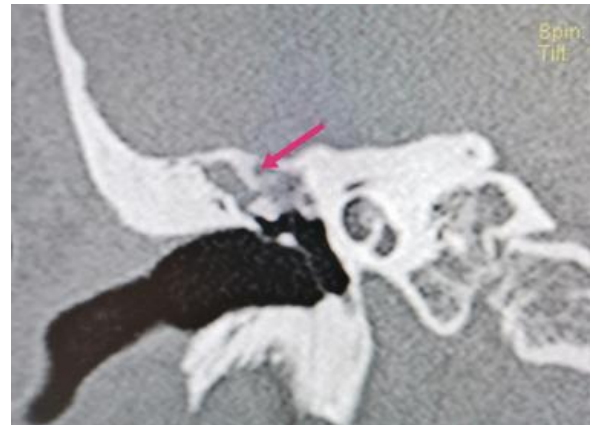


Figure 1. fixation of the Malleus in tegmen tympani by a bone bridge (red arrow) and attical filling

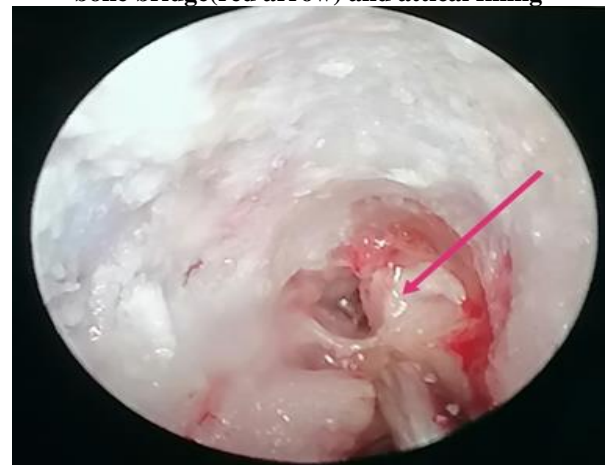

Figure 2. The head of the malleus may be fixed to the bony walls of the epitympanic recess (red arrow)

Discussion

Congenital anomalies of the middle ear can be classified into major, when associated with a involvement of tympanic membrane and external ear, or minor, when there is an exclusive involvement of the middle ear [1,3,4].

In 1993, Teunissen and Cremers [1,4] created a classification of minor malformations, based on the surgical approach, dividing them into four main groups: isolated stapes ankylosis, stapes ankylosis associated with other ossicular malformations, deformity of the ossicular chain with mobile stapes footplate, and severe aplasia or dysplasia of oval or round windows.

House syndrome or Fixed malleus head syndrome corresponds to a primitive attachment, often bilateral, of the Malleus head in epitympanum by an anterior or upper synostose rarely medial [5].

Its frequency is low, reaching 1% of interventions on the middle ear according to some series [6].

Causes of Malleus Head Fixation

Malleus fixation can occur as a congenital anomaly or develop following otitis media [7].

In our case we refer to secondary ossification:

- unilateral ear injury
- inflammatory attic filling
- infectious otic antecedent
- absence of other organic malformations

Ossicular mobility can be re-established with two surgical methods. The more simple method consists in a classical incus transposition with malleus neck section. The more physiological method consists in drilling the synostosis fixing the malleus without disrupting the ossicular chain; stapedotomy is associated in certain cases (Type III) [8].

Conclusion

Isolated hearing loss, unilateral or bilateral, needs a middle ear exploration. It can be an otosclerosis only, or otosclerosis associated to malformations of middle ear area

(ossicular chain anomalies, fixation of head of malleus...). The diagnostic is confirmed during surgery. The most common case is the class II of Charachon. We could not find any similar study in which the researchers investigated the frequency of ossicular and footplate area anomalies in patients with suspected OS. Many of the papers are limited case reports, and it seems that the frequency of ossicular anomalies is better to be evaluated and compared in different countries.

References

1. Teunissen EB, Cremers WR (1993) Classification of middle ear anomalies. Report on 144 ears. *Ann Otol Rhinol Laryngol* 102: 606-12.
2. Goodhill V (1960) Pseudo-Otosclerosis. *Laryngoscope* 70: 722-57.
3. Swartz JD, Faerber EN (1985) Congenital malformations of the external and middle ear: high-resolution CT findings of surgical import. *AJR Am J Roentgenol* 144: 501-6.
4. Cremers CW, Teunissen E (1991) The impact of a syndromal diagnosis on surgery for congenital minor ear anomalies. *Int J Pediatr Otorhinolaryngol* 22: 59-74.
5. Esteves SD, Silva AP, Coutinho MB, Abrunhosa JM, Almeida e Sousa C (2014) Congenital defects of the middle ear--uncommon cause of pediatric hearing loss. *Braz J Otorhinolaryngol* 80: 251-6.
6. House HP (1963) Early and late complications of stapes surgery. *Arch Otolaryngol* 78: 606-13.
- 7-W. Hugh Powers, MD; James L. Sheehy, MD; Howard P. House, MD The Fixed Malleus Head A Report of 35 Cases February 1967
- 8-Bruzzo M, Braccini F, Cacès F, Vallicioni JM, Chays A, Magnan J Fixed malleus head syndrome *Annales D'oto-laryngologie et de Chirurgie Cervico Faciale : Bulletin de la Societe D'oto-laryngologie des Hopitaux de Paris* [01 Nov 1998, 115(5):279-283]