

# Role of Multidetector CT in Determining the Variations in Renal Arteries Anatomy and Its Clinical Relevance

Sachal Sharma<sup>1</sup>, Namita Singh<sup>2</sup>, Payal Malhotra<sup>3</sup> and Murtaza Kamal<sup>4</sup>

<sup>1</sup>BLK Super Speciality Hospital, New Delhi.

<sup>2</sup>INMAS New Delhi.

<sup>3</sup>Rajiv Gandhi Cancer Institute and Research Centre, New Delhi.

<sup>4</sup>Star Hospitals, Hyderabad.

### ARTICLE INFO

#### Article history:

Received: 8 August 2020;

Received in revised form:

01 September 2020;

Accepted: 11 September 2020;

#### Keywords

Renal Arteries,  
Variants,  
MDCT,  
CT Angiography.

### ABSTRACT

The advancements in surgical nephrology in the management of numerous renal pathologies in the form of vascular reconstruction, renal transplants, nephron sparing surgeries, etc and the indispensable use of non invasive MDCT technology in detecting the variations in renal arteries anatomy has validated the study. Assessment of the anatomical variants of bilateral renal arteries in Indian population cohort on MDCT angiography and its clinical implications. 110 subjects were included in the study. The subjects were in the age group of 20 to 50 years. There were 60 (55%) male and 50(45%) female subjects. Normal and variant anatomy of renal arteries was studied using a 40 slice multidetector CT scanner. 76(69%) patients had single renal artery on right side, two renal arteries in 32(29%) patients and three renal arteries in 2(1.8%) patients. On the left side 87(79%) patients have single renal artery, 19(17%) patients have two renal arteries and 4(3.6%) patients have three renal arteries. No correlation with respect to the sex of the subjects was found. Knowledge of the renal artery anatomy is crucial in attaining the precision in renal related surgeries and MDCT renal angiography is the ideal modality of choice as it is not only accurate but also provides a detailed anatomical road map of the vascular anatomy.

© 2020 Elixir All rights reserved.

### Introduction

The wide variations observed in the blood supply of the kidneys are the result of the changes during embryological development in early fetal life[1]. In around 75% of individuals renal arteries arise from aorta immediately below superior mesenteric artery at the level of L1-L2 intervertebral disc space. In around 60% of individuals renal arteries divide at the renal hilum. There is somewhat increased frequency of occurrence of accessory renal arteries on left side. Traditionally conventional catheter angiography is used to assess normal abdominal aortic anatomy[2]. However it is an invasive procedure and has limited value in detailed assessment of vessel anomalies which is important to reduce the risk of trauma to the vessels and to ensure thorough vascular ligation and anastomosis during surgery[3]. Recently Multidetector CT angiography has become a key investigation for assessment of renal vasculature and has challenged the role of conventional angiography. MDCT system offers shorter image acquisition time, narrower collimation, improved temporal and spatial resolution and post processing of axial CT images using various techniques like Multiplanar reconstruction (MPR), Maximum intensity projection (MIP) and volume rendered techniques(VRT)[2]. The advantage of CT angiography over conventional angiography is that the former is non invasive and it can be performed on outpatient basis. After the scan is finished and the iv canula is removed, patient does not need to stay for observation as there are least chances of procedure related

complications except for radiation exposure and IV contrast related complications [4]. Also it is better than MR angiography, as less procedure time and less patient compliance is required in CT angiography. Although studies are available regarding the normal and variant anatomy of renal arteries, but less of the studies are on Indian cohort.

### Material and methods

#### Data Source

This was a prospective study carried out on 110 patients coming to the department of Radiodiagnosis, who underwent the study on Siemens Somatom Sensation 40 over a period of 15 months from September 2009 to November 2010. Study subjects were in the age group of 20-50 years and there were 60(55%)males and 50(45%)females. The study protocol was approved by the local ethical committee and after relevant clinical history and consent, the procedure was explained to the patient.

#### CT Protocol

As part of our protocol firstly a scout image was obtained. After this unenhanced CT scans was obtained while keeping the protocol for the unenhanced acquisition as 140 kVp, 130–230 mA, 5-mm thickness, pitch of 0.9 mm per rotation. The area from the lower thoracic spine to the symphysis pubis level with the patient in a supine position was adopted as the field of view. During examination, an 18-20 angiocath needle inserted into the patient's antecubital vein was used to inject 120 ml of non-ionic iodinated contrast medium using the bolus tracking technique (rather than a

predetermined delay time) with an automatic injector at a rate of 3-4ml/sec, with estimated dose of contrast as 1-1.5ml/kgwt of the patient. Image acquisition started when the threshold HU of 100HU is obtained in the abdominal aorta after an approx. delay of 5-6 seconds. Arterial phase was selected for acquiring images and then transfer of data to a workstation for analysis of images is done. Maximum intensity projection(MIP), Multiplanar reconstruction (MPR) and 3D Volume rendering technique(VRT) are used for evaluation.

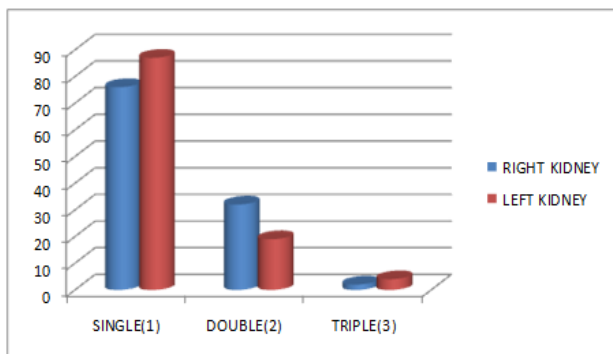
#### Method of analysis

Renal arteries were evaluated in terms of number of renal arteries on each side and any other renal artery apart from the main renal artery is termed as accessory or aberrant renal artery and are described as follows.

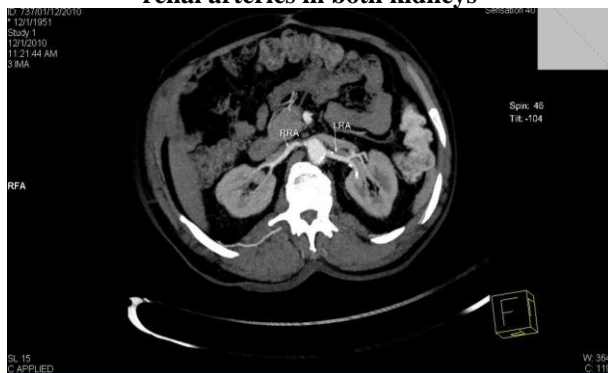**Accessory renal artery:** Renal artery apart from main renal artery which is entering through the renal hilum.

**Aberrant renal artery:** Renal artery apart from main renal artery which is entering through directly penetrating the renal cortex.

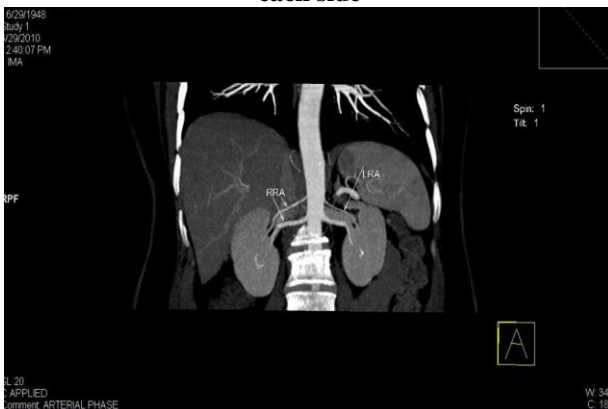#### Results



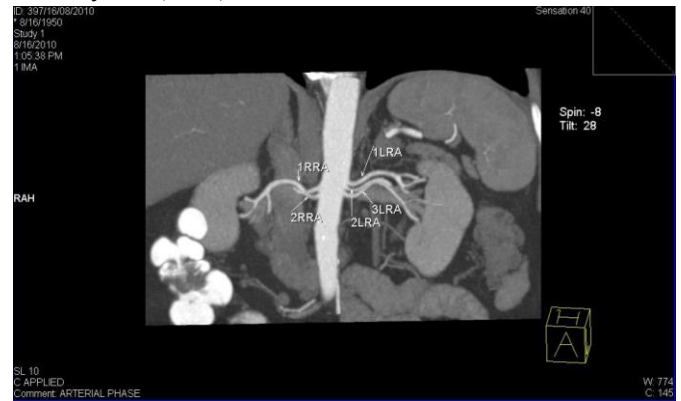**Diagram 1. Shows distribution of variation in number of renal arteries in both kidneys**



**Figure 1. Axial MIP image showing single renal artery on each side**



**Figure 2. Coronal MIP image showing double renal arteries on each side**



**Figure 3. Coronal MIP image showing three renal arteries on left side and two renal arteries on right side**

Out of 110 patients evaluated for number of renal arteries on each side, in the right kidney 76(69%) patients had single renal artery(fig.1) ,32(29%) patients had double renal arteries(fig.2) and 2(1.8%) had triple renal arteries. In left kidney 87(79%) of patients had single renal artery(fig.1),19(17%) had double renal arteries (fig.2) and 4(3.6%) patients had triple renal arteries on left side(fig.3). Results are tabulated in terms of a bar diagram (diagram1) No more than triple renal arteries were found. No significant correlation was found between the variations in renal arteries and the sex of the patient.

#### Discussion

The variation in renal arteries is quite common and encountered in one third of the population. Data obtained in our study correlates well with that described in the anatomy and conventional angiography literature[3]. The comparability of results also validates the use of MDCT for determination of renal vascular anatomy as well as its variations. Rubin[5] showed comparable diagnostic results between renal CTA and digital subtraction angiography for peripheral run-off vessels. Other studies by Kaate et al[6] and Beregi et al[7] showed comparable sensitivity and specificity for detecting and quantifying renal artery stenosis comparing CTA with digital subtraction angiography. The results of our study are comparable to the study done by Ugurel M.S. et al [1] Investigated 100 patients 58 of them had single renal artery on right side and 42 patients revealed more than one renal artery similar to the current study . A large study cohort by Satyapal et al[8 ] studied 440 kidneys and reported that the incidence of double renal arteries in was 23.29%(102 Kidneys) and the presence of triple renal arteries was 4.5 % (20 Kidneys) which also shows comparable results as in our study. Similarly, CT angiography performed by Rawat KS[3] in Rajeev Gandhi Cancer Institute and Research Centre of 125 patients showed that total renal artery variations were noted in 33 (26.4%) patients. Multiple left renal arteries were found in 20(16%) patients and multiple right renal arteries in 19(15%) patients. Angiographic evaluation of 855 patients by Ozkan et al [9] to study the renal artery variation revealed, a single renal artery was present in both kidneys in 76% of patients. Renal artery variations included multiple arteries in 24%, bilateral multiple arteries in 5%, and early division in 8% of the cases. Bergman et al[10] reported that double renal arteries occur in 10% of cases and the incidence of triple renal arteries is 1-2%. On dissection of 267 cadavers Khamanorong et al [11] found double renal arteries in 93 kidneys (17.43%) and triple renal arteries in five (0.93%). Bordei et al [12] analyzed 252 kidneys to analyze renal

vasculature and recognized 54(20%) double renal arteries and 3 (1.1%) triple renal arteries.

The role of CT has carved its path into the ever demanding surgical field of nephrology where the accurate anatomic data of the kidney as well as its renal arteries are critical in surgical planning and better patient outcome. For instance, knowledge of renal artery anatomy before renal transplantation plays an important role as the transplantation of kidneys that have one renal artery is technically easier than when there is more than one renal artery. Moreover, post-surgical rates of complication and kidney loss are lower in kidneys with single renal artery as compared to kidneys with more than one renal artery[9]. Variants in renal arteries is also important in surgical procedures related to the posterior abdominal wall, renal transplantation, abdominal aortic aneurysm, ureter surgery and the vascular pedicles of the kidney[13]. It is important for the surgeons to have extensive preoperative knowledge of the renal vascular anatomy for selecting the proper kidney and for the surgical planning when performing laparoscopic donor nephrectomy. Depiction of the vascular variants on the preoperative imaging avoids the vascular injuries and dissection of these vessels during surgery. Accessory kidney arteries sometimes enter the kidney directly from the superior or inferior renal poles. An accessory artery in the inferior renal pole crosses the ureter obliquely from its anterior aspect, and may lead to hydronephrosis by compressing the ureter. It is important to be aware that accessory renal arteries are not juvenile arteries, and thus ligation of an accessory renal artery ends up with ischemic damage to the supplied portion of the kidney. Therefore, a knowledge of variations in renal vasculature is of crucial importance for interventions involving the renal arteries or abdominal aorta[1]. Planning nephron-sparing surgery in a case of a renal neoplasm also requires precise localization of the renal lesion and its relationship to the renal vasculature[14].

### Conclusion

Knowledge of variant anatomy plays a key role in planning and execution of therapeutic procedures. Due to the increasing role of intervention in the management of renal diseases the pre procedural assessment of renal vascular anatomy and their variations in terms of number of renal arteries has become a part of every diagnostic and therapeutic procedures. CT angiography has arose as a powerful tool in assessing the variations in the arterial anatomy and with multiple advantages over conventional angiography and comparable results.

**Disclaimer:** The research work done in the article is original and is not published or under consideration for publication in any other journal

**Conflict of Interest:** Nil

### References

1. Ugurel M.S. Anatomical variations of hepatic arterial system, celiac trunk and renal arteries: an analysis with multidetector CT angiography .British Journal of Radiology. 2010; 83: 661-667.
2. Türkvatan A, Özdemir M, Cumhuri, Ölcer T. Multidetector CT angiography of renal vasculature : normal anatomy and variants- Eur Radiol. Jan 2009 ;19(1):236-44.
- 3 Rawat KS. CT angiography in evaluation of vascular anatomy and prevalence of vascular variants in upper abdomen in cancer patients. Ind j radiol Imag 2006;Year : 2006, Volume : 16 , Issue : 4 ,Page : 457-461
4. Convey A.M. Variant Hepatic Arterial Anatomy Revisited: Digital Subtraction Angiography Performed in 600 patients. Radiology journal 2002; 224, 542-547
5. Rubin, Geoffrey D. CT and MR angiography: comprehensive vascular assessment (2008); 3:94, 20:874, 18:719-772.
6. Kaatee R, Beek FJA, de Lange E, et al. Renal artery stenosis: detection and quantification with spiral CT angiography versus optimized digital subtraction angiography. Radiology. 1997; 205:121-127.
7. Beregi JP, Elkohen M, Deklunder G, et al. Helical CT angiography compared with arteriography in the detection of renal artery stenosis. AJR.1996; 167:495-501.
8. Satyapal KS, Haffejee AA, Singh B, Ramsaroop L, Robbs JV, Kalideen JM. Additional renal arteries: incidence and morphometry. Surg Radiol Anat.2001;23: 33-8.
9. Ozkan U. Renal artery origins and variations: angiographic evaluation of 855 consecutive patients. Diagnostic and interventional radiology. 2006; 12:183-186.
10. Bergman RA, Afini AK, Miyauchi R. Renal arteries: Illustrated encyclopedia of human artery variation: Opus II: Cardiovascular system: Arteries: Abdomen. Anatomy atlases. 2005.
11. Khamnarong K, Prachaney P, Utraravichien A, Tongun T, Sriporaya K. Anatomy of renal artery supply. Clin Anat. 2004; 17(4):334-6.
12. Bordae P, Septe E, Ilescu D. Double renal arteries originating from aorta. Surg Radiol. 2004;26(6):474-479.
13. Soni S. Multiple variations in the paired arteries of abdominal aorta. Journal of clinical and diagnostic research. 2010; June. Vol 4, issue 3: 2622-2625.
14. Siniluoto TM, Hellstrom PA, Paivansalo MJ, Leinonen AS: Testicular infarction following ethanol embolization of a renal neoplasm. Cardiovasc Intervent Radiol 1988; 11(3):162-164.