

## Haglund Syndrome or Pump-Bump: A Confusing Diagnosis of a Swelling Painful Hindfoot

Chirihan. Ayadi\*, Hajar. Andour, Amal. Lahfidi, Issam. En-Nafaa and Mohamed. Lahkim  
Radiology Department, Military Hospital, Rabat, Morocco

### ARTICLE INFO

#### Article history:

Received: 11 July 2022;

Received in revised form:

2 September 2022;

Accepted: 16 September 2022;

#### Keywords

Posterior Heel Pain,

Haglund Syndrome.

### ABSTRACT

Posterior heel pain is a largely reported symptom caused by several diseases. Haglund syndrome is one of its uncommon etiologies. The deformity referred to as a prominent bursal projection of the calcaneus can be asymptomatic and clinical manifestations define the syndrome related to the inflammation it causes. We report the case of a 45-year-old man, with no medical history presenting to clinical examination for a swelling painful posterior heel in which MRI showed a Haglund syndrome. Through this case, we detail radiological findings of this disease and the main differential diagnoses. Posterior heel pain is a largely reported symptom caused by several diseases. Haglund syndrome is one of its uncommon etiologies. The deformity referred to as a prominent bursal projection of the calcaneus can be asymptomatic and clinical manifestations define the syndrome related to the inflammation it causes. We report the case of a 45-year-old man, with no medical history presenting to clinical examination for a swelling painful posterior heel in which MRI showed a Haglund syndrome. Through this case, we detail radiological findings of this disease and the main differential diagnoses.

© 2022 Elixir All rights reserved.

### Introduction

The Haglund syndrome is an association of bone and soft tissue abnormalities at the origin of a common problem of hindfoot pain generally caused by low-cut shoes. This syndrome regroups a prominent posterior bursal projection of the calcaneum defined as a Haglund deformity, Achilles tendinosis, retrocalcaneal and retro Achilles bursitis. The diagnosis can be set on radiographic aspects; however, MRI provides by a superior soft-tissue contrast resolution the extent and the exact location that are very helpful if an operative management is planned.

### Case presentation

A 45-year-old man, with no medical history presented with a painful swelling of the posterior heel for 6 months. Clinical examination found a soft tissue swelling at the insertion of tendon Achilles with a negative Thompson-test refuting the possibility of Achilles tendon tear. MRI of the homolateral heel was then performed and showed radiographical findings compatible with Haglund syndrome (Figure).

### Discussion

The hindfoot and the ankle are complex anatomic structures consisting in bones, tendons, bursae and ligaments of which each's injury can lead to posterior heel pain. Firstly, described by Patrick Haglund in 1928, the Haglund syndrome is characterized clinically by what is called a "pump-bump" in reference to the painful soft tissue swelling at the posterior heel occurring while starting walk after rest(1). There is not age range for this condition concerning both men and women, occasioned by chronic stress leading to an inflammation of Achilles tendon as well as superficial and retrocalcaneal bursae. This inflammation is induced by a mechanical

mechanism, in which the prominent bony projection of the calcaneus- Haglund deformity- along with low-cut shoes cause the symptomatology that is more prevalent in the sportive community particularly professional athletes, runners, football players and tennismen. Hindfoot varus and pes cavus, as well as repetitive trauma and obesity are predisposing factors.

Lateral foot radiographs in a standing position are generally enough to set diagnosis. Different criteria are suggested to this aim, including the upper parallel pitch line to objective the prominence of the bursal projection, the Fowler angle or the posterior calcaneal angle with a threshold of 75° and the pitch angle to determine the calcaneus orientation. Among these measures, the most accurate and reproducible to consider is the upper parallel pitch line. Other radiographical findings include the loss of the retrocalcaneal lucence as a sign of retrocalcaneal bursitis. A thickening of Achilles tendon over 9 mm measured 2 cm above its insertion associated to the loss of the sharp interface between the insertion and the pre-Achilles fat pad defines the tendinopathy. The convexity of the posterior soft tissues at the level of its insertion indicates its bursitis.

Even if plain radiographs together with the symptomatology are usually enough to set diagnosis, it remains unreliable highlighting the importance of MRI for ambiguous and dubious cases. It shows a higher sensitivity to establish all soft tissue-abnormalities with the cardinal signs of retrocalcaneal and retro Achilles bursitis, its tendinopathy apparent as an area of increased signal in T2-weighted images. Bone marrow edema and the enlargement of bursal projection are more evident using the same diagnosis parameter than radiography (UPL)(2,3).

Tele:

E-mail address: [chirihane.ayadi@gmail.com](mailto:chirihane.ayadi@gmail.com)

© 2022 Elixir All rights reserved

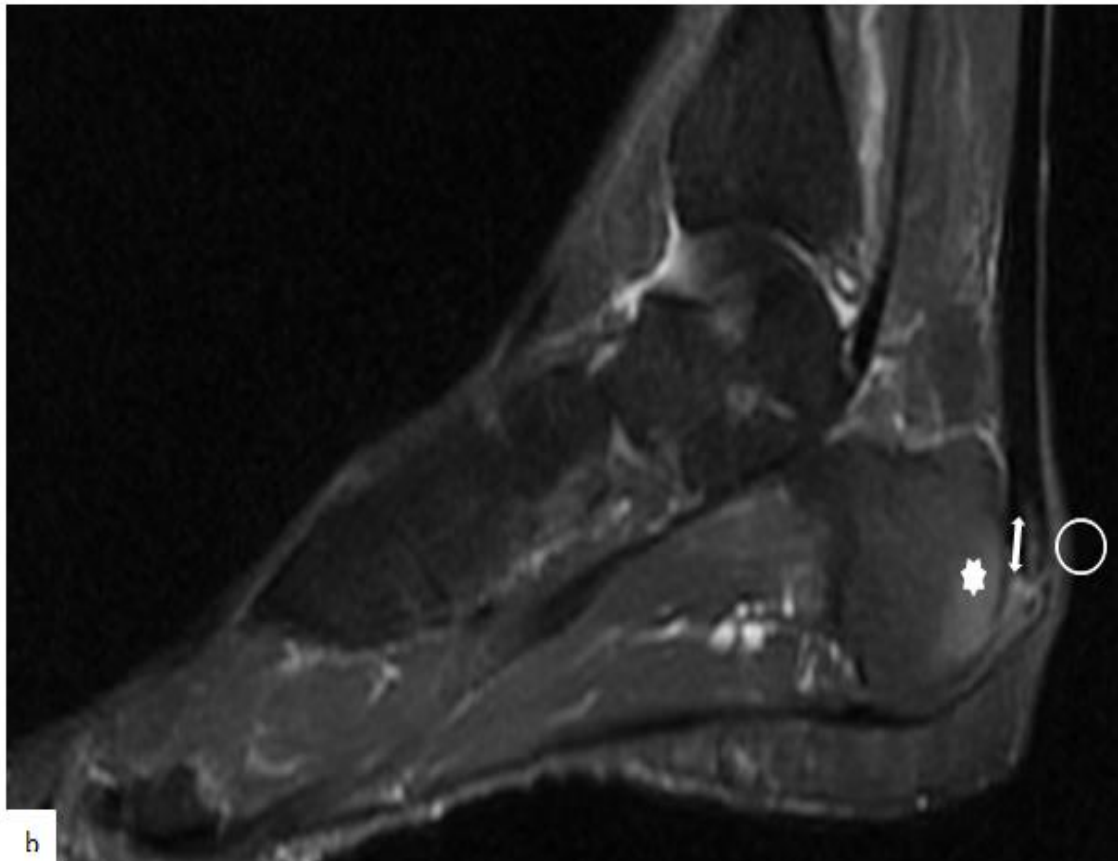
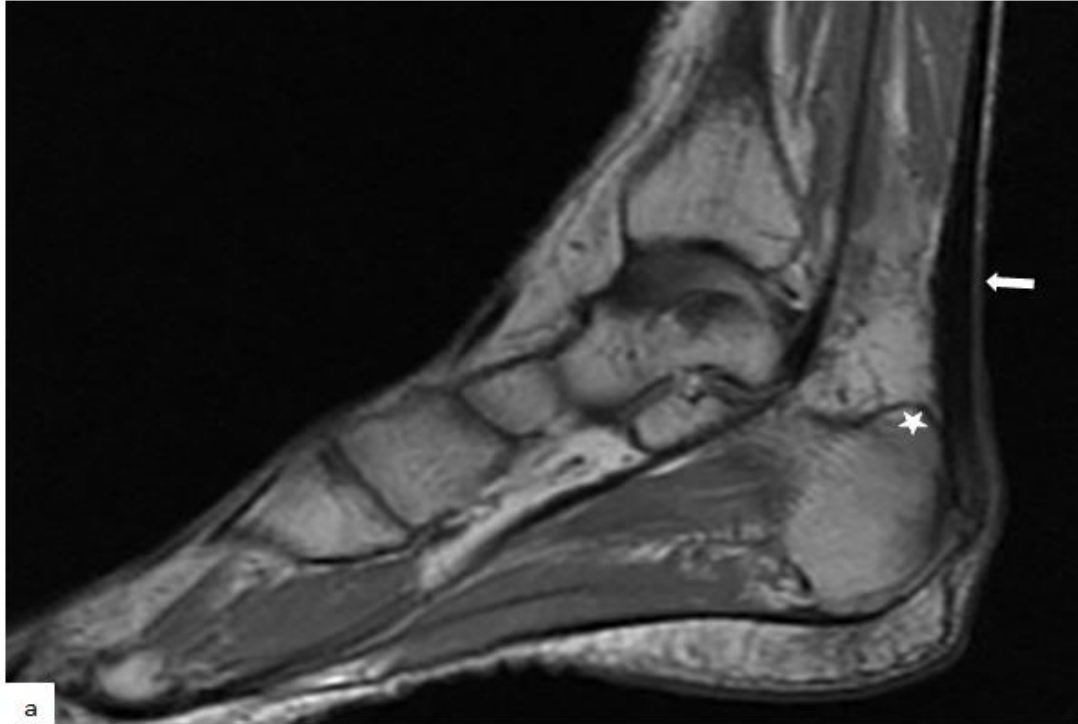
Moreover, MRI allows differential diagnosis with some systemic inflammatory diseases mainly Reiter's syndrome and rheumatoid arthritis. In these diseases, the "pump-bump" is more extended over the Achilles tendon insertion and the cortical bursal projection is eroded whereas it's intact in Haglund syndrome.

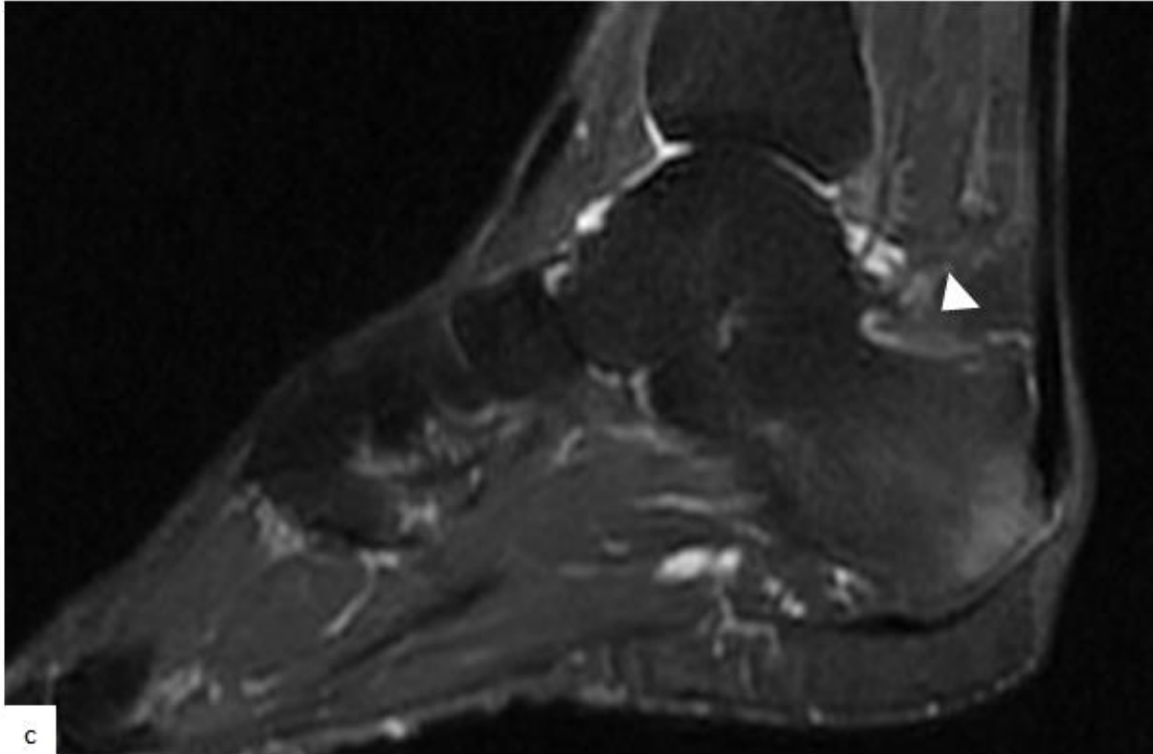
The management of the pathology starts usually as medical. Steroid injection under ultrasound guidance has been also reported to have satisfactory results with a controversial risk of tendon's tear. Endoscopic or open surgery can be considered by the resection of the prominent bursal

projection and bursectomy if the conservative management failed(4).

#### Conclusion

Painful hindfoot is a common problem with variable causes. Haglund syndrome is one of its etiologies that should not be omitted. MRI is more sensitive and informative with some diagnosis keys including: highly clinical and radiological suspicion, evaluation of the bursal projection with the ability to use the upper pitch line and detecting soft-tissue abnormalities.





**Figure.** MRI of posterior heel according to sagittal T1-weighted images (a), and sagittal STIR images (b, c) showing a prominent bursal projection (a; asterisk), a thickened Achilles tendon (arrow). STIR sequences show an hypersignal of bone marrow at the insertion of Achilles tendon, sit too of an hypersignal signing bone marrow edema (asterisk) and tendinopathy (double arrow) with a swelling of soft tissues at this level compatible with the “pump-bump” (circle). There is also a retrocalcaneal bursitis as a discreet hypersignal and a loss of lucent aspect of retrocalcaneal bursae at this level (head arrow).

#### References

1. Pavlov H, Heneghan MA, Hersh A, Goldman AB, Vigorita V. The Haglund syndrome: initial and differential diagnosis. *Radiology*. juill 1982;144(1):83-8.
2. Chauveaux D, Liet P, Le Huec JC, Midy D. A new radiologic measurement for the diagnosis of Haglund's deformity. *Surg Radiol Anat*. 1991;13(1):39-44.
3. Lawrence DA, Rolen MF, Morshed KA, Moukaddam H. MRI of Heel Pain. *American Journal of Roentgenology*. avr 2013;200(4):845-55.
4. Hung E, Kwok W, Tong M. Haglund Syndrome-a Characteristic Cause of Posterior Heel Pain.:3